

MRI Prognostication in Cervical Spinal Cord Injury without Discocorporeal Injury

Lieut Col Harjinder Singh Bhatoe, MCh

Department of Neurosurgery, Army Hospital (R & R), Delhi Cantt 110010. INDIA

Abstract : MRI has emerged as the most important imaging modality in the evaluation of spinal cord injury. Its importance in the diagnosis and prognostication has been well established. We retrospectively studied the MRI appearances of 29 patients with cervical spinal cord injury without radiologically demonstrable fracture or dislocation of the cervical spine. All patients were adults, who presented with varying grades of cervical myelopathy following trauma; eight of these were elderly with stenotic spinal canals due to cervical spondylosis. Neurological function and MRI appearances were correlated. The presence and rostrocaudal extent of intraaxial hematoma, extrinsic stenotic compression of spinal cord were each significantly associated with poor neurological function at presentation and in long-term follow-up examinations. Although the best single predictor of long-term improvement in neurological function was the neurological grade at the time of presentation, the presence and extent of intraaxial spinal cord hematoma and the presence of spinal cord compression provided significant additional information. MRI provides accurate diagnostic and prognostic information regarding neurological function and aids in treatment planning in cervical spinal cord injury without accompanying skeletal injury.

Keywords : cervical spine, magnetic resonance imaging, quadriplegia, spinal injury

Introduction

While neurological evaluation is critical in the initial assessment of patients with spinal injuries. MRI provides an efficient and safe means of directly evaluating the injured cervical spinal cord, since the MRI findings correspond to specific pathological changes in the spinal cord tissue. These findings are relevant to decision making and in determination of prognosis¹. MRI correlation in cervical spinal cord injuries associated with fracture/dislocations have been described recently^{1,2} and there are reports of prognostic role of MRI in spinal cord injury without radiological abnormality (SCIWORA) as well^{3,4,5,6}. This report attempts to define the MRI appearances of the injured spinal cord with intact cervical spine – both in adults and in the elderly – and correlate the appearances to the prognosis. Relevant literature is briefly reviewed.

MATERIAL AND METHODS

The study included 29 patients with traumatic cervical myelopathy manifesting as objective sensorimotor or motor deficit documented on presentation without concomitant injury to osseous and discoligamentous components of the spine, admitted over a period of twelve years (1992-2003).

Address for correspondence : H S Bhatoe, MS, MCh, Department of Neurosurgery, Army Hospital (R & R), Delhi Cantt-110010. INDIA. Tel.: 011-25668095, 25668096, 25681893, Fax: 011-25681893 E-mail: hsbhatoe@indiatimes.com

Criteria for inclusion: For this study, those patients with traumatic cervical myelopathy were included who did not have:

- radiologically demonstrable fracture or dislocation corresponding to the clinical level of myelopathy
- radiologically demonstrable fracture of the spinal canal rim at clinical level of myelopathy. It meant that those patients with fractures of spinous or transverse processes, but with intact spinal canal, could be included in the study.

Most of the patients were received in the Neurosurgical Center within 72 hours of the injury. All patients were neurologically examined by a neurosurgeon on admission and assigned their respective Frankel grade (Tables 1 & 2). Lateral cervical spine radiographs under supervision were obtained to exclude any bony injury or subluxation. Patients then underwent MRI of the cervical spine. All patients could undergo the imaging procedure within seven days of their injury. MRI in the acute stage (within 24 hours) was not possible due to logistic reasons. The scans were obtained at 0.5 Tesla (sixteen patients) and 1.5 Tesla (thirteen patients), using sagittal and targeted axial T1- and T2-weighted sequences. All MRI data were collected and the following parameters were evaluated:-

- appearances of the cord on T1 weighted imaging (T1WI)

- (b) rostrocaudal length of abnormally increased T2-weighted signal consistent with spinal cord edema/hematoma
- (c) presence or absence of spinal cord compression by hematoma/preexisting stenotic spinal canal

Cervical spine instability was excluded by taking lateral radiographs in flexion and extension, and fracture of the spinal canal was excluded by axial computed tomography.

Table 1. Frankel Grading of Spinal Cord Injury

Grade A	: No neurological function below the injured spinal level
Grade B	: No motor function, partial sensory function preserved
Grade C	: Partial motor function but of no functional use
Grade D	: Partial useful motor function; ambulatory with/without support
Grade E	: Normal neurological function

MANAGEMENT AND RESULTS

Twenty seven of the twenty nine patients showed abnormal T2 hyperintensity, representing edema or contusion in sagittal and axial images of the spinal cord. The rostrocaudal length of this signal change ranged from single cord level (<5 mm) to several cord segments. Longer rostrocaudal T2-hyperintensity was significantly correlated with poor neurological function (Frankel grade) in the initial neurological evaluation. Eight patients with MRI demonstrable compression (preexisting stenotic spinal canal due to cervical spondylosis, hypertrophied ligamentum flavum) along with spinal cord contusion presented in Frankel grade A/B. Out of twenty one patients who did not have stenotic cervical canals, only four presented in Frankel grade A/B. Two out of these twenty-one patients had normal MRI appearances. There was no MRI evidence of extraneural (discoligamentous) injury in any of the patients. The initial neurological status and MRI appearances are given in Table 2.

Table 2. MRI Appearances (Frankel Grading & T2 Hyperintensity) & Outcome
Group I : Normal Spinal Canals (N = 21)

Frankel grade on admission	No of Cases	Rostrocaudal Extent* of T2 Hyperintensity	Frankel grade after 3 months	No of Cases
A/B	4	>3	A/B	4 (one death)
C	13	2 – 3	D/E	12 One static at C
D	4	2/nil**	E	3

*no of vertebral levels

**two patients had normal MRI

Correlation with Neurological Examination Results

Twenty one out of 29 patients showed isointense cord swelling (Fig 1), one showed hypo- and two showed hyperintense swelling of cord on T1WI. Correlating the T2WI appearances with Frankel grades on admission, it was revealed that rostrocaudal length of T2 hyperintensity of less than one vertebral level (5 mm) were associated with better grades (D/E). There was no consistent pattern

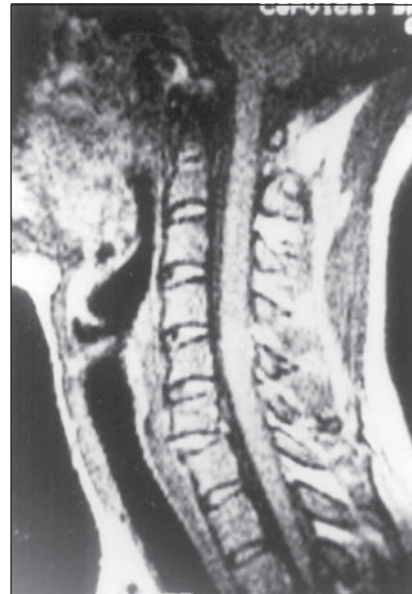

FIGURE 1. T1WI showing isointense swelling of the cord at C5. There is no canal stenosis

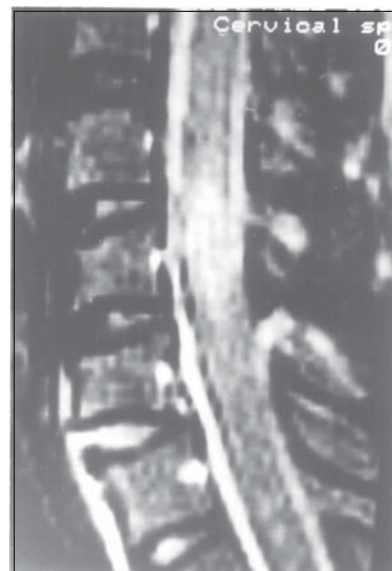

FIGURE 2. T2WI of the same patient showing short segment, diffuse intrinsic hyperintensity at C5

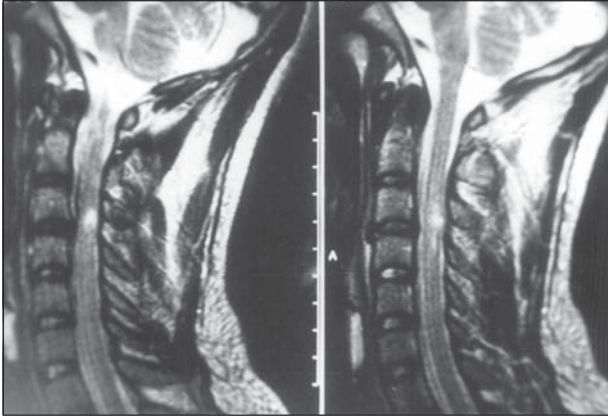


FIGURE 3. T2WI in a normal caliber spinal canal, showing short segment hyperintensity at C3/C4

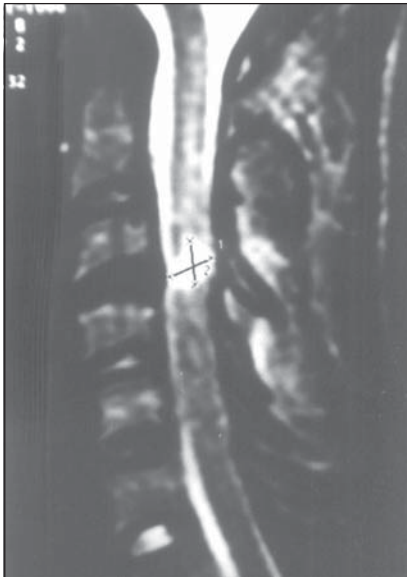


FIGURE 4. T2WI showing normal caliber spinal canal and hyperintensity at C3/C4 in a 17-year-old. Patient remained quadriplegic.

of myelopathy in longer segment T2 hyperintensity, Frankel grades were poor (A/B) when rostrocaudal signal intensity exceeded one vertebral level, with involvement of complete cord thickness (Figs 2,3,4). All eight patients with preexisting stenosis were associated with extrinsic compression due to hypertrophied ligamentum flavum and bony hypertrophy and had long segment rostrocaudal T2 hyperintensity (Figs 5,6). These patients uniformly were in Frankel grade A/B. Of the twenty one patients with normal spinal canals, only four had Frankel grades A/B, and these had T2 hyperintensity ranging from one to three vertebral levels. Fifteen patients had shorter spinal cord segment involvement (5 mm or less) and better neurological grades (Frankel C-E). There was thus a



FIGURE 5. T2WI in an elderly, quadriplegic patient with canal stenosis and intrinsic hyperintensity

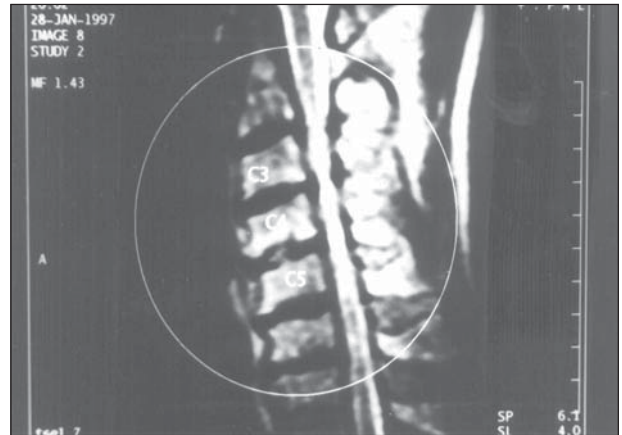


FIGURE 6. T2WI in an elderly, quadriplegic patient with canal stenosis and intrinsic hyperintensity

consistent correlation between the MRI findings and the severity of neurological injury.

Correlation with Neurological Improvement:

The Frankel grade at the time of initial examination was the best predictor of neurological outcome. Nevertheless, a number of MRI variables emerged as significant predictors of neurological improvement from presentation to the most recent follow-up examination.

- (a) presence of T2 Hyperintensity on MRI: this was universally associated with persistent myelopathy.

No patient with Frankel grade A injury and intraaxial hematoma showed any recovery. On the other hand, patients with shorter segment hyperintensity showed neurological improvement, especially when associated with better Frankel grade on admission. Both the patients with normal MRI showed complete neurological recovery.

- (b) Presence of extrinsic compression: Preexisting cervical canal stenosis often due to spondylosis was accompanied by complete cord transection-like picture and showed no response to decompressive laminectomy (Table 3).

**Table 3. MRI Appearances (Frankel Grading & T2 Hyperintensity) & Outcome
Group II: Stenotic Spinal Canals with Spondylotic Myelopathy (n=8)**

Frankel grade on admission	No of Cases	Rostrocaudal Extent* of T2 Hyperintensity	Frankel grade after 3 months	No of Cases
A/B	8	2 – 3	A/B	7 (one death)

No patient with both intraaxial hemorrhage and Frankel grade A injury at presentation showed any recovery of motor function in long-term follow up monitoring. These findings demonstrate the independent importance of neurological function and MRI findings at initial presentation in predicting the ultimate neurological outcome.

Clinical Management:

Eight out of a total study population of twenty nine underwent surgery. All eight of these had stenotic canals causing spinal cord compression due to hypertrophied ligamentum flavum. Laminectomy and excision of the hypertrophied ligament was done and there was visible relief in spinal cord compression. There were two deaths: one post trauma and one in the postoperative period. While both these patients were Frankel grade A at the time of admission, one had normal spinal canal and the other was an elderly male with severely stenotic spinal canal who had undergone decompressive surgery. MRI had shown intraaxial hematoma in both these patients.

Two patients with Frankel grade D and normal MRI appearances showed complete recovery within 72 hours and were diagnosed as having spinal cord concussion.

DISCUSSION

SCIWORA, an acronym for Spinal Cord Injury *Without* Radiographic Abnormality, was coined to describe myelopathic features in children who did not show any

fracture or dislocation on plain radiographs of cervical spine⁷. This type of traumatic myelopathy is rarely described in adults, especially in those with normal caliber spinal canals. Traumatic cervical myelopathy without any fracture or dislocation has often been described in elderly with stenotic spinal canals.

The Phenomenon of SCIWORA

Mechanism of cord damage in young and children differs from that in the elderly with stenotic cervical canals. In the children and young adults, it is likely that hyperflexion and torsion strain of the spinal column is the underlying mechanism of cord damage. Spinal cord is a viscoelastic tissue exhibiting adaptive properties over time during physiological range of movements. Of equal importance is the reciprocal adaptation of the meninges to neutralize the stretching of the cord; the spinal canal elongates between 5 and 9.7 cm during movement ranging from extension to extreme flexion⁸. The requirements of movements are natural and passive and sustained by the spinal cord and roots. During non-physiological conditions of extreme amplitudes, the nervous structures can be subjected to strain, even if for a short time, which exceeds their capacity to adapt⁹. Tethering by dentate ligaments can contribute to stretching of the cord⁹. Rotatory acceleration can lead to cord damage in a manner similar to diffuse axonal injury of the brain, as shearing forces are generated in the spinal cord; as the pia is restrained than rest of the cord by dentate ligaments, gray matter in the spinal cord is often damaged by rotatory acceleration¹⁰. In the elderly with stenotic spinal canals the cord gets damaged in hyperextension injury, which causes narrowing of the canal and the cord to be suddenly compressed between protruding discs, osteophytic spurs, calcified and hypertrophied ligaments, etc¹¹. Sudden compression leads to intramedullary hemorrhage and central infarction of the cord^{11,12}.

Magnetic Resonance Imaging and Prognostication

MRI is an effective and safe imaging procedure for evaluation of spinal cord injuries, and is increasingly being used in the evaluation of traumatic myelopathy. Various studies have reported data from scans acutely (within 24 hours of injury) and within one week after injury, and correlated their findings between the MRI appearances of the injured cord, and neurological function and outcome^{1,2,13,14}. The term SCIWORA has been rendered inaccurate by MRI, and there are reports linking the MRI appearances with acute traumatic central cord syndrome or SCIWORA^{3,4,5,6}. T1WI (spin-echo)

demonstrates the alignment of the cervical spine, integrity of individual bodies, spinal cord swelling¹⁵. Significant changes in signal intensity, whether due to hemorrhage, contusion or edema are best seen in T2 spin-echo imaging. In suitable patients, time consuming sequences such as STIR can be utilized¹⁶. Administration of intravenous Gadolinium improves the sensitivity, and enhancement indicates necrosis of the cord with poor prognosis for recovery⁶. Quencer et al⁵ studied 11 cases of acute traumatic central cord syndrome with MRI and correlated autopsy findings of three fatal cases in the series. Three of the 11 had normal caliber spinal canals and eight had cervical canal stenosis. There was no evidence of blood or blood products in the spinal cords on autopsy. However, there was disruption of myelinated tracts with myelin and axonal degeneration, and debris in white matter. They thus concluded that abnormal signal noted on MRI in these patients is edema. Similar findings were demonstrated by Martin et al⁴ on autopsy of a patient who had died after sustaining SCIWORA. MRI had shown central hyperintense area at C3/C4. Autopsy was done in one of the patients who died in our series and blood in the spinal cord could be demonstrated¹⁷. Presence of compression due to preexisting cervical canal stenosis along with T2 hyperintensity is associated with poor prognosis⁸. In our series too, the eight elderly patients with stenotic cervical canals causing cord compression and intrinsic T2 hyperintensity fared poorly with one death and persistent poor postoperative Frankel grade despite decompressive surgery.

The temporal profile of appearances of intrinsic hematoma and the injured cord has been well documented^{18,19}. It is now established in animal models that the extent of signal change shown on MRI is related to the severity of injury²⁰, and clinical studies also have shown a general association between the extent of signal change and functional outcome^{13,14,21}. Marciello et al² after analyzing 24 cases of acute spinal cord injury with MRI stressed the prognostic significance of the findings of intramedullary hemorrhage. While a normal looking cord had the best prognosis, the outcome progressively worsened with the findings of intramedullary edema involving more than one cord segment, and was worst with intramedullary hemorrhage. In children, SCIWORA is reported to be a mild, partial syndrome and MRI abnormalities were seen only in those with complete deficits²².

In spite of having clear cut features of cervical myelopathy following trauma, MRI may occasionally show a normal spinal cord, as in two of our patients.

Such patients have features of mild cord dysfunction, which usually recover within a short period, and have been diagnosed as having spinal cord concussion (SCC). It was hypothesized that SCC occurred due to functional disturbances of axonal membrane without disruption of structural integrity¹⁰. Zwimpfer and Bernstein²³ defined criteria for diagnosing SCC as follows:-

- (a) No evidence of cervical canal stenosis
- (b) Spinal trauma should have preceded the onset of deficit
- (c) Neurological deficit should be consistent with spinal cord involvement at the level of injury
- (d) There should be complete recovery in 72 hours

Now it is known that there are limitations of low to midfield MRI and gradient echo sequences compared with high field spin echo imaging, such as relatively poor spatial resolution and signal-to-noise ratio, and limited slice thickness²⁴. Hence subtle cord changes of edema could be missed²⁵, which can now be picked up by suitable fat suppression sequences²².

CONCLUSION

The entity of SCIWORA is undergoing further evaluation with the utilization of MRI for evaluation of traumatic cervical myelopathy. Usually reported in children, SCIWORA may be seen in adults with normal sized spinal canals also. Extrinsic compression due to preexisting stenotic spinal canal results in more severe injury in contrast to that sustained by those without stenosis. While it is established that the best prognostic indicator in SCIWORA is the initial Frankel grade, MRI plays an important role in its assessment and prognostication. A normal looking cord carries the best prognosis for neurological recovery in SCIWORA. T2 hyperintensity is likely to be due to spinal cord edema or intramedullary hematoma. Small focal zones of T2 hyperintensity carry a better prognosis, while a long rostrocaudal region of T2 hyperintensity especially when accompanied by extrinsic compression due to spondylotic stenosis carries a poor prognosis, in spite of surgical decompression.

REFERENCES

1. Selden NR, Quint DJ, Patel N, et al. Emergency magnetic resonance imaging of cervical spinal cord injuries: Clinical correlation and prognosis. *Neurosurgery* 1999; 44: 785 – 793.
2. Marciello M A, Flanders A E, Herbison G J, et al. Magnetic resonance imaging related to neurologic outcome in cervical spinal cord injury. *Arch Phys Med Rehabil* 1993; 74: 940 – 946.

3. Hayashi K, Yone K, Ito H, Yanase M, Sakou T. MRI findings in patients with a cervical spinal cord injury who do not show radiographic evidence of a fracture or dislocation. *Paraplegia* 1995; 33: 212 – 215.
4. Martin D, Schoenen J, Lenelle J, Reznik M, Moonen G. MRI-pathological correlation in acute traumatic central cord syndrome. Case report. *Neuroradiology* 1992; 34: 262 – 266.
5. Quencer R M, Bunge R P, Egnore M, et al. Acute traumatic central cord syndrome. MRI-pathological correlations. *Neuroradiology* 1992; 34: 85 – 94.
6. Shimada K, Tokoika T. Sequential MRI studies in patients with cervical cord injury but without bony injury. *Paraplegia* 1995; 33: 573 – 578.
7. Pang D, Wilberger JE, Jr. Spinal Cord injury without radiographic abnormalities in children. *J Neurosurg* 1982; 57:114-129.
8. Chirossel J P, Vanneuville G, Passagia J G, et al. Biomechanics and classification of traumatic lesions of the spine. In, Symon L (ed): *Advances and Tech Standards in Neurosurgery*, Vol 22. New York: Springer Verlag, 1995, pp 56 – 137.
9. Wilder B L. Hypothesis: The etiology of midcervical quadriplegia after operation with the patient in the sitting position. *Neurosurgery* 1982; 11: 530 – 531.
10. Kobrine A I. The neuronal theory of experimental traumatic spinal cord dysfunction. *Surg Neurol* 1975; 3: 261 – 264.
11. Koyanagi I, Iwasaki Y, Hida K, et al. Acute cervical cord injury without fracture or dislocation of the spinal column. *J Neurosurg (Spine I)* 2000; 93: 15 – 20.
12. Taylor A R. The mechanism of injury to the spinal cord in the neck without damage to the vertebral column. *J Bone Jt Surg (Br)* 1951; 33: 543 – 547.
13. Flanders A E, Schaefer D M, Doan H T, et al. Acute cervical spine trauma: correlation with degree of neurological deficit. *Radiology* 1990; 177: 25 – 33.
14. Kulkarni M R, McArdle C B, Kapanick H T, et al. Acute spinal cord injury. MR imaging at 1.5T. *Radiology* 1987; 164: 837 – 843.
15. Takhtani D, Melhem ER. MR imaging in cervical spine trauma. *Magn Reson Imaging Clin N Amer* 2000; 8:615-634.
16. White ML. MR imaging in cervical spine trauma. *Magn Reson Imaging Clin N Amer* 2000; 8:453-470.
17. Bhatoe H S. Cervical spinal cord injury without radiological abnormality in adults. *Neurology India* 2000; 48: 243 – 248.
18. Gomori J M, Grossmann R I, Goldberg H I, et al. Intracranial haematomas: imaging by high field magnetic resonance at 1.5T. *Radiology* 1985; 157: 87 – 93.
19. Tavri O (1994). MRI in spinal trauma. In, Ramani P S, Sharma A (eds). *Modern trends in the management of Neurotrauma*. Dept of Neurosurg, LTGM Hospital, Bombay pp 171 – 174.
20. Fujii H, Yore K, sakou I. Magnetic resonance imaging study of experimental acute spinal cord injury. *Spine* 1993; 18: 160 – 167.
21. Silberstein M, Hennessey O. Implications of focal spinal cord lesions following trauma – evaluation with magnetic resonance imaging. *Paraplegia* 1993; 31: 160 – 167.
22. Dare A O, Dias M S, Li V. Magnetic resonance imaging correlation in pediatric spinal cord injury without radiographic abnormality. *J Neurosurg (Spine I)* 2002; 97: 33-39.
23. Zwimpfer T J, Bernstein M. Spinal cord concussion. *J Neurosurg* 1990; 894 – 900.
24. Mascalchi M, Dal Pozzo G, Dini C, et al. Acute spinal trauma: the prognostic value of MRI appearances at 0.5T. *Clin Radiol* 1993; 48: 100 – 108.
25. Voyvodic F, Dolinis J, Moore V M, et al. MRI of car occupants with whiplash injury. *Neuroradiology* 1997; 39: 35 – 40.
26. Frankel HL, Hancock DO, Hyslop G, et al. The value of postural reduction in the initial management of closed injuries of the spine with paraplegia and tetraplegia. *Paraplegia* 1969; 7:179-192.