

# Stabilization for Sub Axial Cervical Spine Injury

Col P K Sahoo MCh, Col Prakash Singh MCh, Lt Col HS Bhatoe MCh

Department of Neurosurgery, Army Hospital (R & R) Delhi Cantt 110010

**Abstract :** A retrospective analysis of sixty patients with cervical spinal cord injury operated during Jan 2001 to Dec 2003 was carried out. Fifty four (90%) were male and six were female patients. Amongst them 45 (75%) were in the age group 21 to 40 years. Thirty six (60%) sustained injury by vehicular accident and 24 due to fall, wrestling, boxing, obstacle crossing, terrorist activities, cattle and camel hits. All patients presented with evidence of post-traumatic cervical spinal cord injury and evaluated with Frankel's neurological grade at admission. Six patients presented with grade 'A', 02 grade 'B', 36 grade 'C', 16 grade 'D' neurological deficit as per Frankel's classification. Plain radiography, Computerised tomography (CT) Scan and Magnetic Resonance Imaging (MRI) of cervical spine revealed disc prolapse in 30, anterior thecal compression due to burst/compression fracture in 24 and dislocation in 06 patients. Cord contusion and haematoma in 08 and cord transection in 04 patients were detected in MRI. Anterior Cervical Microdiscectomy (ACD) and fusion in 10; discectomy, fusion and titanium plating in 20; corpectomy and bone grafting in 05; corpectomy and cage placement in 03; corpectomy, bone grafting and titanium plating in 16, post fusion was carried out in 06 cases. Postoperative radiography showed good alignment, stability of spine and implants in position. Outcome was evaluated again with Frankel's scale. There were 26 patients with grade 'E', 25 grade 'D', 01 grade 'C', 06 patients did not show any recovery and 02 patients died. Recovery was rewarding in patients with initial incomplete spinal cord injury.

**Keywords:** cervical spine injury, functional recovery, stabilization

## Introduction

Acute injuries to cervical spine and spinal cord are among the common causes of severe disability and may be associated with quadriplegia and respiratory distress leading to morbidity and mortality. Better understanding of the mechanism of spinal cord injuries, biomechanics of spine and pathophysiological changes that occur in spinal cord following injury has revolutionised the management in recent years.

The availability of computerised tomography (CT), magnetic resonance imaging (MRI) scans has further aided the diagnostic evaluation of cervical spine injury by delineating the exact site, extent of injury, stability of spine and guides for appropriate surgical approaches. Faced with cervical spine injury, the initial goal is to save life in those patients who are often victims of polytrauma. Prevention of neurological deterioration comes second and finally spinal alignment, stability, rapid mobilization and early rehabilitation has to be considered. It is now possible to operate cervical spinal cord injured patients early in the presence of respiratory and cardiovascular compromise state, in a neuro intensive care unit (ICU) with advanced monitoring and ventilator facilities.

The pioneering work of Smith and Robinson and Cloward in anterior removal of cervical disc and fusion

Address for correspondence: Col P K Sahoo MS, M Ch, Department of Neurosurgery, Neuro Sciences Centre, Army Hospital (R&R), Delhi Cantt - 110 010

is a commonly performed procedure today<sup>1,2</sup>. The insight provided by these basic surgical approaches, use of operating microscope, high speed drill, image intensifier, availability of bone bank and titanium cervical spine locking plate system for stabilisation of spine has made significant difference in the outcome of cervical spinal cord injured patients. In recent years the field of spine surgery invaded by multiple newer implants and instruments and now development is such that is difficult to keep abreast of the different instrumentation available in the market.

## Materials and Methods

Over the past three years from Jan 2001 to Dec 2003, 114 patients with cervical spinal injury were admitted and managed at our institution. Amongst them 60 patients underwent surgery during the same period for cervical spinal cord compression and instability. A retrospective analysis was performed for 60 surgically treated patients with cervical spinal cord injury to evaluate mode, extent of Neurological deficit, types of injury, surgical procedures performed and functional outcome.

On admission patients were clinically evaluated for mode of injury. Extent of neurological deficit was recorded as per Frankel's grade. Associated injuries were noted. Forty five patients (75%) in the present series were young adults in the age group of 21 to 40. Males 54 (90%) were affected predominantly. The maximum number of patients 36 (60%) sustained injury due to road

traffic accident. Other causes of injury were fall from height in 15; missile injuries 02; wrestling 02; boxing 02; cattle and camel hits in 03 patients. The extent of neurological deficit were recorded as per Frankel's grade (Table 1).

**Table 1. The Extent of Neurological Deficit as per Frankel's grade**

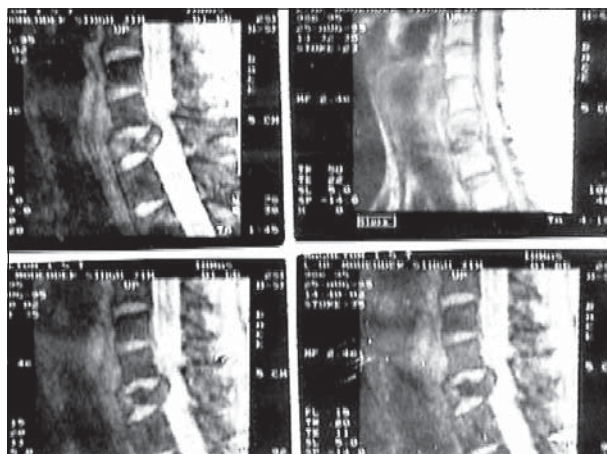
Grade	Description	No. of Patient
Grade 'A'	Complete motor and sensory loss	06
Grade 'B'	Complete motor and incomplete sensory loss	02
Grade 'C'	Motor preserved below the injured segment but no practical use	36
Grade 'D'	Preserved motor power with minimal function	16
Grade 'E'	Normal Motor and Sensory Function	00

The maximum number of patients (12) had associated extremity bony injuries. Other associated injuries were head injury in 06, chest injury in 04 and abdominal injury in 02 patients.

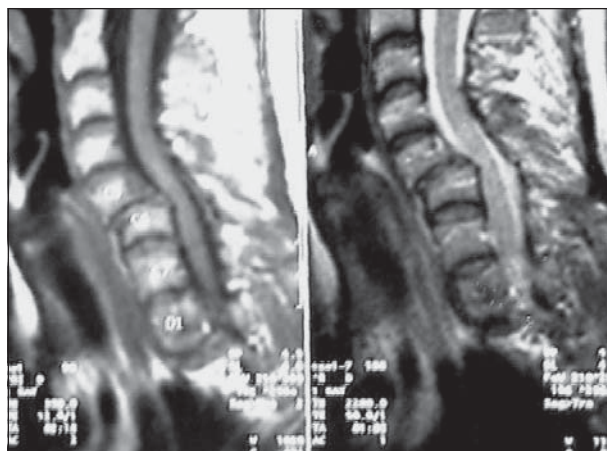
Anterior posterior (AP) and translateral radiograph, Computerized Tomography (CT) Scan and Magnetic Resonance Imaging (MRI) scan of cervical spine was carried out in all patients. Patients were put on Gardner Wells skull traction and operated within 01 to 04 weeks of admission. The outcome was evaluated with Frankel's scale after 03 months, 06 months and 01 year. The spinal alignment, stability and implant position was confirmed by post op and follow up radiography.

MRI scan done in all patients delineated anterior thecal compression due to disc prolapse in 30 (Fig. 1), burst/compression fracture 24 (Fig. 2) and dislocation in 06 (Fig. 3). Cord oedema, haematoma, contusion was present in 08 and cord transection was present in

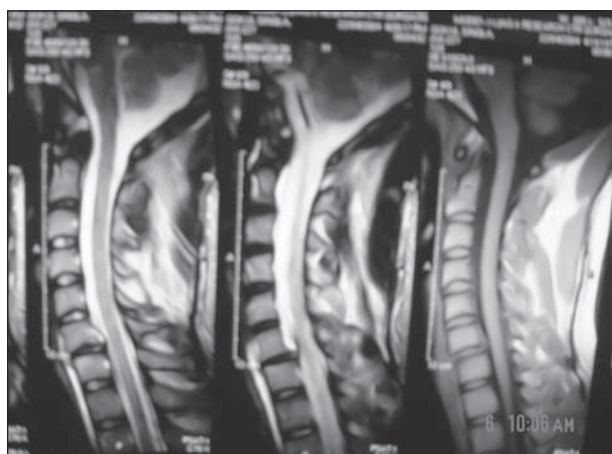
04 patients. The type and level of injury was delineated by MRI (Table 2).



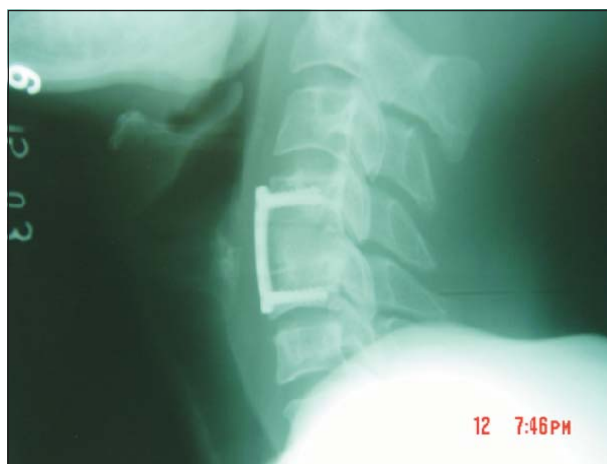**FIGURE 2.** Burst Compression fracture C5



**FIGURE 3.** Dislocation C5 – C6



**FIGURE 1.** Disc Prolapse C6 –C7

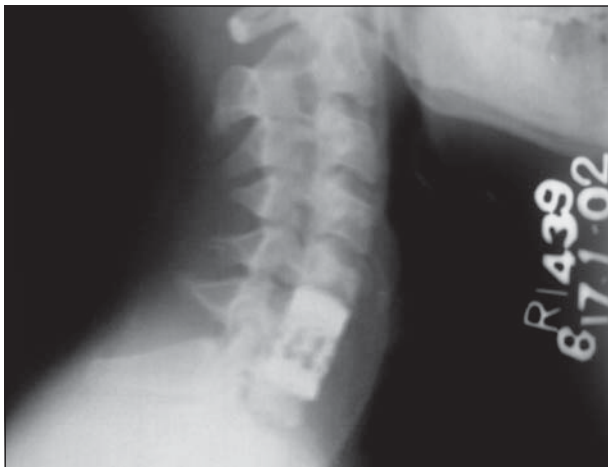

**FIGURE 4.** Discectomy, fusion and plating

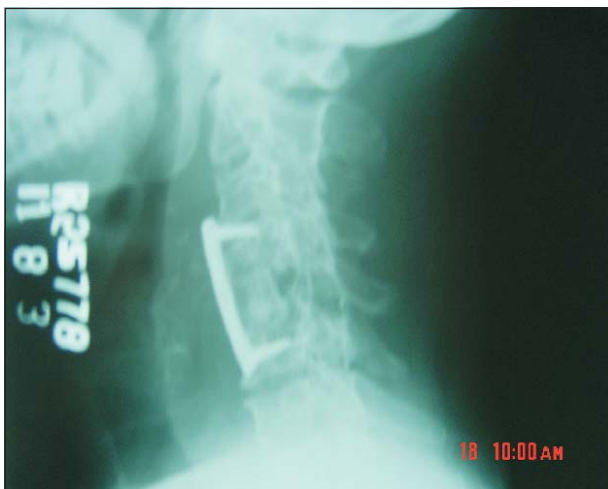**Table 2. Type and Level of Injury : Radiography, CT Scan and MRI Scan**

	C3-C4	C4-C5	C5-C6	C6-C7	Total	
Disc Prolapse	—	04	20	06	30	
Dislocation	—	02	02	02	06	
	C3	C4	C5	C6	C7	Total
Burst Fracture	—	02	03	02	01	08
Compression Fracture	—	05	07	03	01	16

Anterior Cervical Microdiscectomy (ACD) and fusion was done in 10 patients; discectomy, fusion and titanium plating with unicortical screw in 20 (Fig. 4), corpectomy and bone grafting in 05; corpectomy and cage placement in 03 (Fig. 5); corpectomy, bone grafting and plating in 16 (Fig. 6), and posterior fusion using titanium cables & apofix was carried out in 06 patients (Table 3).



**FIGURE 5.** C6 Corpectomy Cage Placement



**FIGURE 6.** Corpectomy, grafting and plating

**Table 3. Operative Procedures Carried Out (No. 60)**

Sl. No.	Procedure	No.
1.	Anterior Cervical Microdiscectomy & Fusion	10
2.	Anterior Cervical Microdiscectomy + Fusion +Synthes Plating	12
3.	Anterior Cervical Microdiscectomy + Fusion + Zephir’s Plating	08
4.	Corpectomy & bone grafting	05
5.	Corpectomy + Titanium Cage Placement	03
6.	Corpectomy + Bone grafting + Synthes Plating	10
7.	Corpectomy + Bone grafting + Zephir’s Plating	06
8.	Reduction & Post Fusion with Titanium Cables	03
9.	Reduction & Post Fusion with Apofix	03

**RESULTS**

Post operatively the neurological recovery of patients was assessed as per Frankel’s grade after 03 months, 06 months, and 01 year (Table 4). Excellent recovery was observed in 25 patients and none of the patients with Frankel’s ‘A’ who had cord trans section in MRI scan showed neurological improvement. Post op radiography revealed the spinal alignment was good in stable condition and there was no implant failure.

**Table 4. Recovery as per Frankel's Grade**

Initial Grade	No.	Improved				No Improvement				DIED
		B	C	D	E	A	B	C	D	
A	06	—	—	—	—	05	—	—	—	01
B	02	—	—	—	—	—	01	—	—	01
C	36	—	—	25	11	—	—	—	—	—
D	16	—	—	—	15	—	—	—	01	—

**DISCUSSION**

The goal of surgery in cervical spinal cord injury is to prevent or minimize neurologic injury, provide an optimal environment for the spinal cord and nerve roots to recover from damage and to obtain a stable healed cervical spine. This goal is achieved by realigning bony fragments, reducing the dislocation, decompression of the spinal cord of disc material anteriorly or bony fragment both anteriorly and posteriorly as delineated by MRI and stabilizing the spine.

Generally accepted technique for traumatic Subluxation, dislocation, locked facets are reduction and stabilisation by posterior approach<sup>3,4</sup>. The posterior fixation technique with wire and bone after reduction is simple, safe and effective for stabilisation of dislocations



of cervical spine. However, the metallic wire is not MRI compatible and throws artifacts on both CT and MRI scans. Therefore, Presently available titanium cables and clamps<sup>5</sup> are used for posterior fixation. In this series also this technique was effectively used in 06 patients without any complication. Besides being simple, this system is also MRI compatible. Hence post op MRI can be performed with minimal artifact.

The anterior approach is mainly used in injuries involving anterior column of the spine i.e., those concerning the vertebral bodies and intervertebral discs. The pioneering work of Smith & Robinson and Cloward in anterior removal of cervical disc and fusion is commonly performed procedure today<sup>1, 2, 6</sup>. In the present series 10 patients with cervical spinal cord injury due to disc prolapse were managed with anterior cervical micro discectomy and Smith Robinson's grafting and another 20 patients with discectomy, bone fusion and anterior cervical syntheses/ Zephirs titanium plating.

Anterior compression due to burst or wedge compression fracture of vertebral body needs corpectomy<sup>7, 8</sup>.

Our experience with corpectomy and cortico-cancellous autogenous iliac bone graft and anterior cervical fusion adequately document that, the procedure is simple, safe, biomechanically sound providing stability with good results<sup>9</sup>. In the present series corpectomy and bone grafting was done in 05 cases; and corpectomy and titanium cage placement was done in 03 cases.

Orozco in 1970 first used anterior cervical plate in case of cervical trauma. Subsequently Caspar standardized the method with exact operating steps and instrumentation in 1981<sup>10, 11, 12, 13</sup>. The basic principle was based on the AO work group's recommendations for metal plate osteosynthesis. Fast and stable bone healing is observed if there is correct realignment, good bone to bone contact, compression and absolute immobilization by anterior cervical instrumentation with metallic plates and screws. Moreover good neurologic outcome is predicted because of surgical immobilisation. Caspar's trapezoid plate osteosynthesis technique incorporates AO principles, gives optimal neural healing environment because of liberal bony decompression. This is safe, stable, and strong and gives immediate stability.

Operative internal fixation of cervical spine provides improved segmental stability and reduces the need for prolonged bed rest and/or rigid external orthosis. To prevent screw loosening and graft slippage the Caspar plating system requires a bicortical purchase. Other plate

systems available include the AO or H plate systems developed by Orozco. The advantages of cervical plating with bicortical screws are unlimited options in screw placement and long-term clinical studies are available with success. The disadvantages of cervical plating with bicortical screws are the operative procedure is technically demanding, require intra operative fluoroscopy, risk of spinal cord injury and screw pull out exists if not careful.

From the first plate designed by Bohler and the early Caspar plate, numerous plates have been designed to overcome the problems associated with screw back out, settling, imaging etc. these plate systems may be classified as (a) Constrained : having fixed screws at both ends of the plate and designed to offer maximum stability at the graft receptor site (Orion<sup>14, 15</sup>, CSLP<sup>16</sup>, Atlantis). (b) Semi Constrained : having variable screws at both ends of the plate and designed to permit maximum loading at the graft receptor site (Atlantis, Zephir). (c) Hybrid : having a combination of fixed and variable screws at both ends of the plates and designed to allow maximum flexibility (Atlantis, Premier).

To reduce the incidence of screw pullout and graft and slippage, the locking plate system using cancellous screws was developed by Morscher. Other locking plate systems like Synthes<sup>16</sup>, Codman, Orion<sup>14, 15</sup>, Zephir, Atlantis, and Premier are also available. All are made of titanium to minimise MRI artifacts. These locking plate systems offers immediate stability, with the use of multiple fixation points, and a rigid plate screw interface. They are safer to use, as they do not require a bicortical purchase, thus avoiding possible injury to cord, roots or vascular structures. It should be noted that the Morscher system has some limitations due to lack of flexibility in screw placement and angulation. Presently available variable angle Atlantis and Premier screws obviates these difficulties.

The advantages of unicortical screw with cervical spine locking plate system are easy placement and fluoroscopy is not mandatory. Fluoroscopy may be utilised to optimise plate selection and screw placement. Anterior cervical stabilisation after corpectomy was carried out in 16 patients with titanium plate and unicortical screws of synthesis and Zephir system in this series.

In the present series patients were taken up for surgery between one to four weeks after admission. It has been suggested that neurological recovery is better if surgical treatment is done early<sup>17</sup>. However Benzel and Larson<sup>7</sup>

advocated delayed surgical intervention in a retrospective analysis of 99 surgically treated patients with lower cervical spine injuries after they are metabolically and neurologically stable.

Although it is difficult to measure neurological function, measurement is necessary for the evaluation and prediction of outcome following surgery. The Frankel's system is most widely used though modifications have developed. Maynard et al revised the Frankel's scale to improve evaluation of motor function by using five functional grades<sup>18</sup>. Tator et al developed a scale that improves upon the Frankel's system by including an assessment of sensory function<sup>19</sup>. By and large the original Frankel's grading system remains the one most in use. In this study Frankel's grades was followed for neurological assessment and functional recovery of patients

In the present series all the patients showed neurological recovery except 06 with initial Frankel grade 'A' and 02 with Frankel's grade 'B' who failed to recover and 02 of them died. The failure to recover Frankel's grade 'A' patients is consistent with observation of others<sup>7</sup>. Amongst 36 patients with Frankel 'C', 11 had excellent and 25 had good recovery. Fifteen patients with Frankel 'D' showed excellent recovery. In the present series there were 02 deaths due to spinal shock, respiratory compromise and multiple injuries.

Anterior cervical titanium plating with unicortical screws for cervical spine injury was performed in 36 patients in this series. The postoperative and follow up radiological alignment was good and plates were in situ. There was no implant failure/ screw pull out. Patient mobilisation and ambulation was fast without rigid external orthosis. This study documents stabilization of cervical spine and functional recovery following surgery was rewarding in patients with initial incomplete spinal cord injury.

## REFERENCES

1. Smith GW, Robinson RA : Anterio-lateral cervical disc removal and interbody fusion for cervical disc syndrome. *Bull John Hopkins Hosp* 1955; 96 : 223-224.
2. Cloward RB : The anterior approach for removal of ruptured cervical disc. *J Neurosurg* 1958; 15 : 601-606.
3. Bohlman HH : Acute fractures and dislocations of the cervical spine, an analysis of 300 hospitalised patients and review of literature. *JBJS* 1979; 61A : 1119 1142.
4. Al Baz MO, Mathur N : Modified technique of tension band wiring in flexion injuries of the middle and lower cervical spine. *Spine* 1955; 20 : 1241 – 1244.
5. Aldrich EF, Weber PB, Crow WN : Halifax interlaminar clamp for posterior cervical fusion : a long term follow up review, *J Neurosurg* 1995; 78 : 702 708,
6. Epstein NE : Anterior cervical discectomy and fusion without plate instrumentation in 178 patients. *J Spinal Disord.* 2000; 13 : 1 – 8.
7. Benzel EC, Larson SJ : Functional recovery after decompressive spine operation for cervical spine fractures. *Neurosurgery* 1987; 20 : 742-746.
8. PS Ramani : Stabilisation of lower cervical spine injuries. *Neurol India (supplement)* 1995; 43 : 113-118.
9. Sahoo PK, Sharma JR, Gill HS. Functional recovery after corpectomy and corticocancellous iliac crest bone grafting for cervical spinal cord injury, Initial experience. *Med J Armed Forces Ind* 1998; 54 : 208 211
10. Casper W, Barbier D, Klara PM : Anterior cervical fusion and casper plate stabilisation for cervical trauma. *Neurosurgery* 1989; 25 : 491-502.
11. CE Deopujari, SN Bhagawati, JA Pachor, GD Parulekar : Anterior cervical Osteosynthesis trapezoid fusion with Casper technique. *Neurol India (supplement)* 1995; 43 : 125-129.
12. Randle MJ, Wolf A, Levi L, et al : The use of anterior Caspar plate fixation in acute cervical spine injury. *Surg Neurol* 1991; 36 : 181 – 189.
13. Bose B : Anterior cervical fusion using Caspar plating : analysis of results and review of the literature. *Surg Neurol* 1998; 49 : 25 – 31.
14. Taha JM, Zuccarello M : ORION anterior cervical plate system. *Neurosurgery* 1996; 38 : 607 – 609.
15. Heidecke V, Rainov NG, Burkert W : Anterior cervical fusion with the Orion locking plate system. *Spine* 1998; 23 : 1796 – 1802.
16. Spivak JM, Chen D, Kummer FJ : The effect of locking fixation screws on the stability of anterior cervical plating. *Spine* 1999; 24 : 334 – 338.
17. Carol M, Ducker TB, Byrnes DP : Mini myelogram in cervical spinal cord trauma. *Neurosurgery* 1980; 7 : 219-224.
18. Maynard FM, Reynolds GG, Fountain F Wilmot C Hamilton R: Neurological prognosis after traumatic quadriplegia. *J Neurosurg* 1979; 50 : 611 616.
19. Tator CH, Towed DW, Schwartz MI : Sunnybrook cord injury scales for assessing neurological injuries and neurological recovery, in Tator CH (ed) : *Early management of acute spinal cord injury*. New York, Robin Press 1982; 7 24.