

Post-traumatic Cranial Nerve Injury

Purav Patel M Ch, S Kalyanaraman FRCS, J Reginald M Ch, P Natarajan M Ch, K Ganapathy M Ch
K R Suresh Babu M Ch, A Vincent Thamburaj M Ch, B Chendhlnathan M Ch, M Balamurugan M Ch
Department of Neurosurgery, Apollo Speciality Hospitals, Chennai

Abstract: Injury to the cranial nerves is a common accompaniment of head trauma. Incidence of cranial nerve injury in head injury varies in various published literature. Indian literature on post-traumatic cranial nerve injuries as whole is scanty. Aims of this study are to document the incidence of cranial nerve injuries in head injuries, to correlate incidence with radiological findings, to assess recovery time with respect to signs and symptoms at initial presentation and to stress the importance of clinical examination in head injured patients. We studied 794 consecutive cases of head injured patients from May 2002 to November 2004. One hundred patients were found to have cranial nerve injuries and were included in this study. Clinical examination of cranial nerves was done meticulously on a daily basis. Patients were followed up at monthly interval for a minimum of six months.

Keywords: Cranial nerve injury, head injury

INTRODUCTION

Hippocrates first described cranial nerve injury (optic nerve) following head injury when he wrote, "dimness of vision occurs injuries of the brow and those placed slightly above"¹. Although every student of surgical neurology is taught to examine the head injured patient meticulously and look for signs and symptoms of cranial nerve injury, there is a paucity of documentation especially of its incidence, clinical significance with special reference to disability and prognosis. In this study we find that a number of common beliefs are belied, especially with reference to the incidence in relation to severity of injury and multiplicity of cranial nerve injuries.

MATERIALS AND METHODS

We studied 794 consecutive cases of head injury from May 2002 to Nov 2004; 100 of these patients were found to have cranial nerve injuries and were included in this study. The patients were grouped into mild, moderate and severe head injury, based on the GCS at the time of admission – mild (13-15), moderate (9-12), severe (<9). All patients were investigated with cranial scan of the brain at the time of admission. Clinical examination of cranial nerves was done meticulously on a daily basis. High-resolution temporal bone CT scan, audiogram, VEP and other investigations were done when clinically indicated. Patients were followed up at one-month intervals.

OBSERVATIONS AND RESULTS

Cranial nerve injuries were seen in 100 of 794 patients (652 males & 142 females) with head injury – an incidence of

Address for correspondence: Purav Patel M Ch, Consultant Neurosurgeon Apollo Speciality Hospital 320, Chennai
e-mail: Post traumatic cranial nerve injuries

12.6%. Of the 100 patients, 50 had mild, 26 had moderate and 24 had severe injury. There was a preponderance of male patients (87 males and 13 females). Sixty seven patients (67%) had single cranial nerve injury (Table 1): these included facial (20 patients), oculomotor (12 patients) and optic (11 patients) nerve injury. Multiple cranial nerve injury was seen in 32 patients (32%) (Table 2).

Table 1 : Post-traumatic single cranial nerve injury.

No. of patients	Cranial nerve involvement
03	First cranial nerve
11	Second cranial nerve
12	Third cranial nerve
07	Fourth cranial nerve
07	Sixth cranial nerve
20	Seventh cranial nerve
07	Eighth cranial nerve

Table 2 : Post traumatic multiple cranial nerve injuries.

No. of patients	Cranial nerve involvement
05	Second, third, fourth & sixth
05	Sixth & seventh
05	Seventh & eighth
02	Second & seventh
02	Third & fourth
02	Third, fifth (frontal branch) & sixth
01	First, third, fourth & sixth
01	First, second & sixth
02	First & second
01	Second, sixth & seventh
01	Third, fourth, fifth (maxillary branch) & sixth
02	Fifth & seventh
01	Fourth, sixth & seventh
01	Seventh, ninth & tenth
01	Ninth & tenth

Olfactory Nerve Injury

Seven patients (0.88%) had post-traumatic olfactory dysfunction(Fig-1). Four of these patients had multiple cranial nerve injuries (three patients had moderate head injury; one patient had severe head injury). All three patients with only olfactory nerve dysfunction had sustained mild head injury. CSF rhinorrhea (3 patients) & total loss of smell (5 patients) were common findings. One patient with cribriform plate fracture and associated medial temporal lobe contusion had anosmia with olfactory hallucinations (follow up – 8 months). Two patients showed minimal improvement in perception of smell with 12 to 16 months follow up. The remaining four patients have shown no improvement over a follow up of 10 to 18 months.

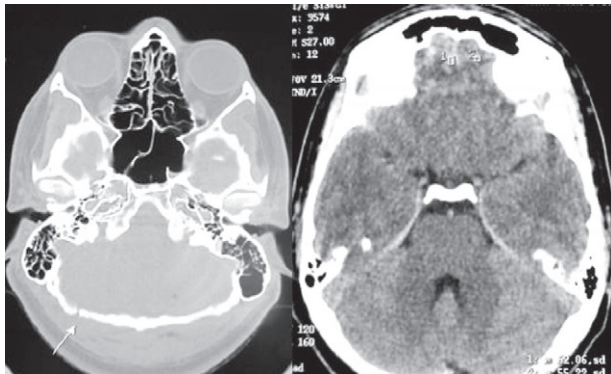


FIGURE 1. Patient with bilateral anosmia due to right occipital blow (Fracture) & bifrontal hemorrhagic contusions

Optic Nerve Injury

Twenty-two patients (2.78%) had post-traumatic optic nerve injury. Eleven of these patients had other associated cranial neuropathies. Mild head injury (13 patients) was more common compared to moderate (5 patients) and severe (4 patients) head injury. Frontal and fronto-temporal blow to the head (14 patients) were common modes of injury(Fig-2). Frontal contusions (8 patients), temporal contusions (3 patients) and CSF rhinorrhea (4 patients) were the other common findings in patients with moderate to severe head injury. Four patients (two children) had bilateral optic nerve injury including one child with bilateral total visual loss. Orbital fractures were present in all 22 cases. Multiple orbital fractures extending up to orbital apex (9 patients) were more commonly seen followed by fracture of the lateral wall (7 patients), medial wall (3 patients) and roof of orbit alone (3 patients). In all patients visual acuity was compared using a standard ophthalmologic conversion from the values of no light perception, light perception, perception of hand movement and finger counting.

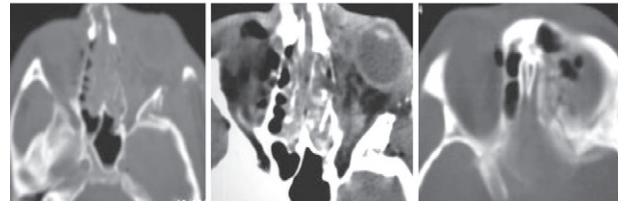


FIGURE 2. Patient with left orbital wall fracture going up to apex causing optic nerve contusion.

Table 3: Steroid Treatment in Optic Nerve Injury [Methyl Prednisolone]

No. of	Steroid treatment	Improvement of vision patients
10	Inj. Methyl-prednisolone 1 gm I.V. over 1 hour followed by 500 mg. 6 th hourly for 4 days, followed by Tab Prednisolone for 4 to 6 weeks in tapering dose (starting from 30 mg twice daily).	** *** ****. Blurred vision to counting fingers 2 feet(1 patient) hand movements to counting fingers at 2 feet (3 patients) minimal improvement in bitemporal hemianopia (2 patients) counting fingers at 2 feet to near normal vision (3 patients).
5	Inj. M.P 1 gm. I.V. over 1 hour followed by 500 mg. 6 th hourly for 2 days, followed by Tab Prednisolone for 4 to 6 weeks in tapering dose (starting from 30 mg twice daily).	Vision remain status (one patient with perception of hand movement and other patient with counting fingers at 2 feet distance)
1* (3 year child with bilateral total visual loss)	Tab. Prednisolone 5mg. Twice daily for 4 weeks followed by Inj. ACTH 25 I.U. subcutaneously every week for 6 weeks.	No improvement
1(12 year boy with bilateral optic nerve injury)	Tab. Prednisolone 10 mg. Twice daily for 2 weeks followed by 2 mg. Twice daily for 2 weeks followed by 5 mg. Once daily for 1 week.	Bilateral blurred vision to counting fingers at 2 feet distance within 8 weeks.

Three patient with bony impingement of optic nerve (based on CT orbit) underwent surgery within twelve hours of injury under cover of Methyl Prednisolone, of which one patient showed minimal vision improvement (perception of hand movement to finger counting at 2 feet distance) at 2 weeks and in other two patients vision remained static (one patient with perception of hand movement and other patient with counting fingers at 2 feet distance) at 4 to 6 months follow up. Intravenous steroid (Methylprednisolone) followed by oral steroid in tapering doses were given to 18 patients. Improvement of visual acuity was varied with recovery period ranging from 4 days to 8 weeks with follow up period of 8 months to 2 years. One patient with total visual loss (out of five) showed visual acuity improvement up to counting fingers at 2 feet distance within 5 weeks. One patient with orbital roof fracture alone (GCS – 15/15), presented with counting fingers at one foot distance and total ophthalmoplegia, which recovered to normal visual acuity within 4 days with minimal persistent sixth nerve palsy at one year follow up.

In six patients (excluding patients with total blindness) visual acuity remained static.

Oculomotor Nerve Injury

Total 23 patients developed post-traumatic oculomotor nerve injury with an incidence of 2.9% including 11 patients with multiple cranial nerve injury. Severity of injury was varied (12 patients – severe, 9 patients – mild & 3 patients with moderate head injury). 11 patients had skull base fractures (7 patients with severe head injury). Significant improvement in extra-ocular muscle paresis in patients with non-penetrating trauma suggests neuropraxia type of injury to some degree. Bilateral oculomotor nerve palsy (2 patients) and complete oculomotor nerve palsy (10 patients) were more common with severe head injury. In conscious patients with partial ptosis the prime symptoms were mixed horizontal and vertical binocular diplopia. Out of 5 patients with associated brain stem contusions, 2 patients had bilateral nuclear palsy (rostradorsal midbrain). One patient with discrete contusion at dorsal midbrain tegmentum presented with bilateral ptosis with moderately dilated pupils (Fig-3). Out of two patients with anterior tegmentum midbrain contusion, one patient developed Weber syndrome. The dilated, light-fixed pupil with turned out eyeball was helpful in diagnosing third nerve injury in unconscious patients. One patient with extensive skull base fracture had involvement of cranial nerves III, IV, V1, V2, VI (Fascicular cavernous sinus portion involvement). The recovery period for complete third nerve palsy was long (6 weeks to several months). Near normal medial gaze recovery was more commonly seen within first two months while upward and downward gaze recovery was incomplete and delayed (more than 3 months).

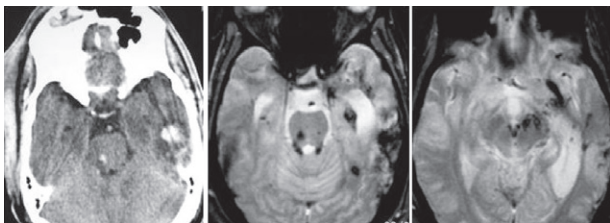


FIGURE 3. CT and MRI (FLAIR image) of the patient with bilateral nuclear third nerve injury.

Trochlear Nerve Injury

Seventeen patients had post-traumatic trochlear nerve injury with an incidence of 2.14%. Of these, 10 patients had with multiple cranial nerve injury. Mild head injury (10 patients) was more common compared to moderate (2 patients) and severe head injury (5 patients). Diagnosis of trochlear nerve palsy was made on the basis of classic head-tilt test of Bielchowsky, presence of hypertropic eye

with relation to gaze and presence of vertical diplopia with occasional torsion component. In unconscious patients the diagnosis was possible after the patient regained consciousness. Two patients had bilateral trochlear nerve injury (torsion diplopia and down gaze horizontal diplopia), of which one patient had dorsal midbrain contusion (nuclear injury) with subarachnoid hemorrhage in cisterna ambiens (Fig-4). Other patient had concussion head injury (GCS-14/15) with occipital scalp hematoma. Midfacial fractures (5 patients) and supromedial orbital wall fractures (3 patients) were other common findings. In rare cases patient with trochlear nerve injury may tilt head to the same side of nerve damage to ignore the second image (Fig-5). Spontaneous complete recovery of trochlear nerve was seen in 9 patients with severe head injury (3 out of 5 patients) are more prone to partial and delayed recovery (more than one year).

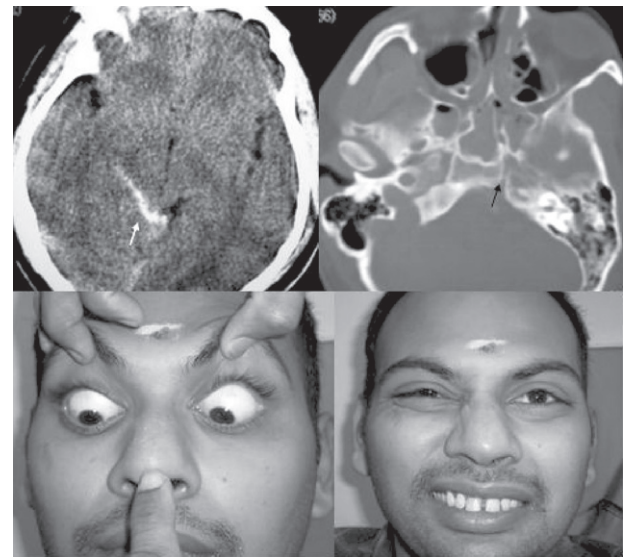


FIGURE 4. Patient with bilateral fourth nerve injury (Rt>Lt) & 6th & 7th nerve injury due to skull base fracture.

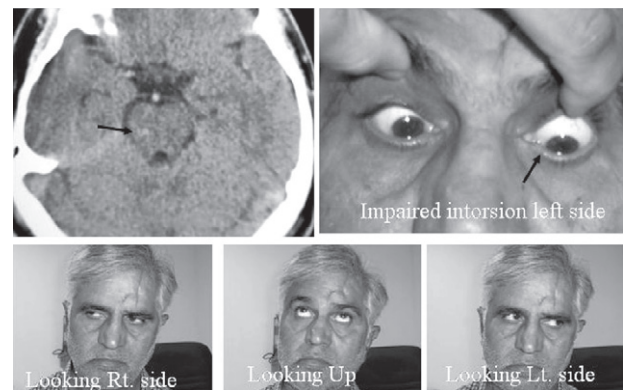


FIGURE 5. Right midbrain contusion causing left Trochlear nerve injury with head tilting to the left side to ignore the second image.

Abducens Nerve Injury

There were 24 patients with sixth cranial nerve palsy with an incidence of 3.02%. Among these, 17 patients had multiple cranial nerve injury. Mild (11 patients) and moderate (8 patients) head injury was more common mode of injury compared to the severe head injury. Skull base fractures (16 patients) involving clivus (4 patients) was the common findings. Out of two patients with bilateral sixth nerve palsy one patient had petrous bone fracture going up to the opposite side via clivus. Other patient with bilateral nerve injury had associated ipsilateral facial nerve palsy with opposite hemiplegia (ventral pontine Millard Gubler's syndrome). All seven patients with only 6th nerve injury showed better improvement (6 out of 7 patients) within 3 to 8 weeks. While patients with multiple cranial nerve injury (11 out of 17 patients) showed delayed (1 month to six months) improvement.

Facial Nerve

Of all the cranial nerves, the facial nerve is most susceptible to injury due to its complex course through the temporal bone with proximity to structures such as the middle ear⁽²⁻⁵⁾. Only nuclear and infranuclear facial nerve were included in the study. Facial nerve injury was seen in 36 patients (4.53%). Sixteen patients had mild head injury, 12 patients had moderate and only 8 patients had severe head injury. In 20 patients only facial nerve was involved, while in the rest, multiple cranial nerve involvement was observed. Early facial palsy (within five days of injury) was seen in 16, while 20 patients showed delayed facial palsy. Temporal bone fractures were found in all 36 cases, (Figs 6,7). High resolution CT of temporal bone was done in patients in whom fracture line was not seen clearly on routine CT scan brain. Five patients with transverse temporal bone fractures had frontal or occipital scalp haematoma, while blows to the lateral head are common in patients with longitudinal fractures. Longitudinal fractures were most common (20 patients), followed by transverse (8 patients) and mixed (8 patients) fractures. Bilateral temporal bone fractures were seen in five patients and bilateral facial paralysis was seen in only one patient. In unconscious patients, gross facial functions were elicited as a grimace in response to painful stimuli. Otoscopic examination of the external auditory canal revealed varied features like a step deformity (2 patients), hemotympanum (14 patients), perforation or bleeding from a lacerated canal wall. Five patients had associated hearing loss. Temporal lobe contusions were present in 14 patients while 20 patients were having multiple skull bone fractures along with temporal bone fracture. Facial nerve injury grading was done according to the most frequently used House-Brackmann scale (grade I-0 pt, grade II-9 pt, grade III-7 pt, grade IV-9 pt, grade V-11 pt, grade VI-0 pt). Since the risk of adverse effects is low and treatment

may decrease the risk of permanent facial paralysis; depending on the neurological condition of the patients, short course of oral steroids in a tapering regimen was given. 19 patients showed near normal facial nerve function (House-Brackmann scale grade I or II) while 17 patients showed partial improvement within one week. Recovery period may vary from one week to several months. In contrast to patients with early facial palsy, patients with delayed onset show better improvement.

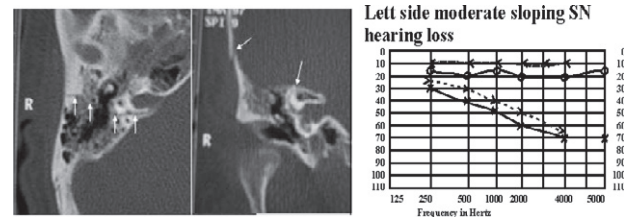


FIGURE 6. Transverse temporal bone fracture extending to IAC causing 7th & 8th nerve injury.

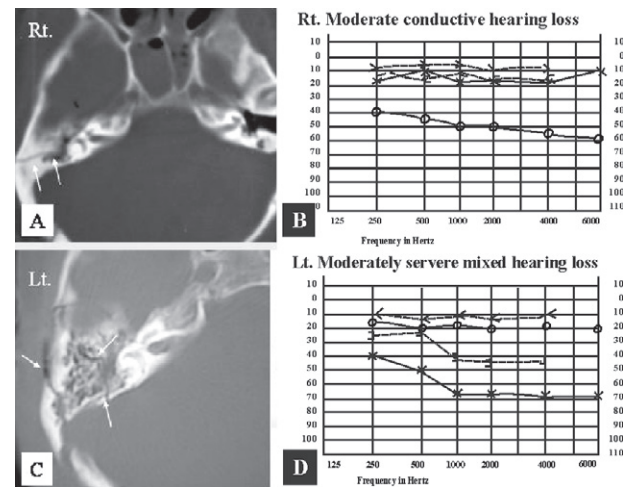


FIGURE 7. Temporal bone Longitudinal (A) fracture causing conducting hearing loss (B) & mixed fracture (C) causing mixed hearing loss (D).

Vestibulo-cochlear Nerve

Out of 12 patients with hearing loss (incidence of 1.51%) five patients had facial nerve involvement also. Four patients had mild, six patients had moderate and one patient had severe head injury. On examination patient may draw attention with complaint of decreased hearing. Temporal bone fractures (longitudinal – 3 pt, transverse – 4 pt, mixed – 6 pt) were present in all cases. High-resolution CT scan of the temporal bones with 1 mm slices and axial & coronal magnified images were done to see ossicular chain dislocation. Five patients developed sensory neural hearing loss, three patients' conductive hearing loss and four patients had mixed hearing loss. Bilateral hearing loss was diagnosed in two patients, out of which patient with bilateral SN hearing loss showed partial improvement. No improvement was seen in-patient with severe bilateral

conductive hearing loss. Overall only five patients showed hearing improvement with recovery period ranging from 6 weeks to several months. Vertigo and nystagmus was more common in-patient with transverse temporal bone fracture and are more refractory to medication. Tympanic membrane perforations and hemotympanum were seen in four patients, which resolved within four to six weeks.

Lower Cranial Nerves Injury

One patient (14 year female) with fractures involving right temporal, left occipital and third cervical vertebra had seven, nine and tenth (immobile left vocal cord) cranial nerve injuries. Ninth and tenth cranial nerves improved within six weeks. Other patients had fracture of posterior lip of foramen magnum leading to ninth and tenth cranial nerve injury which were partially improved at six months duration.

Multiple Cranial Nerve Injuries

Out of 100 patients, 32 patients had post traumatic multiple cranial nerve injuries (Fig-8) with an incidence of 4.03%. Severity of injuries showed no major difference (mild injury-12 pt, moderate injury-10 pt, severe injury-10 pt). Sixth (seventeen patients) and seventh (fifteen patients) cranial nerves were more commonly involved followed by third (eleven patients) second (eleven patients) and fourth (ten patients) cranial nerve. Multiple skull base fractures were present in 21 patients and more common with sixth (13 patients), seven (12 patients) and fourth (6 patients) cranial nerve injuries. All five patients with trigeminal nerve injuries had midfacial fractures and maxillary division (4 patients) was more commonly involved followed by frontal division (1 patient). One patient with fractures involving right temporal, left occipital and third cervical vertebra had seven, nine and tenth (immobile left vocal cord) cranial nerve injuries. Lower cranial nerves (ninth and tenth) improved within six weeks. Two patients with post-traumatic carotid cavernous fistula presented with near complete ophthalmoplegia and blurring of vision. Both patients recovered completely (within one week) after endovascular balloon embolisation.

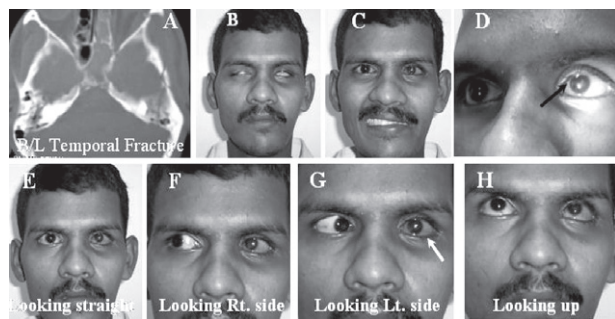


FIGURE 8. Patient with multiple nerve injury-bilateral 7th (B,C), Left optic (D) & Left 6th nerve injury.

DISCUSSION

In case of cranial nerves, biomechanics of the causative injury is related to the outcome^{1,2,6-8}. Cranial nerves are injured before, during or after their passage through the skull. In addition to and following the immediate effect of injury, some of the cranial nerves may be damaged by complications such as the tissue reaction at a fracture site, increased intra cranial pressure or meningitis^{2,6-8}. However, even in an unconscious patient, gross cranial nerve function can be elicited.

In published literature anosmia is the commonest manifestation of cranial nerve injury following trauma. But in our series, olfactory nerve injury is not the commonest. This can be explained by the patient population presenting to our tertiary care institution^{1,2,7}.

The severity of trauma in optic nerve injury is often slight and may even in rare instances be insufficient to cause disturbance in consciousness⁷. Perimetry performed in patients with adequate cooperation revealed no specific visual field loss pattern for traumatic optic neuropathy but it may be used to document visual field disturbance with optic neuropathy. Visual evoked response (VER) may be useful to document nerve conduction and is helpful if the patient is unresponsive^{9,12-14}. Injury to optic chiasma may occur when a fracture line crosses the region of the sella turcica and occasionally it may be torn by severe injury¹⁵.

The pattern of image separation is the key to diagnose which cranial nerve (and extra-ocular muscle) is involved^{2,6-8,11}. Partial third cranial nerve palsy is easier to diagnose in an alert patient. Symptomatic glare in bright light and blurred vision for near objects (paralysis of accommodation) are helpful clinical findings in patients with mild ptosis^{2,8,10,11,16,17}. In patients with partial preservation of parasympathetic pupillary innervation with third cranial nerve injury, the pupil on the involved side may react to light nearly as briskly as the pupil of the other eye. In semiconscious patient with suspected third nerve palsy efforts should be made to arouse the patient at least to the point that there is some effort at eye opening, and ptosis can be apparent^{2,6,11,16}. Unlike olfactory and optic nerve injuries, lesions of the oculomotor nerve usually recovered well in our series.

Fourth cranial nerve palsy is difficult to diagnose in the presence of third cranial nerve palsy because the small increment of depressor deficit (superior oblique muscle) cannot be discerned readily from the depressor palsy that results from weakness of the third nerve-innervated depressor (inferior rectus muscle)^{2,6,11,17}. If intorsion (simultaneously watching landmarks such as conjunctival vessels lateral and medial to the iris) of the globe on

attempted down gaze is absent, one should suspect concomitant fourth cranial nerve palsy.

The commonest injuries to the trigeminal nerve are to its peripheral branches – the supraorbital or the infraorbital nerves. The infraorbital nerve is frequently damaged by the maxillary fractures. The area of numbness usually diminishes without any special treatment¹⁵.

A perforation of the tympanic membrane, bloody and/or clear discharge (CSF) suggests a longitudinal temporal bone fracture and a potential facial nerve injury^{2-5,8}. Extent of paralysis and timing of onset of paralysis may also affect the outcome^{2,3,5}. In a conscious and stable patient, a thorough examination of cranial nerve function including otoscopy and audiometry with speech discrimination is recommended.

Cranial nerve paralysis can result in psychological, functional and social disturbances in the form of impairment of facial expression, impairment of vision, and oral competence. Rehabilitation is an important part of the treatment. CT and MRI findings may help to localize the site of injury.

Diagnostic difficulties

The common diagnostic difficulties that we encounter in our study are

- Perseverance is required to diagnose cranial nerve injury in the presence of severe head trauma.
- Unlike hearing and vision, the sense of smell is difficult to evaluate.
- Coma may obscure all but, third, sixth and seventh cranial nerve damage.
- Fourth nerve injury diagnosis in association with third nerve injury and in unconscious patients.
- In patient with vertical diplopia and orbital trauma it is often impossible to differentiate whether nerve injury or superior oblique muscle injury caused it.
- With auditory canal blockage it is difficult to distinguish between eighth nerve damage or ossicular disruption.

CONCLUSION

The incidence of cranial nerve injury following head injury is significant (12.6% in our series). Meticulous clinical examination, documentation and follow up are essential to detect these injuries. Delayed recovery (up to one year) can occur with olfactory, trochlear and vestibulocochlear nerve injury. Early recognition and treatment may provide

beneficial effects.

REFERENCES

1. PJ Vinken, GW Braun. Injuries of the brain and skull, part two, chapter 2. In: Handbook of Clinical Neurology, 1976; 24 : 27-58.
2. James R Keane, Robert W. Baloh. Posttraumatic cranial neuropathies. *Neurology Clinics*, 1992;10:849-67.
3. Lambart PR, Brackman DE. Facial paralysis in longitudinal temporal bone fractures : a review of 26 cases. *Laryngoscope* 1984, 94 : 1022-6.
4. Ghorayeb BY, Rafie JJ. Fracture of the temporal bone. Evaluation of 123 cases. *J Radiol (Fr)*, 1989;70:703-10.
5. Yanagihara N, Murakami S, Nishihara S. Temporal bone fractures inducing facial nerve paralysis : a new classification and its clinical significance. *Ear Nose Throat J* 1997; 76:64-71.
6. Gennarelli TA, Meaney DF. Mechanisms of Primary head Injury. In, . Wilkins RH, Rengachary SS (eds). *Neurosurgery Vol 2*. McGraw Hill, 1996;2611-22.
7. Russel WR. Injury to cranial nerves and optic chiasm. In Brock S, Cassel (ed): *Injuries of the brain and spinal cord*. 1960:118-26.
8. Kalyanaraman S, Ramamurthi B. Analysis of 2000 cases of head injury. *Neurol Ind* 1970 : 18.
9. Ashar A, Kovacs A, Khan S, Hakim J. Blindness associated with midfacial fractures. *J Oral Maxillofac Surg.* 1998;56(10):1146-50.
10. Elisevich KV, Ford RM, Anderson DP, Streford JG, Richardson PM. Visual abnormalities with multiple trauma. *Surg Neurol* 1984;22:565-75.
11. Lepore FE. Disorders of ocular motility following head trauma. *Arch Neurol* 1995;52(9):924-6.
12. Mahapatra AK, Bhatia R. Predictive value of visual evoked potential in unilateral optic nerve injury. *Surg Neurol* 1989;31:339-42.
13. Mahapatra AK, Tandon DA. Optic nerve injury. A prospective study of 250 patients. In : M Samii (Eds). *Skull base: Anatomy, Radiology and Treatment*. S. Harger, Basel 1994;pp:305-9.
14. Mahapatra AK. Current management of optic nerve injury. In Venkataraman S & Misra BK (eds). *Progress in Clinical Neurosciences*. Mediworld Publishing. Delhi 1997;12:241-54.
15. Lewin W : Injuries to cranial nerves and visual pathways. In, Lewin W, Bailliere, Tindall and Cassell (eds). *The management of Head injuries* 1996:137-46.
16. Bhutani AK, Singh AK, Prakash B. Post traumatic brainstem haematoma. *Neurol Ind (suppl)* 1993;41:43-4.
17. Gonzalez E. Post traumatic third nerve paralysis. *Arch Neurobiol.* 1984;47:213-8.