

Management Dilemmas in Delayed Presentation of Traumatic Atlanto-occipital Dislocations

AR Maqsood Ahmed M Ch, DI Bhat M Ch, B Indira Devi M Ch, and BA Chandramouli M Ch

Department of Neurosurgery
National Institute of Mental Health and Neurosciences, Bangalore-29.

INTRODUCTION

Traumatic atlanto occipital dislocation (AOD) was till recently believed to be a universally fatal injury. However of late there have been increasing number of reports of patients surviving traumatic AODs. This may perhaps be due to better pre-hospital management and better transportation facilities¹. There are however very few reports of patients who have delayed presentations after having suffered a traumatic AOD². We present three patients, all of whom sustained radiographically documented AOD, following significant trauma. Interval between trauma and presentation ranged from weeks to years and they presented in a relatively preserved neurological state in contrast to the grave nature of the injury.

CASE REPORTS

Case 1

A 55-year-old man presented with a history of fall from a height of 10 feet, 3 weeks prior to admission. He had fallen face down and sustained injuries to the forehead. Following this he had pain in the neck aggravated by movements and associated with restricted neck movements. He also had difficulty in swallowing, nasal regurgitation of liquids with a nasal twang to his voice following the trauma. On examination he had tenderness over the C2 region with restricted neck movements. His speech had a nasal twang with dysarthria to lingual consonants. He had involvement of right 9th, 10th and 12th cranial nerves. Motor and sensory systems were normal.

Skull X-ray and Head CT were normal. X-ray of the CV junction showed dens lying anterior to the clivus suggestive of a type 3 atlanto-occipital dislocation. The clival-dental distance was 10 mm and the Powers ratio was 0.7 (less than normal, indicating posterior dislocation). CT of the craniovertebral junction showed fracture of the posterior arch of C1 and right occipital condyle, and a type 3 Atlanto occipital dislocation.

Corresponding Author: B. Indira Devi, Additional Professor, Dept. of Neurosurgery, NIMHANS, Bangalore-29
Email: bindira@nimhans.kar.ic.in, Ph: 080-26995409, 080-26995079.

Suboccipital region, posterior arch of atlas and lamina of axis were exposed by midline incision. C1 arch was observed to be thick and fractured, and both- C1 and C2 were displaced anteriorly. He underwent excision of the C1 arch, and occipito -C2 fusion with contoured rod and sublaminar wires.

At follow up 5 months post surgery he had improved in speech and swallowing difficulty and had minimal hypoglossal palsy.

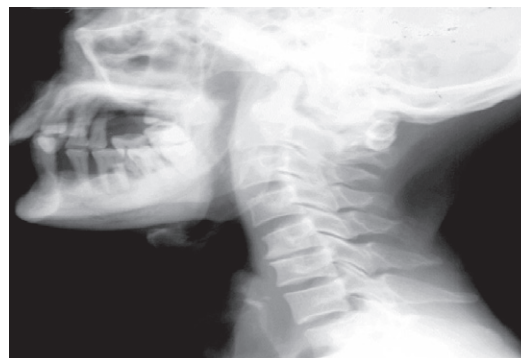


FIGURE 1. X rays of the CV junction of case 1 showing dens lying anterior to the clivus suggestive of a type 3 atlanto occipital dislocation.

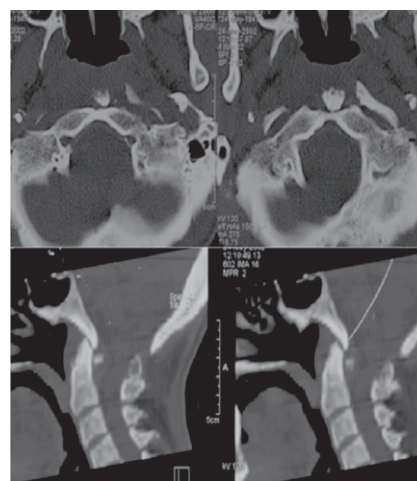


FIGURE 2. CT of the CV-Junction of case 1 showing fracture of the posterior arch of C1 with right occipital condyle fracture, and a type 3 Atlanto occipital dislocation.

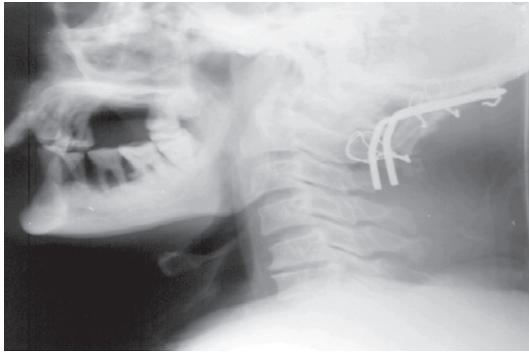


FIGURE 3. Post op X-Rays of case 1 showing good positioning of the implant.

Case 2

A 43-year-old man had sustained injury to the neck due to near-drowning at sea at the age of 15 years. He had developed left sided weakness following this but was able to do his activities of daily life without assistance, till 6 months prior to admission, when he developed worsening of his weakness and had difficulty in walking. He had also developed neck pain without radiation.

On examination he had left sided hemiparesis (power 4/5) with exaggerated deep tendon reflexes, and bilateral extensor plantars. There was no cranial nerve involvement or any significant sensory loss.

X rays of the craniovertebral junction showed type 2 atlanto-occipital dislocation with an occipital-atlantal joint distance of more than 5mm. CT and MRI of craniovertebral junction showed severe cord compression at the foramen magnum level. Anterior compression was bony probably due to bony fusion between the C1 arch and the clivus. Patient was planned for a transoral anterior decompression followed by a posterior fusion. However, since patient was relatively well preserved neurologically, he wanted to decline surgery and thereafter was lost to follow up.

Case 3

An eighty-year-old man presented with a history of fall from a height of 20 feet 5 years prior to presentation. He developed right side weakness following the fall, which improved over a period of one month. A month prior to presentation he had developed restriction of neck movements with right-sided weakness and numbness. He also had chronic obstructive pulmonary disease for which he was on steroids for the nearly four years. On examination he had Cushingoid appearance with easy bruisability. Neurologically, tone was increased in all the limbs, with right-sided weakness (motor power grade 3/5). There was bilateral graded sensory loss of about 75% below C2

dermatome. All deep tendon reflexes were exaggerated. X-ray and CT craniovertebral junction revealed, atlanto-occipital dislocation with dens fracture and anterior translation. Chest X-Ray revealed emphysematous chest. Craniovertebral junction was immobilized in a Philadelphia collar and patient was planned for a Occipito-axial fusion. However, in view of high anesthesia risk due to chronic obstructive airway disease, and his advancing age, patient decided against undergoing surgery and was discharged with advice to wear the cervical orthosis.

DISCUSSION

Traumatic AOD is often a fatal injury. Its exact incidence is unknown as most of the patients die before reaching the hospital^{3,4}. Bucholz and Burkhead⁵ in a post-mortem study reported an incidence of 8% among the 112 victims of multiple trauma, Alker et al⁶ in their post mortem radiographic examination of 312 victims of fatal traffic accidents reported 19 patients with traumatic AOD. The three survivors of traumatic AOD represented 3.1% of all cervical spine injuries in a report by Sakchai et al⁴. The past two decades have seen an increasing number of reports of patients who have survived traumatic AOD^{3,4,7,8,9,10,11,12,13,14}. There are however very few reports of patients who have chronic AOD following trauma². All the three patients in our group presented after varying periods ranging weeks to years after trauma, the longest interval being 18 years.

The mode of injury in most of the reported cases has been traffic accidents between pedestrian and a fast moving vehicle. In our series two patients sustained injury after falling from a height while one sustained AOD when he fell into sea. There has been a controversy about the mechanism of injury at the atlanto-occipital level. Hyperflexion is suggested as the underlying mechanism⁶. Werne¹⁵ in his series of cadaveric dissections concluded that the structure that is responsible for checking the hyper extension and vertical translation of the occiput on the spine was the tectorial membrane, a view supported by Sun et al¹⁶. In view of the high frequency of mandibular fractures and submental lacerations seen in these injuries, Bucholz⁵ felt hyperextension injury is more consistent and plausible mechanism. Hyperextension with tectorial membrane damage and extreme lateral flexion with damage to the alar ligaments is the most commonly accepted mechanism of injury^{9,14}. In our series, first patient who sustained a fall on his forehead and who also had associated posterior C1 arch fracture and right occipital condylar fracture probably had a combined hyperextension and lateral flexion injury as posterior C1 arch fractures are known to be caused due to hyper extension and the mechanism of condylar fractures is lateral flexion with alar ligament tear¹⁷.

Patients with AOD may exhibit a wide spectrum of neurologic involvement ranging from severe deficits with ventilatory insufficiency and instantaneous death to no deficits. Cranial nerve deficits especially 6th nerve palsy and lower cranial nerve deficits are known to occur^{4,7,9,12,14}. Second and third patient in our series had hemiparesis and the first patient had lower cranial nerve palsy.

Diagnosis is based on high index of suspicion in patients of multiple trauma and respiratory arrest⁴. Radiological diagnosis is usually evident with lateral cervical spine X-rays.

Traynelis et al¹⁸ classified AOD in three types: type 1 (anterior), type 2 (longitudinal) and type 3 (posterior) based upon the relationship of the occiput and the atlas (Fig 5). Review articles by Ozgur⁸ and Mathew⁹ have detailed craniometric dimensions to diagnose AOD. Commonly used ones are (Fig 4) :

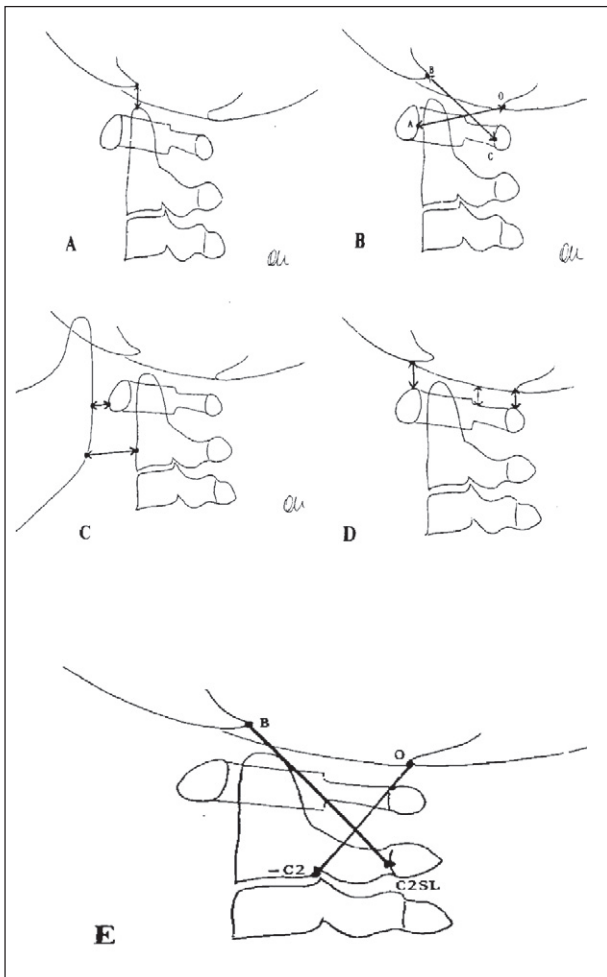


FIGURE 4. Various radiological methods used to diagnose AOD: A)Wholey, B)Power's ratio, C)Dublin, D)Kaufmann, and E)Lee's X-lines.

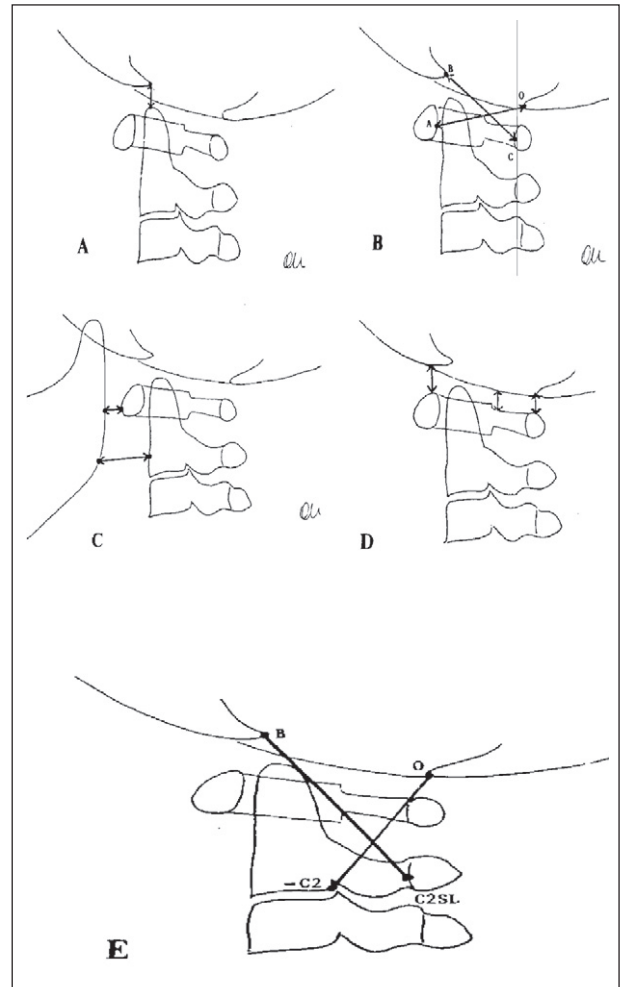


FIGURE 5. Traynelis Classification of AOD: B)type 1, C)type 2, D)type 3.

- A) Wholey's:** Distance between the tip of the dens and the overlying basion is normally less than 5mm in adults and anything more than this is abnormal.
- B) Powers Ratio:** Ratio of distance between the lines joining the basion and the posterior arch of the atlas and the opisthion and the anterior arch of atlas is normally 0.77, any value greater than 1 is considered indicative of type 1 AOD. This measurement is independent of radiographic magnification. However, the Powers ratio has limitations in presence of C1 fractures, congenital foramen magnum anomalies and in type 2 AODs.
- C) Dublin:** distance between the anterior arch of the atlas and the posterior aspect of the mandible, and from the anterior dens to the posterior mandible maintains a constant range for neutral, flexion and extension postures of the cervical spine and in AOD the values

exceed the normal range. This measurement can be affected by radiographic posturing and fractures of the mandible.

- D) **Kaufman:** Width of the atlanto-occipital joint should not exceed 5mm: anything more is suggestive of type 2 AOD. Difficulty in interpreting due to superimposition of the mastoid tips and false positives limit its usefulness.
- E) **Lee's X lines:** First line ('BC2SL') is between tip of the basion and midpoint of the spinolaminar line of C2, second line ('C20') is between posteroinferior corner of body of C2 and the tip of the dens. Normally BC2SL and C20 should just intersect tangentially with the postero-superior aspect of the dens and the highest point on the atlas spinolaminar line respectively; any deviation suggests AOD. Advantage of Lee's lines is that no calculations are necessary but hyperextension can cause problems.

Of all these measurements, the Powers ratio is the most widely used. A combination of these methods was used to diagnose our patients as mentioned previously.

Retropharyngeal hematoma is usually an associated radiographic finding in these patients and should arouse suspicion in doubtful cases^{13,19}.

CT scan of the craniovertebral junction axial, sagittal and 3D reconstruction in selected patients will be useful in confirming the diagnosis especially when there is doubt on plain radiographs^{19,20}. Other investigations useful in the evaluation are MRI of the craniovertebral junction and vertebral angiography. MRI demonstrates soft tissue injuries and spinal cord damage better¹⁹. Low field MRI with its compatibility for resuscitation instruments and ease of access of medical personal to the patient was very useful in a study by Papadopoulos³ wherein they not only detected radiographically occult AOD but a spinal epidural hematoma as well, which was evacuated surgically. The non-availability of MRI in most of the situations, the space restraints and the long time for investigation are definite drawbacks.

Vertebral angiography can pick up brainstem injury due to vascular injury^{19,21}, and is particularly of value in these patients who have neurological worsening and/or clinical findings that cannot be explained on the basis of the diagnosed anatomical abnormality¹⁹.

Treatment of traumatic AOD consists of early ventilatory support, spinal immobilisation, and closed reduction if possible under fluoroscopy⁷, and subsequent posterior

surgical fusion^{3,4,8,19}. Use of cervical traction is controversial. Its use is indicated only in type 1 and type 3 AODs, where it may help to realign the bony structures and decompress the cord⁸. In type 2 however since there is already distraction at the atlanto-occipital region further traction may worsen the patient and cause cervicomedullary stretch^{3,8,18,19,22}.

Since this injury is usually ligamentous it is not likely to heal with external immobilization^{9,14} and halo vest stabilization is itself not sufficient^{3,8,14,17}. Hence, most of the patients will require a (posterior) occipito-cervical fusion. Various types of fusion devices and techniques have been described, though occasionally only halo immobilization has caused bony fusion¹³. Usually fusion is accomplished by wiring the C1 to the occipital condyles with the addition of a bone graft^{8,23}. Steinman pin is an alternative of achieving this fusion but will cause more restriction of neck movements⁸. Houle et al¹⁴ have described the use of the Locksey device for the same purpose and they felt that it provided immediate stability and did not require any external orthoses. Mathew et al⁹ felt that posterior fusion with only autologous cancellous bone graft was sufficient to cause osseous consolidation and that lack of any metallic construct would allow unhindered post operative CT evaluation with out any artifacts.

Though anterior approach for spinal decompression and fusion was felt to increase the instability⁷ it has been described combined with posterior fusion by Masakazu et al² and this had helped in decompressing the anterior medullary compression that occurs due to fibrosis between occipital condyles and C1 superior facets in an old injury. One patient in our series underwent surgery by a posterior approach, using sublaminar wires and contoured rod made out of Steinman pins. We had planned to use both anterior transoral decompression and posterior fusion for our second patient as he had significant anterior compression but due to reasons mentioned he was not operated.

Table 1: Summary of the three patients

Patient	Mode of Injury	Neurological Deficit	Radioimaging	Treatment
1.	Fall From Height	1.restricted Neck MOVt 2. Lower Cranial Nerve Palsy	Type 3 AOD	Posterior Fusion
2.	Near drowning	1. Neck pain 2. Hemiparesis	Type 2 AOD	Lost to follow up
3.	Fall From Height	1.restricted Neck Movt 2. Hemiparesis	AOD With Dens Fracture	Conservative

CONCLUSION

- Survivors after traumatic atlanto-occipital dislocation are increasingly being reported, probably due to improved pre hospital care and better patient transportation.
- Though rare, patients can present late after having suffered and survived traumatic atlanto-occipital dislocations.
- Diagnosis requires a high index of suspicion and any patient with respiratory involvement after trauma or having features of high cervical cord compression must be evaluated.
- Patients who present in good neurological grade will have a better outcome after posterior stabilization.

REFERENCES

1. Traynelis Vincent C., Kaufman Howard H.. Atlanto-Occipital Dislocation. In: Wilkins RH, Rengachary SS (eds). Neurosurgery. NewYork: McGraw-Hill, 1996; 2871-2874.
2. Masakazu Takayasu , Masahito Hara , Yoshio Suzuki , Jun Yoshida. Treatment of traumatic atlanto-occipital dislocation in chronic phase. *Neurosurg Rev* 1999; 22 : 135-7.
3. Papadoulus SM. , Dickman CA. , Sonntag VKH. , Rekate Harold L, Spetzler RF. Traumatic atlanto-occipital dislocation with survival. *Neurosurgery* 1991; 28 : 574-9.
4. Sakchai Saeheng , Nakornchai Pheunpathom. Traumatic Atlanto-occipital Dislocation. *Surg Neurol* 2001; 55:35-40.
5. Bucholz Robert W., Burkhead Wayne Z.. The Pathological Anatomy of Fatal Atlanto-Occipital Dislocations. *J Bone Jt Surg* (Supplement)1979; 61A: 248-250.
6. Alker George J., Oh Young S., Leslie Eugene V., Lehotay Judith, Panaro Victor A., Eschner Edward G. Postmortem Radiology of Head and Neck Injuries in Fatal Traffic Accidents. *Radiology* 1975; 114 : 611-7.
7. Hosono Noboro, Yonenobu Kazuo, Kawagoe Kazuyoshi, Hirayama Naoki, Ono Keiro. Traumatic atlanto-occipital dislocation. *Spine* 1993; 18:786-90.
8. Harmanli Ozgur, Koyfman Yakov. Traumatic atlanto-occipital dislocation with survival: a case report and review of the literature. *Surg Neurol* 1993; 39: 324-30.
9. Mathew J.Matava, Thomas E.Whitesides, Patricia C.Davis. Traumatic atlanto-occipital dislocation with survival. Serial computerised tomography as an aid to diagnosis and reduction: A report of three cases. *Spine* 1993; 18: 1897-903.
10. Dublin Arthur B, Marks William M, Weinstock David, Newton Thomas H. Traumatic dislocation of the atlanto-occipital articulation(AOA) with short-term survival. With a radiographic method of measuring the AOA. *J.Neurosurg* 1980; 52: 541-6.
11. Dibenedetto Thomas, Lee Casey K.. Traumatic atlanto-occipital instability. A case report with follow-up and a new diagnostic technique. *Spine* 1990; 15:595-7.
12. Anton H.Van Den Bout, Dommissie George F. Traumatic atlanto-occipital dislocation. *Spine* 1986; 11: 174-6.
13. Jevtich V. Traumatic lateral atlanto-occipital dislocation with spontaneous bony fusion. A case report. *Spine* 1989; 14:123-4.
14. Houle Paul, McDonnell Dennis E, Vender John. Traumatic atlanto-occipital dislocation in children. *Pediatr Neurosurg* 2001; 34: 193-7.
15. Werne S. Studies in spontaneous atlas dislocation. *Acta Orthop Scand* (Suppl) 1957;23:1-150.
16. Sun Peter P, Poffenbarger Glen G, Durham Susan, and Zimmerman Robert A. Spectrum of occipitoatlantoaxial injury in young children. *J Neurosurg* 2000; 93: 28-39.
17. Levine Alan M, Edwards Charles C. Traumatic Lesions of the occipitoatlantoaxial complex. *Clin Orthop* 1989;239: 53-68.
18. Traynelis VC, Marano GD, Dunker RO, Kaufman HH. Traumatic atlantooccipital dislocation. Case report. *J Neurosurg* 1986; 65: 863-70.
19. Ahuja Arvind, Glasauer Franz E., Alker Geroge J, Klein David M.. Radiology in survivors of traumatic atlanto-occipital dislocation. *Surg Neurol* 1994; 41:112-8.
20. Gerlock AJ Jr, Mirfakhraee M, Benzel EC. Computed tomography of traumatic atlanto-occipital dislocation. *Neurosurgery* 1983;13:316-9.
21. Lee C, Woodring JH, Walsh JW, Carotid and Vertebral artery in survivors of atlanto-occipital dislocation: Case report and review of literature. *J Trauma* 1991;31:401-7.
22. Pang D, Wilberger JE Jr, Traumatic atlanto-occipital dislocation with survival: Case report and review. *Neurosurgery* 1980;7:503-8.
23. Ewerts CM. Traumatic occipito-atlantal dislocation.Report of a case with survival. *J Bone Jt Surg* 1970;52A:1653-60.