

# Spontaneous Rapid Resolution of Traumatic Subarachnoid Hemorrhage

Ajay Kurve M Ch, A K Mahapatra M Ch

Department of Neurosurgery  
All India Institute of Medical Sciences, Ansari Nagar, New Delhi 110029

**Abstract:** We report a 32-year-old male with severe head injury in whom traumatic subarachnoid hemorrhage resolved spontaneously. On admission, Glasgow Coma Score was 6/15 and CT scan revealed grade III subarachnoid hemorrhage with evidence of diffuse axonal injury and small hemorrhagic contusion in left temporal lobe. Patient improved with conservative management, and serial CT 24 hours later showed complete resolution of subarachnoid hemorrhage.

**Keywords:** diffuse axonal injury, head injury, subarachnoid hemorrhage

## INTRODUCTION

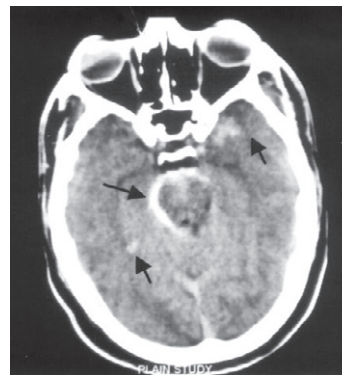
Traumatic subarachnoid hemorrhage (TSAH) was first described by Wilkins in 1859<sup>1</sup>. In an autopsy study of patients dying from head injury, he noticed hemorrhagic CSF which he described as 'sanguinous meningeal effusion in subarachnoid space'. The exact incidence of TSAH is not certain. In a CT analysis, Eisenberg et al<sup>2</sup> reported 39% incidence of TSAH in 753 patients. In a similar study, Chestnut et al reported 44% incidence of TSAH<sup>3</sup>. Clearance of TSAH depends upon the amount of blood seen in initial scan. In TSAH, clearance of blood is faster than that described in aneurysmal SAH<sup>4</sup>. Rapid resolution of traumatic intracranial bleed i.e. extradural haematoma (EDH), subdural haematoma (SDH) and intracranial haematoma (ICH) have been well described in literature. However resolution of TSAH with parallel dramatic improvement in the neurological status of the patient is rare and not frequently reported.

## CASE REPORT

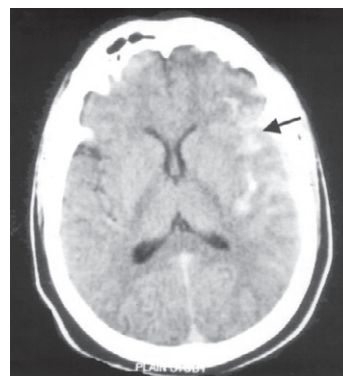
A 32-year-old male, was admitted to casualty with the history of road traffic accident. On admission, Glasgow coma score (GCS) was E<sub>1</sub>V<sub>1</sub>M<sub>4</sub> (6/15), with no limb weakness. Patient was immediately intubated in the casualty. CT scan of head was carried out after stabilizing the patient. CT revealed diffuse subarachnoid haemorrhage (SAH) i.e. in basal cisterns, left sylvian fissure and in frontal cortical sulci with multiple dot contusions (DAI) in both the cerebral hemispheres and small hemorrhagic contusion near the temporal pole (Figs 1a and b). Patient did not have any other injury. He was managed conservatively by elective ventilation, osmotic diuresis (mannitol) and

*Address for correspondence:* Dr AK Mahapatra M Ch, Department of Neurosurgery, All India Institute of Medical Sciences, Ansari Nagar, New Delhi -110029

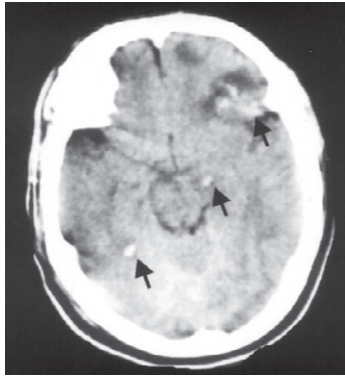
intravenous phenytoin. There was significant clinical improvement, and serial CT head 24 hrs post injury revealed complete resolution of the TSAH while dot contusions and the other mentioned haemorrhagic contusion persisted (Figs 2a and b). Patient was weaned off the ventilatory support and extubated, and when discharged three days later was fully conscious with no neurological deficit.



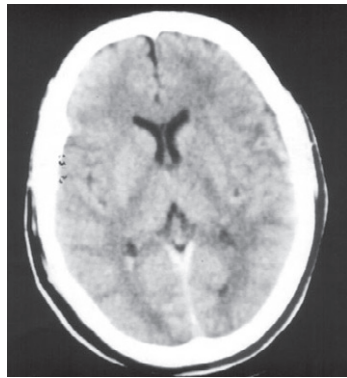
**FIGURE 1a.** CT showing subarachnoid haemorrhage in basal cisterns with DAI with temporal pole contusion.



**FIGURE 1b.** CT showing subarachnoid haemorrhage in frontal cortical sulci



**FIGURE 2a.** CT showing resolution of subarachnoid haemorrhage in basal cisterns with persistence of DAI and haemorrhagic contusion



**FIGURE 2b.** CT showing resolution of subarachnoid haemorrhage in frontal.

## DISCUSSION

First described by Wilkins in 1859<sup>1</sup>, TSAH was thought to be caused by rupture of the intracranial arteries and bridging veins<sup>5,6</sup>. Newbarr and Courville<sup>7</sup> hypothesized tearing of superior cerebral veins at their entry point in superior sagittal sinus. There is probable rupture of fine vessels of pia-arachnoid during shearing strains under the dura. Freytag in 1963 reported SAH in head injured patients due to venous rupture<sup>8</sup>. Thin walled veins are more liable to rupture than rupture of thick walled arteries.

TSAH is one of the important factor influencing the overall outcome in head injured patients<sup>2</sup>. The mortality is 2-3 times higher in patients with TSAH than those without SAH in CT scan. Eisenberg et al<sup>2</sup> in 1990 reported mortality among TSAH patients twice as high as no SAH patients. In patients with TSAH, unfavourable outcome is reported in 60-70% cases. TSAH patients with mild head injury showed higher incidence of unfavourable outcome than mild head injury without SAH<sup>9,11</sup>. The outcome of patient with TSAH is directly related to clinical state and amount of subarachnoid blood seen on the first CT scan<sup>12</sup>.

Clearance of TSAH depends on the amount of blood seen in initial scan. In TSAH, clearance blood is faster than that described in aneurysmal SAH<sup>4</sup>. Rapid clearance of blood in patients of TSAH is reported by Kakarieka in 1996<sup>13</sup>. In his study he noticed reduction of subarachnoid blood to 50% after 2 days of initial CT and 33% after 3 days of initial CT scan. Here we report rapid resolution of TSAH within 24 hrs with parallel rapid neurological improvement. Such rapid resolution of traumatic bleed is described in relation with intracranial hematomas, subdural hematomas and intradural hematomas but not with TSAH. Wu Me et al<sup>14</sup> described a patient with rapid resolution of intracerebral hematoma within 72 hours. Berker et al<sup>15</sup> reported ultra-rapid spontaneous resolution of acute post-traumatic SDH within two hours of its occurrence. Imai<sup>16</sup> had reported rapid spontaneous resolution of signs of intracranial herniation in a 57 year old patient in who acute subdural haematoma got resolved. Similarly Edward et al<sup>17</sup>, Fernandez et al<sup>18</sup>, Kato et al<sup>19</sup>, Cohen JC et al<sup>20</sup> also reported rapid spontaneous resolution of acute SDH. Kurowia et al<sup>21</sup> have described rapid spontaneous resolution of acute extradural and subdural haematoma in 17 years old man.

## CONCLUSION

TSAH is an unusual finding in CT after head injury. Rapid resolution of TSAH is a phenomenon observed rarely, and the treating surgeon should be aware of such a possibility to prognosticate the outcome.

## REFERENCES

1. Wilkins S. Sanguineous meningeal effusion. *Guy Hosp Rep* 1859;5:119-27.
2. Eisenberg HM, Garg HE, Aldrich EF et al. Initial CT findings in 753 patients with severe head injury. A report from NIH traumatic coma data base. *J Neurosurg* 1990; 73 : 688-98.
3. Chestnut RM, Luerssen TG et al. Post traumatic ventricular enlargement in traumatic coma data bank : Incidence, risk factor and influence in outcome. In : Avezaat CJJ Van Eijndover, Mass AIR, Tans JTJ (Eds). Proceedings of 8<sup>th</sup> International Symposium on Intracranial Pressure. Springer Berlin Heidelberg, New York 1993; pp:503-506.
4. VanGijn J, Van Dougen KJ. The time course of aneurysmal haemorrhage on computed tomograms. *Neuroradiology* 1982;23:153-6.
5. Dowling CT, Curry B. Traumatic basal subarachnoid haemorrhage. Report of 6 cases and review of the literature. *Am J Forensic Med Pathol* 1988;9:23-31.
6. Nakamura N, Taunoda M et al. Post traumatic progressive non-obstructive hydrocephalus, report of two cases. *No To Shinkei* 1971;23:1217-21.
7. Newbarr FD, Courville CB. Trauma as the possible, significant factor in rupture of congenital intracranial aneurysms. *J Forensic Spinal Cord injury* 1958 ; 31:174-99.

8. Freytag E. Autopsy findings in head injuries from blunt forces. Statistical evaluation of 1367 cases. *Arch Pathol* 1963;75:402-13.
9. Rimel RW, Giordani B et al. Moderate head injury : Completing the clinical spectrum of head trauma. *Neurosurgery* 1982; 11: 344-51.
10. Dacey RG, Alves Wa et al. Neurosurgical complications after apparently minor head injury. *J Neurosurg* 1956; 65 : 203-10.
11. Williams DH, Levin MS et al. Mild head injury classification. *Neurosurgery* 1990; 27 : 230-6.
12. Mahapatra AK, Rajkumar. Traumatic subarachnoid haemorrhage. In: Mahapatra AK, Rajkumar (Eds). A text book of head injury. Modern Publishers, New Delhi 1999; pp : 230-6.
13. Kakarieka A. Analysis of CT findings in SAH. In : Traumatic subarachnoid haemorrhage. A Kakarieka (ed), Springes Verlag Berlin Heidelberg 1997; pp : 21-34.
14. Wu MC, Liu JX et al. Rapid natural resolution of intracranial haematoma. *Clin J Traumatol* 2004; 7 : 96-100.
15. Berker M, Gulsen S, Ozean OE. Ultrarapid spontaneous resolution of acute post-traumatic subdural haematomas in patient with temporal linear fracture. *Acta Neurochir (Wien)* 2003; 145 : 715-7.
16. Imai K. Rapid spontaneous resolution of signs of intracranial herniation due to subdural haematoma – case report. *Neurol Med Chir (Tokyo)* 2003; 43 : 126-9.
17. Edward RJ, Britz GW et al. Spontaneous resolution of acute subdural haematoma. *Br J Neurosurg* 2002; 16 : 609-10.
18. Fernandez-Portales I, Gomez-Perals L et al. Rapid spontaneous resolution of acute subdural haematoma. *Neurocirugia* 2002; 13 : 491-4.
19. Kato N, Tsunodo T et al. Rapid spontaneous resolution of acute subdural haematoma occurs by redistribution – two case reports. *Neurol Med Chir (Tokyo)* 2001; 41 : 140-3.
20. Cohen JC, Eger K et al. Spontaneous resolution of acute subdural haematoma and HIV related cerebral atrophy : Case report. *Surg Neurol* 1998; 50 : 241-4.
21. Kuroiwa T, Tanabe H et al. Rapid spontaneous resolution of acute extradural and subdural haematomas. Case report. *J Neurosurg* 1993; 78 : 126 – 8.