

## Growing Skull Fracture Following Monkey Bite

**Amaresh Deginal** DNB (Neurosurgery), **Naveen Rao M Ch\***  
**K. Balasubramanyam M D\*\***, **Siddaling Changty M D\*\***  
Departments of Neurosurgery, Plastic Surgery\* & Pediatrics\*\*,  
Rajiv Gandhi Superspeciality Hospital, Raichur - 584102, Karnataka.

**Abstract:** Most of the skull fractures in childhood heal without sequelae. Rarely, however the fracture site starts widening with time and appears to be growing, and is thus called growing skull fracture. Its late complication is called leptomeningeal cyst, which is practically cerebromeningeal cicatrix with loculated CSF. All most all reported cases are due to head trauma resulting from road traffic accidents or fall. Here we report a case of leptomeningeal cyst occurring one year after having been bitten by a monkey over the site.

**Keywords:** dural tear, growing skull fracture, leptomeningeal cyst, monkey bite, skull fracture.

### INTRODUCTION

Although skull fractures are seen commonly in pediatric age group, the incidence of growing skull fracture is rare, occurring in only 0.05 to 1 percent among skull fractures in childhood. These are more common in the parietal region, and are characterized by progressive diastatic enlargement of fracture line. Dural tear is a pre-requisite for growing skull fracture. Since the cranium is thin in young children (less than eight years' age), therefore they are more prone to developing growing skull fracture in the presence of dural tear.

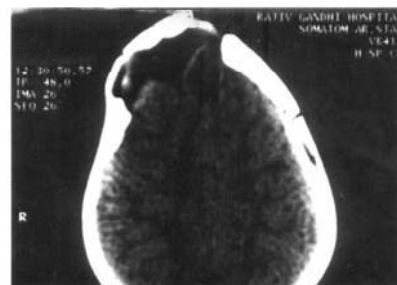### CASE REPORT

A three-year-old female child was brought with one-year-history of slowly enlarging swelling over her left frontal region. There was history of adult monkey bite at the same site two years earlier, when child was kept under a tree as mother did work in the field. A large scalp laceration was sutured by a local doctor, and X-ray skull showed linear fracture. Wound healed uneventfully, and the child subsequently showed normal growth according to age. Later however, her mother noticed gradual swelling at the bitten site, which gradually increased to its present size. On examination, child was fully conscious & neurologically stable. A huge cystic swelling (9 cm x 6 cm) over right frontal region with central healed scar was seen. There

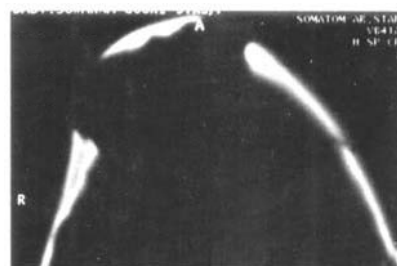
were no signs of inflammation and everted bony edges were felt at the cyst margin.

X-rays skull, (AP & lateral views) confirmed huge gap in skull with thickened bone at the edges. A large, free piece of bone was seen lifted up at the centre.

CT Brain (Fig 1) Showed leptomeningeal cyst with thick & everted bony margins. Contents of the cyst were CSF and cerebro-meningeal cicatrix. A piece of bone was seen at the centre of cyst, which was probably a free bone fragment detached at the time of monkey bite (Fig 2).



**FIGURE 1 :** CT showing leptomeningeal cyst with loculated CSF, Cerebromeningeal cicatrix



**FIGURE 2 :** CT showing thick and everted bony margins and a big piece of elevated bone at the centre

*Address for correspondence :* Dr. Amaresh Deginal, Consultant Neurosurgeon, Rajiv Gandhi Superspeciality Hospital, Raichur – 584102 Karnataka, India.  
Phone : 08532-236202 to 05, Ext : 1295, Cell: (0) 9448690223  
Email : deginal\_70@yahoo.co.in, dramaresh\_deg@rediffmail.com

The child underwent exploration, excision of the cicatrix and sequestrum, duroplasty and cranioplasty using autologous rib. No perioperative or postoperative problems were encountered, and cosmetic result was good.

### DISCUSSION

During infancy brain volume increases rapidly, and this increase is the predominant factor in causation of growing skull fracture is dural laceration. The pulsatile force of brain during its growth causes the fracture in thin, growing skull to enlarge. This interposition of tissue prevents osteoblasts from migrating to fracture site, inhibiting healing. Resorption of adjacent bone by continuous pressure from tissue herniation through the bone gap adds to the progression of fracture line. Cranial defect never increase in size if the underlying dura is intact, and craniotomies performed in the past without water-tight closure of dural lacerations have to lead to growing skull fracture<sup>1,2</sup>. Post-traumatic fractures of skull routinely seen in neurosurgical practice but growing skull fractures are unusual. Growing skull fracture following to animal bite (monkey bite) has not been reported so far. Dural tear is a prerequisite for growing skull fracture in children less than eight years of age, and such a fracture is almost never seen after eight years of age<sup>3</sup>. The recommended early surgical correction is by closure of dura and cranioplasty. However attempts to control the growing skull fractures by repeated lumbar punctures or punctures of the leptomeningeal cyst have failed<sup>4</sup>. Ramamurthi & Kalyanaraman have reported four patients whose growing

skull fractures under went spontaneous stabilization without surgical correction<sup>5</sup>. Transient progression and subsequent spontaneous healing of neonatal diastatic fractures has also seen reported<sup>5</sup>. Main aim of surgical management is to prevent sequelae like cerebro-meningeal cicatrix, neurological deterioration and seizure disorder. Growing skull fracture following animal bite has not been reported earlier.

### CONCLUSION

Growing skull fracture can occur following animal bites on the head in small children who are vulnerable to attacks by small domesticated or undomesticated animals in the urban setting.

### REFERENCES :

1. Sacro GB, Mariottini A, Thomaccini D, Palma L. Growing skull fractures : progressive evolution of brain damage and effectiveness of surgical treatment. *Childs Nerv Sys* 1989; 5:163 – 7.
2. Iyer Shivaram Gopal, Saxena Puneet, Ghanshyam Kumar. Growing skull fractures. *Ind Ped* 2003 ; 40 : 1194 – 6.
3. Tomita T. Growing skull fractures of childhood. In, Wilkins RH, Rengachary SS (eds). *Neurosurgery* Vol II. McGraw-Hill, Philadelphia, 1996: p 2757 – 61.
4. Thompson JB, Mason TH, Haines GL, Cassidy RJ. Surgical management of diastatic linear fractures in infants. *J Neurosurg* 1973 ; 39 : 493 – 7.
5. Ramamurthi B, Kalyanaraman S. Rationale for surgery in growing fractures of the skull. *J Neurosurg* 1970 ; 32 : 427 – 30.