

Traumatic Hemicraniectomy

N Khursheed M Ch, M Rumana M S, S Zahoor M S, A Ramzan M Ch
Deptt, of Neurosurgery, SKIMS, Srinagar,190011

A 5 year old child was hit by a motor vehicle. He was received in a state of shock in Accident and Emergency. His both frontal bones including the overlying scalp were avulsed and underlying dura was seen. Urgent resuscitation was started and a CT scan was done. (Figs 1-4) Child was shifted to emergency theatre; however child had a cardiac arrest from which he could not be resuscitated. The cause of blood loss was tear in the superior sagittal sinus.

Trauma is the most frequent cause of death in children¹. There are 7000 deaths per year in U.S.in children below 14yrs². The most common cause of head trauma is a fall and the most common cause of severe head injury is motor vehicle accident³

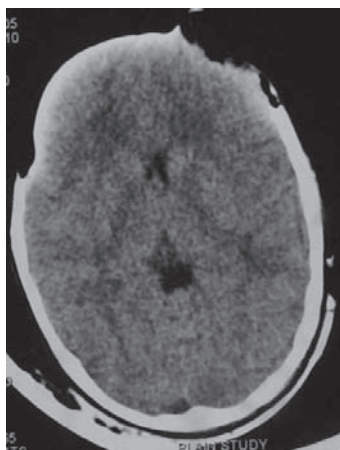


Fig. 1

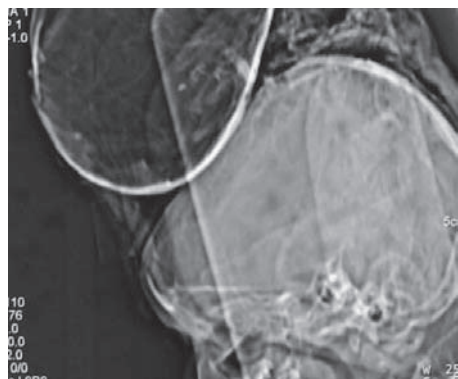


Fig. 2

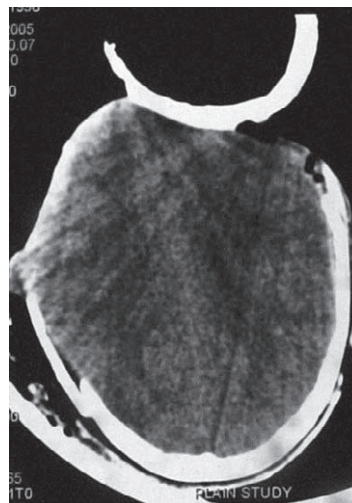


Fig. 3

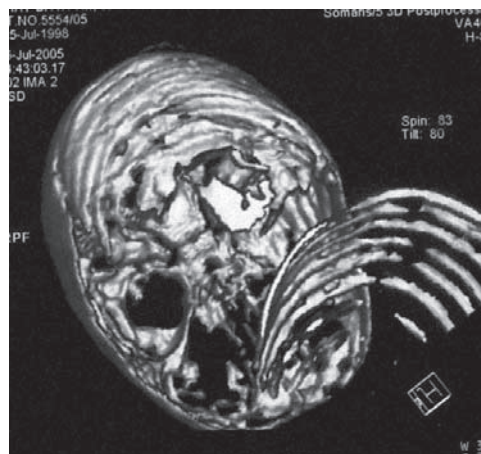


Fig. 4

REFERENCES

1. Accident facts. Chicago; National safety council,1982.
2. Aldrich EF, Eisenberg HM, Saydjari C. Diffuse brain swelling in severely head injured children. A report from the NIH Traumatic Coma Data Bank. *J Neurosurg* 1992;76;450-4.
3. Anderson DW, McLaurin RL. The National Head and spinal cord injury survey. *J Neurosurg* 1980; 53(Suppl); S1-S43.