

# Concomitant post-traumatic craniospinal multicompartmental hematoma associated with posterior fossa extradural hematoma - Case report and review of literature

B Indira Devi M Ch, Arivazhagan A M Ch, Mithun G Sattur M Ch, Sastry VR Kolluri M Ch

Department of Neurosurgery

National Institute of Mental Health and Neurosciences, Bangalore, 560029

**Abstract:** BACKGROUND: Spinal epidural hematomas following trauma are rare. There are few case reports in literature of concomitant cranial and spinal hematomas following trauma. We report a patient who presented with concomitant post traumatic cranial and spinal epidural, subdural and subarachnoid hematomas. Imaging of the upper cervical spine in patients with posterior ossa fractures and hematomas is advisable. Surgical evacuation of the hematomas is safer and would relieve symptoms.

**Keywords:** multicompartmental hematoma; post traumatic; craniospinal hematoma ; spinal epidural hematoma ; posterior fossa hematoma.

## INTRODUCTION

Spinal epidural hematomas have been reported to occur in patients with anticoagulant therapy, hypertension, and following trauma etc<sup>1,2</sup>. Rare cases of concomitant cranial and spinal epidural hematomas following trauma have been reported in literature<sup>3</sup>. They usually occur following high velocity vehicular accidents<sup>2</sup>. We report a patient with cervical spinal epidural, subdural and subarachnoid hematoma associated with posterior fossa extradural hematoma following relatively trivial trauma.

## CASE REPORT

A forty-year-old man fell backwards from a height of about 5 feet while painting the wall at his home. While falling, his head and neck hit against the edge of a paint can placed on the floor nearby. Following the fall, he complained of local pain at the back of the head and in the nape of the neck. Two hours following trauma, he was seen in a local hospital and was investigated with a

CT scan of the head (Fig 1), which showed a fracture of occipital bone extending upto the foramen magnum and extradural and subdural hematomas in the posterior fossa. There was a small left cerebellar contusion. He was managed conservatively. However, three days later, he developed suboccipital and cervical pain, double vision on looking to the right and unsteadiness of gait following which he was referred to our institute. Due to the occurrence of new symptoms and persistent neck pain, he was investigated with a repeat CT scan of the head and upper cervical spine (Fig 2), which showed extradural hematoma in the posterior fossa and cervical spinal extradural clot over C1 and C2 posteriorly. An MRI of the brain and the cervical spine (Fig 3) delineated the bleed better. The complete hemogram, liver function tests and coagulation profile of the patient were normal. Though the level of sensorium and vitals were stable, surgical evacuation was discussed and carried out. A midline suboccipital craniectomy and C1, C2 laminectomy was done. At surgery, a comminuted fracture of the occipital bone extending to the foramen magnum rim was found. There was an organizing extradural clot in the posterior fossa extending inferiorly upto C2. Dura looked bluish yellow, tense and non pulsatile. On opening the dura, a subdural hematoma was found covering the inferior vermis, tonsils and the dorsal surface of the cervical cord. Thin subarachnoid blood over the vermis and tonsils were noticed on evacuating the subdural clot. No active bleed either from the arteries or veins was found. Dura

### Corresponding Author :

Dr. B . Indira devi  
Additional Professor  
Department of Neurosurgery,  
National Institute of Mental Health and Neurosciences,  
Bangalore, 560029.  
e-mail: bindira@nimhans.kar.nic.in  
Phone: +91-080- 26995409.  
Fax: 091-080-6564830; 091-080-6562121.

was closed primarily followed by bone replacement and wound closure.

Post operatively, patient's gait ataxia improved. He had persistent right abducens palsy. The histopathology of the extradural, subdural and subarachnoid clot examined separately did not reveal any lesion.

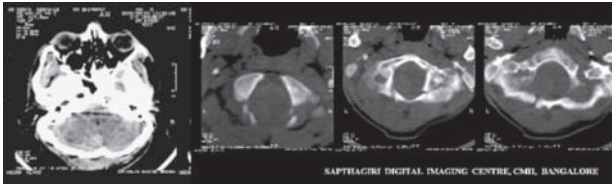


Fig 1: CT scan head 2 hours following trauma showing occipital fracture and thin posterior fossa hematoma.

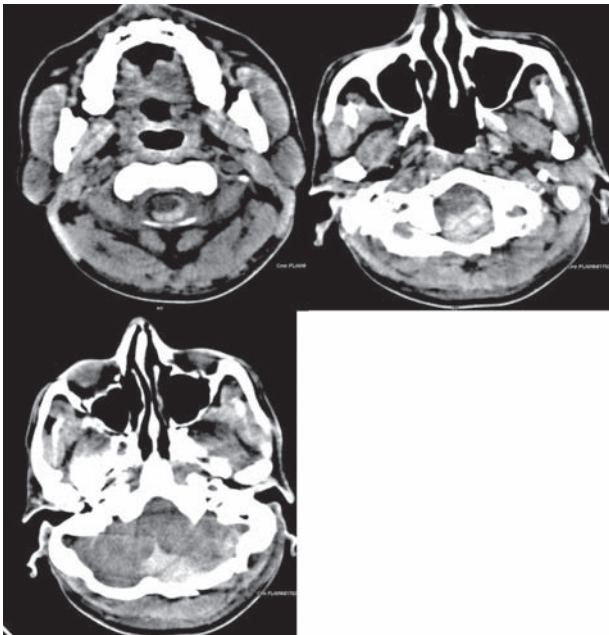


Fig 2: CT scan of head and cervical spine 3 days following trauma revealed posterior fossa extradural and subdural hematoma and cervical extradural hematoma.

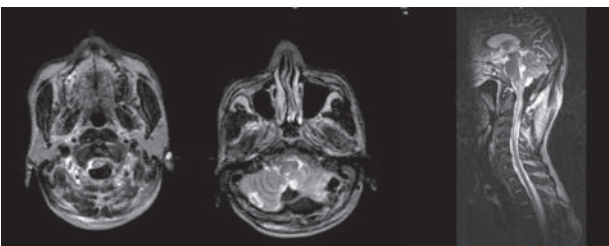


Fig 3: MRI of brain and cervical spine showing hematoma in posterior fossa extending into the cervical extradural space upto C2 level.

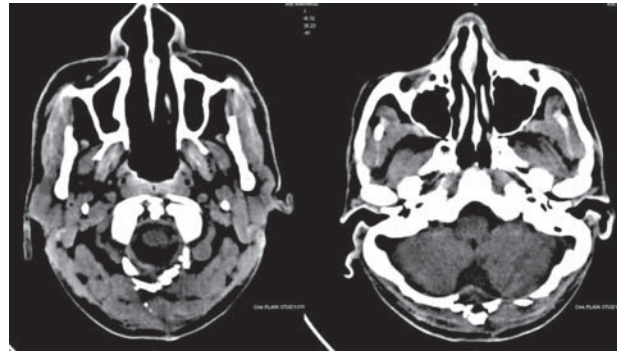


Fig 4: Post-operative CT scan showing complete evacuation of hematoma.

## DISCUSSION

Traumatic spinal epidural / subdural hematomas are rare. They may be seen in patients on anticoagulant therapy, hypertension<sup>1,2</sup>. Subdural hematoma<sup>3</sup> and subarachnoid bleed<sup>4</sup> following trauma also have been reported rarely in literature. This is probably the first reported case of traumatic cervical spinal extradural subdural and subarachnoid hematomas associated with posterior fossa extradural hematoma in English literature, to our knowledge.

The usual mechanism of injury of spinal extradural/subdural hematoma is following vehicular accidents<sup>2,5</sup>. Our patient had a fall from 5 feet height and sustained injury over the neck when it hit against the edge of a paint can. He had only neck pain and gait ataxia. It is unusual that such a relatively trivial fall had resulted in extensive hematomas involving epidural, subdural and subarachnoid spaces. He was an alcoholic, but the screening for coagulopathy was negative.

Concomitant cranial and spinal subdural hematomas have been reported in literature by Hung et al<sup>3</sup> and Bortolotti et al<sup>6</sup>. In these cases, the spinal subdural hematoma was found in the lumbar spine in association with intracranial subdural hematomas. Bortolotti et al hypothesized that redistribution of blood from the supratentorial subdural space could be the etiology of spinal subdural hematoma<sup>6</sup>.

Occipital condylar fractures have been associated with lower cranial nerve palsies<sup>2,5</sup>. Involvement of third and fourth cranial nerves with spontaneous resolution has been reported in literature<sup>2</sup>. The presence of isolated abducens nerve palsy in our patient could not be explained.

The combination of extradural, subdural and subarachnoid hematoma of posterior fossa extending into upper cervical spine has not been reported earlier. The mechanism of injury that can cause such an extensive bleed is uncertain. We hypothesise that the extradural hematoma in the posterior fossa occurred following the occipital bone fracture and spinal hematoma had probably formed following the rupture of epidural venous plexus. Cerebellar contusion and subdural hematoma could have resulted following shear injury due to local impact. An associated pia arachnoid injury probably resulted in the dissection of the arachnoid and extension of hematoma into the cisterna magna and spinal subarachnoid space.

It is not possible to be definite about the age of the hematoma since initial imaging did not include the cervical spine though CT head was done. The spinal hematomas may have occurred immediately following trauma or may have developed a few days later due to slow dissection of blood in the subarachnoid space.

The spinal hematoma in our patient was not associated with any bony cervical spine injury, hence a cervical spine X ray would not have given a clue to the underlying pathology. Other authors also have noted the absence of bony spine injuries in association with spinal subdural hematoma<sup>6</sup>.

Some authors have reported conservative management of posterior fossa and spinal epidural hematomas resulting in spontaneous resolution<sup>2,7,8</sup>. We recommend that in the presence of significant hematoma in posterior fossa or spinal cord causing compression, surgical evacuation is safer and would relieve the symptoms.

## CONCLUSION

Post traumatic concomitant craniospinal hematomas are rare. Imaging of the upper cervical spine in patients with posterior fossa fractures and hematomas is advisable. Surgical evacuation of the hematomas is safer and would relieve symptoms.

## REFERENCES

1. Boukobza M, Guichard JP, Boissonet M et al. Spinal epidural hematoma: report of 11 cases and review of literature. *Neuroradiology* 1994; 36: 456-9.
2. Cartmill M, Khazim R, Firth JL. Occipital condyle fracture with peripheral neurological deficit. *Br J Neurosurg* 1999; 13: 611-3.
3. Hung KS, Lui CC, Wang CH et al. Traumatic spinal subdural hematoma with spontaneous resolution. *Spine* 2002; 27(24): E 534-8.
4. Domenicucci M, Ramieri A, Paolini S, et al. Spinal subarachnoid hematomas: our experience and literature review. *Acta Neurochir (Wien)* 2005; 147: 741-50.
5. Tuli S, Tator CH, Fehlings MG, et al. Occipital condyle fractures. *Neurosurgery* 1997; 41: 368-377.
6. Bortolotti C, Wang H, Fraser K, et al. Subacute spinal subdural hematoma after spontaneous resolution of cranial subdural hematoma: causal relationship or coincidence? Case report. *J Neurosurg* 2004; 100(4 Suppl Spine): 372-4.
7. Cuenca PJ, Tulley EB, Devita D, et al. Delayed traumatic spinal epidural hematoma with spontaneous resolution of symptoms. *J Emerg Med* 2004; 27: 37-41.
8. Lefranc F, David P, Brotchi J, et al. Traumatic epidural hematoma of the cervical spine: magnetic resonance imaging diagnosis and spontaneous resolution: case report. *Neurosurgery* 1999; 44: 408-11.