

Circumferential fusion for sub-axial cervical spine fracture - subluxations

T S Vasan M Ch

Department of Neurosurgery
Command Hospital (EC), Kolkata (WB)

Abstract: Fracture subluxation or traumatic spondylolisthesis of sub-axial cervical spine is a common but serious spinal injury encountered by neurosurgeons. It is frequently associated with spinal cord injury. Although decompression of spinal cord either anteriorly or posteriorly depending upon the site of compression is straight forward, there is no consensus regarding the approach for stabilization of spine either anterior or posterior or both, after decompression of spinal cord. Circumferential fusion involves combined anterior and posterior stabilization of sub-axial cervical spine. Some of the cases of circumferential fusion performed by the author are presented here. Anterior stabilization was performed with titanium cage or iliac graft insertion at corpectomy or discectomy site along with Anterior cervical plating and posterior stabilization was performed with Apofix clamps or interspinous wiring (cable) or lateral mass plating. Also one patient in whom only anterior stabilization was performed but who had recurrence of dislocation is also cited as an example of inadequacy of only one approach of stabilization to a 3 column cervical spine injury.

Keywords: circumferential fusion, cervical fracture subluxation, paraplegia, quadriplegia, spinal injury, spinal fusion

INTRODUCTION

Spinal fixation or stabilization is indicated when disruption of the normal structures impairs the protective function of the spine. However there is no consensus regarding, indication for anterior, posterior or combined surgical approaches particularly in cases of severe fracture – dislocation of sub-axial cervical spine. Circumferential fusion is basically a bi-directional (anterior and posterior) approach, with circumferential arthrodesis. This technique is best used to provide solid internal stability together with bony fusion^{1,2,3}. Obviously restoration of structural integrity of the spine and protection of vital neural elements are major concerns because the posttraumatic instability of the spinal column delays rehabilitation and secondary neural compromise worsens spinal cord deficits.

Traditionally these have been stabilized by single approach either anteriorly or posteriorly apart from decompression of spinal cord. Recently many spinal surgeons have advocated the concept of combining both the above procedures, which would then give ideal

stabilization for these devastating injuries. We present some of our cases with circumferential fusion for sub axial cervical fracture subluxations and also a case where there was a recurrence of dislocation in which only anterior approach was performed.

CASE REPORT

Case:1 68 year old lady fell backwards from stairs and sustained neck injury. She presented with complete paralysis of Left (LT) Upper Limb (UL) & Lower Limb (LL) and neck pain. On examination she had 0/5 power in LT UL & LL and 2/5 power in Right (RT) UL and LL and her bladder was catheterized for retention of urine. X-Ray and CT cervical spine revealed C3/4 subluxation with upward displacement of C4 body (Fig-1, a & b)). MRI cervical spine showed traumatic listhesis of C3/4 with bilateral facet dislocation and cord contusion (Fig-1, c& d). She was initially managed with cervical traction and after obtaining proper alignment she underwent anterior C3-4 discectomy and iliac graft fusion with

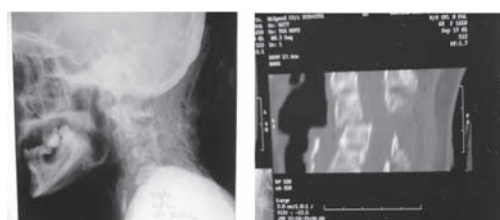


Fig 1-a & b: X-Ray & CT showing C3/4 traumatic listhesis

Address for correspondence:

Col TS Vasan
Department of Neurosurgery
Command Hospital (Western Command)
Chandimandir (Haryana)

Anterior cervical plate fixation (ACP) and followed by posterior fixation with Apo- fix clamps for C3& 4(Fig- 1, e&f). She improved neurologically and became ambulant without support and became continent.

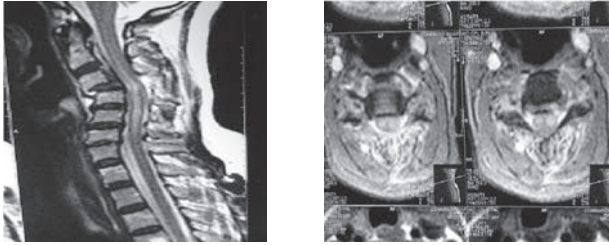


Fig 1- c & d: MRI showed traumatic listhesis of C3/4 with bilateral facet dislocation and cord contusion

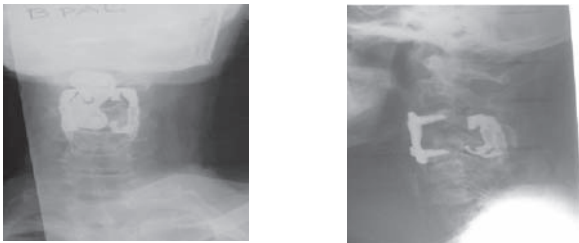


Fig 1- e & f: Post operative X-Ray - AP & Lat view showing ACP & Apofix clamps in situ

Case-2 : 23 year old serving soldier sustained road traffic accident when the taxi he was traveling over turned. He complained of only severe neck pain with no neurological deficits. X-Ray showed evidence of C2 fracture with C2/3 subluxation (Fig-2, a). CT spine with reconstruction showed hangman's fracture C2/3 subluxation (Fig, 2 b & c). MRI revealed fracture C2 pedicle with C2/3 listhesis and C2-3 disc protrusion causing cord indentation (Fig 2, d & e). There was also widening of the interspinous gap of C1 and C2. He underwent C2-3 anterior microdiscectomy with Syncage-C (Synthes)

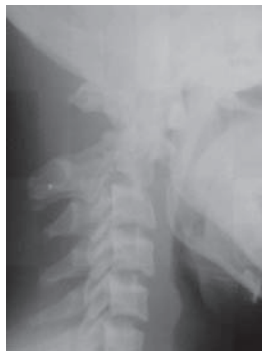

Fig 2-a: X-Ray showing fracture C2 with C2/3 subluxation

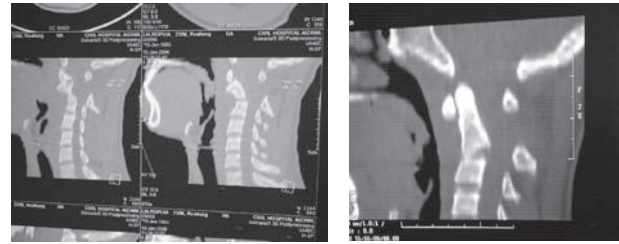


Fig 2-b & c: CT reconstruction showing hangman's # with C2/3 subluxation

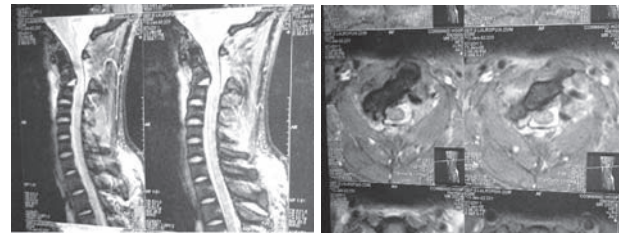


Fig 2-d & e: MRI revealed fracture C2 pedicle with C2/3 listhesis and C2-3 disc protrusion causing cord indentation. There was also widening of the neural arches of C1 & C2 posteriorly.

insertion and ACP fixation followed by C1-C2 modified Galley's fixation and fusion with atlas (Medtronic)titanium cable incorporating C3 spinous process (Fig2, f &g) as well. Presently he is performing all the routine physical job of a soldier.

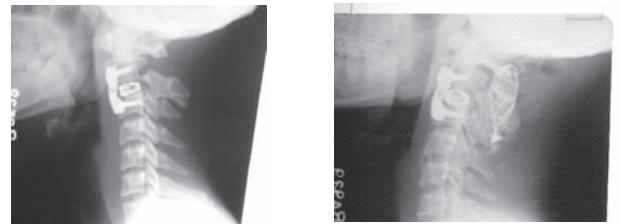


Fig 2- f & g: Post op X-Ray showing ACP with Syncage-C (inter body spacer) anteriorly & Interspinous cable grafting posteriorly.

Case-3: 32 year serving soldier fell down the ladder in drunken state from a height of 12 feet and injured his neck. He immediately found to have profound weakness of both UL and no power in both LL. He was catheterized for retention of urine. He had 2/5 power proximally and 1/5 power distally in both UL with no movement in both LL. CT scan showed burst fracture C5 body with fracture lamina of C 5&6 (Fig 3, a&b). MRI cervical spine showed C5 burst fracture and C5/6 listhesis and fracture lamina of C5 &6 with spinal canal encroachment and cord contusion (Fig 3,c&d). He underwent C5 corpectomy with C4-6 titanium cage and ACP fixation followed by C5 & 6 laminectomy and C4-C6 lateral mass plating and fusion posteriorly (Fig 3,

e&f). He recovered neurologically partially and is continent with 3/5 power in LL.

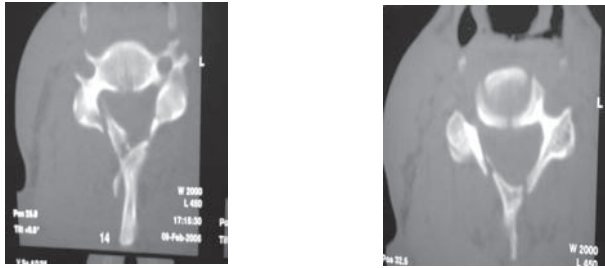


Fig 3 a & b: axial CT scans showing burst # C5 body with # lamina of C5&6

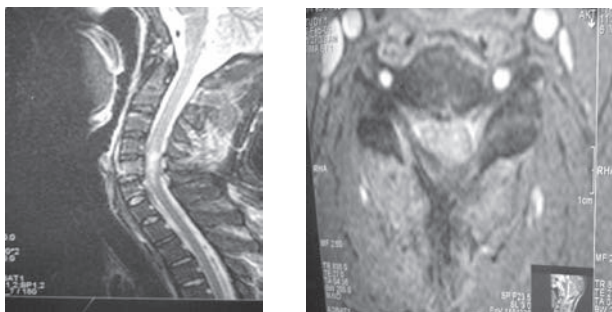


Fig 3 c & d: showing MRI sagittal & axial scans with C5/6 listhesis laminar # fragments encroaching inside spinal canal with cord contusion

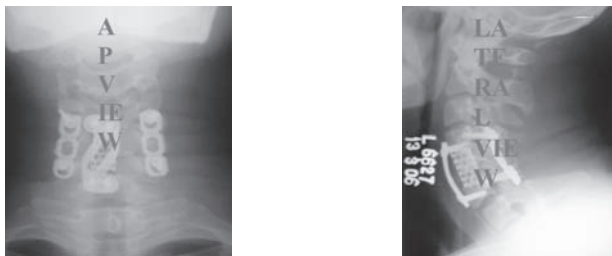


Fig 3 e & f: showing C5 corpectomy with C4-6 titanium cage and ACP fixation followed by C5 & 6 laminectomy and C4- C6 lateral mass plating and fusion posteriorly.

Case-4: 26-year-old serving soldier fell from the cycle into a ditch and injured his neck. He complained of neck pain with radiculopathy along ulnar aspect of both forearms. He had no motor deficits and had hypoesthesia in C8 dermatome bilaterally. X-Ray showed subluxation of C6/C7 (Fig 4, a). MRI revealed subluxation C6/7, locked facet joint and cord edema (Fig4, b&c). Cervical traction reduced the fracture and he underwent C6-7 microdiscectomy with titanium cage and ACP fixation anteriorly followed by C6-7 interspinous atlas cable fixation and fusion posteriorly (Fig 4, d, e&f). He is serving in his unit as a normal soldier.

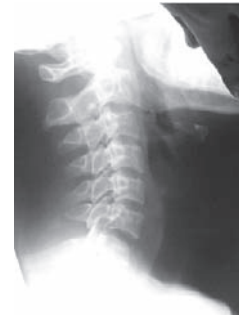

Fig 4-a: X-Ray showed subluxation of C6/C7

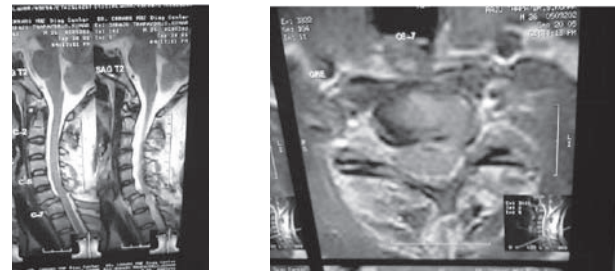


Fig 4-b& c: MRI revealed subluxation C6/7, locked facet joint and cord edema

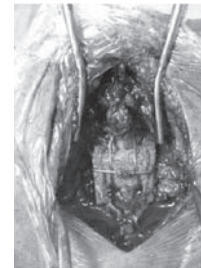


Fig 4-d: Intra operative picture showing posterior interspinous cable & grafting.




Fig 4-e & f: Post operative X-Ray showing ACP anteriorly & interspinous cable grafting posteriorly.

Case-5: 72-year-old man got injured in the neck due to fall after an accident by a speeding vehicle. He had only brief loss of consciousness but complained of weakness in all the limbs and was continent. MRI cervical spine showed fracture body C6 with cord compression and

cord edema. He underwent C6 corpectomy with titanium cage and ACP fixation. He was well after surgery and was ambulant without support. After 3 months he accidentally slipped and fell down in bathroom. He had recurrence of profound weakness in all limbs. MRI and X-Ray cervical spine (Fig 5, a&b, c) showed loosening of anterior cervical plate screws with plate and cage outside the spine with collapse at the site of C6 corpectomy. He later died of pulmonary embolism before he could be taken up for re-surgery. This case shows the catastrophic consequence of only single approach fixation for Traumatic listhesis when 3-column involvement was present.

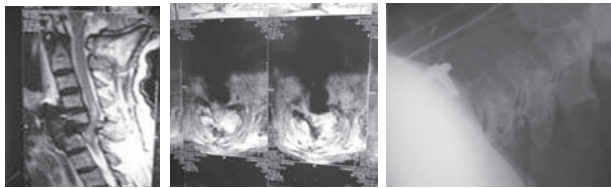


Fig 5-a & b: (MRI cervical spine), c (X-Ray cervical spine). (Earlier operated case with ACP & titanium cage-single approach). Repeat dislocation with the implant lying anterior to cervical spine.

DISCUSSION

The surgical management of fracture dislocation of the sub axial cervical spine is based on decompression of the impaired neural elements and restoration of the normal spinal arch with stabilization^{1,2,3}. Thin sections of CT and MR imaging show with clarity the relationship between bony injuries and spinal cord damage. Bohlman et al⁴ mentioned that anterior decompression may allow for maximal neurological recovery in patients with incomplete neurological deficits and radiographic evidence of persistent spinal cord compromise.

Bohlman and Anderson⁴ reported no non-unions after 72 cases with posterior arthrodesis but 9 percent of anterior arthrodesis alone had graft displacement. This has significance as fracture dislocations of cervical spine are far more treated by anterior approach.

Stuffer et al⁵ and Tucker⁶ reported that the use of anterior fusion alone was associated with the development of kyphotic deformity and graft dislodgement, most likely as a result of coexisting posterior ligamentous and osseous injury. Hence they decided to perform the combined anterior decompression and fixation and the posterior fixation for further stabilization of dislocated cervical spine. Case-5 in our study has shown when only anterior fixation was done; it failed after minor fall with

disastrous consequence.

Many authors like Kostuik et al have described loosening of the plate or screws in up to 17% of their patients after only anterior cervical plate fixation even after a short duration of follow up⁷. Paul C, et al have opted for one-stage combined anterior and posterior cervical approaches which is associated with decreased rate of postoperative graft dislodgement, failure of the instrumentation, pseudoarthrosis. There is an optimum neurological recovery with combined benefits of both anterior and posterior direct decompression of the spinal canal with circumferential arthrodesis. In their series of 100 patients follow up circumferential arthrodesis had fewer short and long term complications⁸. Mc Namara et al have also confirmed good results after circumferential fusion for acute spinal trauma⁹.

Payer M has published 5 cases of traumatic bilateral cervical locked facets of which 4 were tetraplegic¹⁰. He has suggested immediate open anterior reduction by inter body distraction and gentle manual traction, followed by circumferential fixation/fusion. He concluded that immediate open anterior reduction followed by circumferential fixation/fusion obviates the time loss from attempted closed reduction by traction for such cases. Several authors have also suggested for a combined single staged anterior and posterior approach for acute surgical management permitting early restoration of anatomic alignment and decompression while optimizing the environment for neurological recovery^{8,9}.

From a biomechanical point of view, posterior fixation devices have an advantage over anterior devices for fixation of posterior instability such as severe fracture dislocations with 3-column instability^{11,12}. Among various posterior fixation devices, lateral mass plating can achieve greater stabilization than other methods^{3,12,13} although this technique is demanding owing to possible injury to vertebral artery or the spinal roots. This is used in some of our patients (as in case-3 in our study). Lateral mass plating would be the only method available for posterior stabilization when laminectomy is done for posterior decompression of spinal cord.

The selection for approach in unstable sub axial cervical spine depends upon the biomechanical deficiencies of bony and ligamentous structures. In traumatic spondylolisthesis with fracture dislocation of spine, 3-column instability commonly exists. In the presence of both anterior and posterior ligamentous and

bony disruption combined technique provides far greater stabilization than either procedure performed alone^{9,14,15}.

Apart from traumatic spondylolistheses, circumferential fusion is also advocated for complete dislocations with unsatisfactory anterior reduction, in flexion-extension and rotation injuries associated with complete spinal cord injury, in order to favor functional rehabilitation free from orthosis¹⁶.

The procedure can be performed by variety of ways as in our cases. Anterior fixation is usually performed with ACP along with a titanium cage or bone graft taken from iliac crest. We routinely used titanium cage for all our cases as it obviates another surgery at graft site with its long-term morbidity. The cages were filled with bone chips taken from the corpectomy. Posterior fixation can be performed by interlaminar Apofix clamps, interspinous titanium cable, or by lateral mass plating for very rigid fixation along with fusion.

Failure to recognize the presence of 3-column instability can result in the failure of either posterior tension band stabilization or an anterior strut with or without a plate as a means of gaining cervical spinal instability. Failure to identify these patients' results in a sub optimal stabilization procedure that may ultimately fail with potentially catastrophic consequences as in one case cited above.

Cybuski and associates¹⁷ have identified 3 column cervical instability with following factors:

- (a) Retrolisthesis and angulation of superior vertebra over next inferior vertebra suggesting disruption of anterior and posterior longitudinal ligaments
- (b) presence of distraction of posterior interspinous ligaments sufficient to allow subluxation of the facets
- (c) Shear dislocation of one vertebra over another.

Zeidman S et al have proposed that combined stabilization is also indicated in patients with posterior ligamentous disruption or facet fracture and simultaneous anterior compression by a herniated disc¹⁵. In this situation anterior procedure is to be performed first to relieve the cord compression^{14,15}. Also in multiple level of burst fracture, combined procedure is necessary.

CONCLUSION

Circumferential arthrodesis is the ultimate stabilizing technique to obtain a rigid fixation for severe fracture

dislocation with 3-column involvement. Combined anterior and posterior fusion is a demanding technique that can be performed in variety of ways. In these clinical settings it is perhaps the optimal procedure and doing anything less is sub optimal.

REFERENCES

1. Cooper PR, Operative management of cervical spine injuries. *Clin Neurosurg* 1988; 34: 650-74.
2. Capen DA, Garland DE, Waters RL. Surgical stabilization of the cervical spine: a comparative analysis of anterior and posterior spine fusions. *Clin Orthop* 1985; 196: 229-37.
3. Mc Afee PC, Bohlman HH: One stage anterior cervical decompression and posterior stabilization with circumferential arthrodesis: A study of twenty-four patients who had a traumatic or neoplastic lesion. *J Bone Joint Surg (Am)* 1989; 71 A: 78-88.
4. Bohlman HH, Anderson PA. Anterior decompression and arthrodesis of the cervical spine: long term motor improvement. Part-I- improvement in incomplete traumatic quadriplegia. *J Bone and Joint Surg (Am)* 1992; 74A: 671-82.
5. Stauffer ES, Kelly EG. Fracture dislocations of the cervical spine: instability and recurrent deformity following treatment by anterior interbody fusion. *J Bone Joint Surg (Am)* 1977; 59A: 45-8.
6. Tucker HH. Technical report: method of fixation of subluxed or dislocated cervical spine below C1-C2. *Can J Neurol Sci* 1975; 2: 381-2.
7. Kostuik, J.P.; Connolly, P.J.; Esses, S Suh and P, I: Anterior cervical plate fixation with the titanium hollow screw plate system. *Spine* 1993; 18: 1273-8.
8. McAfee PC, Bohlman HH, Ducker TB et al: One stage anterior cervical decompression and posterior stabilization: A study of one hundred patients with a minimum of two years of follow up. *J Bone Joint surg (Am)* 1995; 77: 1791-800.
9. McNamara MJ, Devino DP, Spengler DM: Circumferential fusion for the management of acute cervical spine trauma. *J Spinal Disord* 1991; 4: 467-71.
10. Payer M. Immediate open anterior reduction and antero-posterior fixation/fusion for bilateral cervical locked facets. *Acta Neurochirurgica (Wien)* 2005; 147:509-13.
11. Abumi K, Panjabi MM, Duranceau J. Biomechanical evaluation of spinal fixation device: Part III. Stability provided by six spinal fixation devices and interbody bone graft. *Spine* 1989; 14: 1249-55.
12. Coe JD, Warden KE, Sutterlin III CE, Mc Afee PC, Biomechanical evaluation of cervical stabilization methods in a human cadaveric model.

- Spine* 1989, 14: 1121-31.
13. Jones EL, Heller JG, Silcox DH, Hutton WC. Cervical pedicle screw versus lateral mass screws: Anatomic feasibility and biomechanical comparison. *Spine* 1997; 22: 977-82.
 14. Vaccaro AR, Cook CM, McCullen G, Garfin SR: Cervical trauma: Rational for selecting the appropriate fusion technique. *Orthop Clin North Am* 1998; 29: 745-54.
 15. Zeidman S: Traumatic quadriplegia with dislocation and central disc herniation. *J Spinal Disord* 1991; 4: 490-7.
 16. De Iure F, Scimeca GB, Palmisani M, Donati U, Gasbarrini A, Bandiera S, Barbanti Brodano G, Giardina F, Boriani S. Fractures and dislocations of the lower cervical spine: surgical treatment. A review of 83 cases. *Chir Organi Mov* 2003;88:397-410.
 17. Cybulski GR, Douglas RA, Meyer PR Jr, Rovin RA: Complications in three-column cervical spine injuries requiring anterior-posterior stabilization. *Spine* 1992; 17: 253-6.