

Traumatic orbitomaxillary encephalocele

P K Upadhyay M Ch, SK Sinha M Ch

Department of Neurosurgery
GB Pant hospital, MAMC, New Delhi

Abstract: A rare case of occult traumatic intramaxillary encephalocele and intraorbital encephalocele without obvious connection to exterior is described

Keywords: encephalocele, trauma, orbital fracture, Head injury

INTRODUCTION

Orbital roof fractures are very uncommon and traumatic intra orbital encephalocele is further rare in mild blunt injury to head¹. Similarly growing orbital fracture is also reported but as such quite a rare entity in adults². Mild blunt injury causing orbital as well as roof of maxillary antrum fracture, causing brain material and contained cerebrospinal fluid to reach both these spaces together in form of an occult encephalocele, is unknown in literature, although post traumatic orbital pseudomeningocele in a young child has also been reported³. Maxillary encephalocele alone or in conjunction with orbital encephalocele is unknown in literature.

Case report

An eight-year-old boy attended our hospital services with a complaint of mild headache and swelling of right eyelid in morning, which used to subside in due course of time only to recur next morning. This was associated with occasional double vision. There was no vomiting, seizures or fever. There was no history suggestive of cerebrospinal fluid leak from nose, eye or into the pharynx. On detail enquiry a history of mild blunt injury to head were elicited. On examination no neurological deficit was found. There was no bony defect or strabismus. Slight puffiness however could be detected in the upper right eyelid. MRI showed that there was protrusion of brain material along with cerebrospinal fluid pouch in the Right orbit (Figs1-2) and right maxillary antrum (Fig 3). Patient was advised to under go prophylactic repair. But the relatives preferred to wait for some more time citing their personal reasons at present.

Address for correspondence:

Dr P.K Upadhyay
Department of Neurosurgery, GB Pant Hospital, New Delhi.
pkupadhyay5@yahoo.co.in

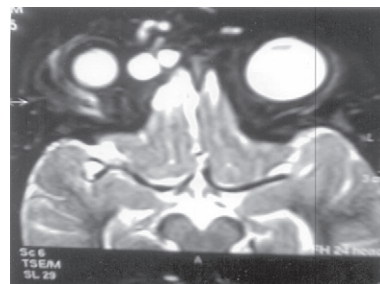


Fig 1 : (L) intra orbital encephalocele

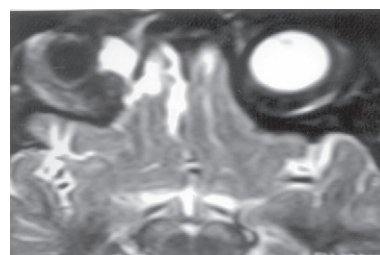


Fig 2 : (L) intra orbital encephalocele

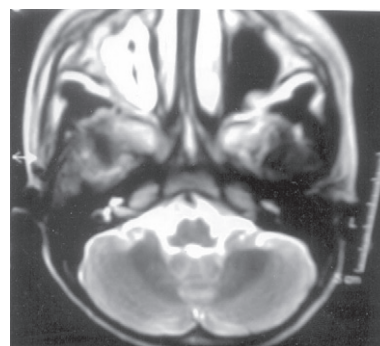


Fig 3 : (L) Intra maxillary encephalocele

DISCUSSION

Orbital roof fracture is uncommon in head injury and its association with traumatic orbital encephalocele is further rare. Traumatic occult intramaxillary encephalocele is unknown in literature. In case of 44 orbital roof fractures, only six have been found to be

associated with orbital encephalocele¹. Orbital fracture of 2 mm size with frontal contusion in children, are at greater risk of developing intraorbital encephalocele and need to be watched¹. If the width is found to be 2-4 mm, then duraplasty and orbitoplasty is required to treat these children¹. Localization of growing skull fracture to orbital roof region is even rare in adults². Traumatic encephalocele in orbital cavity is rare with only 15 cases published³ so far. Road traffic accident is the most common cause. Ecchymoses, preoperative exophthalmos and proptosis is frequent, hence these cannot be termed occult in the true sense. Orbital roof fracture and orbital encephalocele was found in four cases. Associated brain contusions have been seen in five cases⁴; however no intramaxillary encephalocele was detected. After surgical treatment with frontobasal approach with evacuation of the contused herniated brain tissues were done. The orbital roof reconstruction was also performed. Outcome was good with recovery of ocular functions, in most of these cases⁴. Such injury although reported to be rare in the adult age group, five out of six cases in the report by Antonelli were adults⁴.

CONCLUSION

Head injury leading to orbital roof fractures with contusion of frontal lobe, especially in its basal area, should be suspected to harbor an orbital encephalocele. Orbital roof fracture is rare after head injury or blunt injury and it is further difficult to detect in routine X

rays & CT scanning. It is still rare to find growing fracture of the orbital roof and encephalocele in orbit. Therefore if patient has frontal contusion and fracture of orbital floor is found, encephalocele should be suspected, more so in cases of visual complaints. MRI should be requisitioned and looked for encephalocele and other anomalies. Once an encephalocele is confirmed, surgical approach through subfrontal route is preferred. Contused brain is excised, and the gap in orbital roof is reconstructed. Good results, especially for ophthalmic symptoms like exophthalmos, diplopia, and strabismus are expected immediately.

REFERENCES

1. Cayli SR, Kocak A, Kultu R, Tekiner A, Ates U, Sahinbeyoglu B. Intra orbital encephalocele: an important complication of orbital roof fractures in pediatric patients. *Paediatr Neurosurg* 2003; 39: 240-5.
2. Giuffrida M, Cultrera F, Antonelli V, Campobassi A, Servadei F. Growing fracture of orbital roof with post traumatic encephalocele in an adult patient. Case report. *J Neurosurg Sci* 2002; 46: 131-4.
3. Kumar R, Verma A, Sharma K, Rathi B, Malik V. Post traumatic pseudomeningocele of the orbit in a young child. *J Pediatr Ophthalmol Strabismus* 2003; 40: 110-2.
4. Antonelli V, Creminii AM, Campobassi A, Pasculla R, Zofrea, Servadei F. Traumatic encephalocele related to orbital roof fractures: Report of six cases and literature review. *Surg Neurol* 2002 ; 57: 117-25.