

Multiple nerve transfers for the reanimation of shoulder and elbow functions in irreparable C5, C6 and upper truncal lesions of the brachial plexus

PS Bhandari M Ch, LP Sadhotra M Ch, P Bhargava M Ch, AS Bath M Ch
MK Mukherjee M Ch, TS Bhatti M Ch, S Maurya MS

Dept of Plastic & Reconstructive Surgery
Armed Forces Medical College & Command Hospital (SC) Pune-40

Abstract: In irreparable C5, C6 spinal nerve and upper truncal injuries the proximal root stumps are not available for grafting, hence repair is based on nerve transfer or neurotization. Between Feb 2004 and May 2006, 23 patients with irreparable C5, C6 or upper truncal injuries of the Brachial Plexus underwent multiple nerve transfers to restore the shoulder and elbow functions. Most of them (16 patients) sustained injury following motor cycle accidents. The average denervation period was 5.3 months. Shoulder function was restored by transfer of distal part of spinal accessory nerve to suprascapular nerve, and transfer of radial nerve branch to long head of triceps to the anterior branch of axillary nerve. Elbow function was restored by transfers of ulnar and median nerve fascicles to the biceps and brachialis motor branches of musculocutaneous nerve. All patients recovered shoulder abduction and external rotation; 7 scored M4 and 16 scored M3. Range of abduction averaged 123° (range, 80°-170°). Full elbow flexion was restored in all 23 patients; 15 scored M4 and 8 scored M3. Patients with excellent results could lift 5 kgs of weight. Selective nerve transfers close to the target muscle provide an early and good return of functions. There is negligible morbidity in donor nerves. These intraplexal transfers are suitable in all cases of upper brachial plexus injuries.

Keywords: brachial plexus injury, C5-C6 injuries, upper truncal lesions, nerve transfers

INTRODUCTION

In irreparable C5, C6 spinal nerve and upper truncal injuries the proximal root stumps are not available for grafting, hence repair is based on nerve transfer or neurotization. Restoration of elbow flexion takes priority in functional reconstruction¹, followed by shoulder abduction and external rotation. Reinnervation of musculocutaneous nerve has been achieved with transfer of a variety of donor nerves; the spinal accessory nerve^{2,3}, the medial pectoral nerve⁴, the phrenic nerve^{5,6}, the thoracodorsal nerve⁷ and the intercostals nerves^{8,9}. The functional results have been unpredictable with the use of phrenic nerve, medial pectoral nerve and the thoracodorsal nerve. Use of distal end of spinal accessory nerve requires long nerve graft and results are far from satisfactory. Multiple donor nerves are required while using the intercostals nerves.

Selective neurotization of biceps and brachialis muscles

Address for correspondence:

Col PS Bhandari, Senior Adviser Reconstructive Surgery,
Command Hospital (SC) Pune- 411040
E-mail: doctorbhandari@hotmail.com
Mobile: 09373504220

with part of ulnar¹⁰ and median nerves¹¹ have produced consistently good functional results without notable impairment of hand function¹².

Transfer of the spinal accessory nerve to the suprascapular nerve produces an average of 45 degrees of shoulder abduction (range from less than 20 to 80°)¹³. Recently many surgeons have recommended nerve transfers to both the suprascapular and axillary nerves to achieve better results^{13,14}. Transfer of motor branch to long head of triceps to anterior branch of axillary nerve produces minimal functional loss and is compensated easily by the remaining of the triceps and the teres muscle group¹⁵.

MATERIALS AND METHODS

From Feb 2004 to May 2006, 23 patients presented with upper brachial plexus injury. These patients were having irreparable injuries of C5 and C6 spinal nerves and upper trunk. The irreparable injuries included root avulsions (8 cases) and extensive injuries of the upper trunk with doubtful viability of C5 and C6 spinal nerves (15 cases). In these cases even after a very proximal dissection, healthy nerve stumps could not be found. Instead of

performing laminectomies, we favored selective and direct distal nerve transfers. The mechanisms of injury were motorcycle accident in 16 patients, motor vehicle accidents in 6 and fall from the roof in 1 patient. Twenty two of patients were men. The mean age of the patients was 25.6 years (range, 18 to 38 years), and the denervation ranged from 3 months to 9 months (mean, 5.3 months). All patients underwent detailed clinical examination and electrophysiological studies. Baseline investigations included MRI myelography and electromyography. Preoperative shoulder abduction and elbow flexion were graded as 0°. Deltoid, supraspinatus, infraspinatus, biceps, brachialis and brachioradialis muscles were M₀ according to Medical Research Council scoring. There was M₅ power in trapezius muscle and M₄ in triceps. Preoperative grip strength averaged 28.1 kg (range, 8 to 36 kg) and pinch strength averaged 5.9 kg (range, 2.5 to 8 kg). Preoperative 2-point discrimination at the pulp of index and little fingers averaged 3.6 mm each (range, 2 to 4 mm). Each patient presenting with complete paralysis of shoulder and elbow was explored under general anaesthesia. Exploration revealed either root avulsions in C5, C6 (8 patients) or severe fibrosis of C5, C6 spinal nerves extending into the upper trunk. Hence these root stumps were considered unsuitable for nerve grafting. In early cases a long vertical incision along the posterior border of sternocleidomastoid was used to explore the upper part of spinal accessory nerve which was then traced distally. In later cases a short reverse 'C' shaped incision was used to explore the distal spinal accessory nerve. Spinal accessory nerve was divided after the branches to upper trapezius were given off. The suprascapular nerve was identified emerging from the upper trunk and divided close to its origin. The spinal accessory nerve was coapted with the suprascapular nerve with 10-0 nylon sutures. A tension free coaptation was ensured.

For the transfer of motor branch to long head triceps to the axillary nerve, patient was placed in semilateral position with upper arm over the thorax. An oblique incision was made along the posterior border of deltoid. The cutaneous nerve (a terminal branch of axillary nerve) was traced to its origin from the posterior branch of axillary nerve, in the quadrilateral space, bounded above by the teres minor, below by the teres major, laterally by the humerus and medially by the long head of triceps muscle. After emerging from the quadrilateral space, the axillary nerve gives a branch to teres minor muscle and then divides in 1 to 3 anterior branch(es) and one posterior branch. The anterior branch or branches

provide major motor supply to the deltoid. This branch or branches were dissected intraneurally as proximal as possible and transected. At the lower border of teres major the nerve to long head of triceps was identified and followed to its origin from the radial nerve. This branch was sectioned as distally as possible and then flipped 180° to be coapted to the anterior branch or branches of the axillary nerve.

Oberlin transfer (partial transfer of ulnar nerve to the biceps motor branch) was made through a longitudinal incision on the anteromedial aspect of the upper arm. The musculocutaneous nerve was identified after it traversed the coracobrachialis muscle. The motor branch to biceps was usually seen at an average distance of 130 mm from the acromion. In 18 cases, there was one common branch to the short and long head of biceps muscle. In the other 4 cases, there were two separate branches. In 1 case, three branches were seen emerging from the common trunk of musculocutaneous nerve, the third primary branch to biceps muscle was rudimentary. The nerve to the brachialis muscle was found at an average of 193.4 mm below the acromion. In 17 cases, there was a single branch from the musculocutaneous nerve. In 6 cases, two branches were supplying the brachialis muscle. The biceps motor branch was traced as far proximally as possible and then sectioned. The ulnar nerve was identified at the same level and a longitudinal epineurotomy was made. One ulnar nerve fascicle, carrying motor fibers to the flexor carpi ulnaris (confirmed by electrical stimulation) was minimally dissected, sectioned and coapted to the biceps motor branch with 10-0 nylon sutures. Fascicle of the median nerve that innervated the wrist flexor was identified and coapted with the motor branch to the brachialis. Again a tension free nerve anastomosis was ensured.

Postoperatively the flexed arm was strapped to the chest for a period of 3 weeks. After that gradually increasing passive exercises were begun. Paralysed muscles were subjected to electrical stimulation till a grade 3 power was achieved.

Follow up evaluation

All patients were evaluated at 3 monthly intervals for a period of 18 to 48 months (average 32 months). Range of movements was noted with goniometry. Preoperative and postoperative grasping and key pinch strengths were measured with dynamometers. Sensory evaluation was made by measuring the 2-point discrimination at the pulp

of index and little fingers. British Medical Research Council grading system was used to evaluate the strength of elbow flexion, extension and shoulder abduction, ranging from 0 (no evidence of contractility) to 5 (complete range of motion against gravity with full resistance).

RESULTS

The study results are presented in Table 1 & Table 2 and figures 1 to 18.

Table 1: Clinical data

Patient No	Age (yrs)	Sex	Interval between injury & surgery (in months)	Interval between surgery & recovery of elbow flexion to M3 (in months)	Interval between surgery & recovery of shoulder abduction to M3 (in months)	Range of shoulder abduction achieved after final follow up
1.	22	M	4	6	11	170°
2.	26	M	6	7	13	140°
3.	21	M	3	5	9	150°
4.	32	M	7	9	15	100°
5.	19	M	3	5	8	150°
6.	27	M	9	10	17	80°
7.	30	M	4	7	12	130°
8.	29	M	8	10	14	100°
9.	31	M	3	6	9	150°
10.	38	M	9	12	20	90°
11.	25	M	7	8	12	110°
12.	19	M	6	6	11	130°
13.	23	M	5	8	14	140°
14.	28	M	7	11	18	100°
15.	30	M	3	6	9	140°
16.	22	M	4	7	11	140°
17.	31	M	6	7	12	130°
18.	24	M	5	7	13	110°
19.	18	M	4	6	9	140°
20.	23	F	7	9	14	110°
21.	19	M	3	5	7	120°
22.	24	M	7	8	12	90°
23.	29	M	4	7	11	120°

All the patients recovered full elbow flexion; 15 scored M4 and 8 scored M3.

The mean period of time from surgery to electromyographic recovery of the biceps and brachialis muscles were 2.5 months (range, 2-5) and 2.8 months (range, 2-5). All patients recovered shoulder abduction; 7 scored M4 and 16 scored M3 in abduction. Range of

abduction averaged 123° (range, 80°-170°). Four patients with C5 and C6 root avulsion could achieve 150 and above of active shoulder abduction at final follow up. Four patients experienced transient paresthasias in little finger and three in the index finger which lasted for 2 to

Table 2: Comparison of grip strength, pinch strength and 2-Point Discrimination

Patient No	PRE OPERATIVE				POST OPERATIVE			
	Grip (Kgf)	Pinch (Kgf)	2-PD Index finger (mm)	2 PD Little finger (mm)	Grip (Kgf)	Pinch (Kgf)	2-PD Index finger (mm)	2 PD Little finger (mm)
1	32	7	4	4	44	8	4	4
2	28	6	4	4	36	7	4	4
3	36	7	4	4	46	8	4	4
4	28	5	4	4	38	6	4	4
5	36	8	4	4	47	13	4	4
6	20	3.5	3	3	24	4	3	3
7	24	4.5	3	3	30	7	3	3
8	14	3.5	2	2	22	8	2	2
9	30	7	4	4	38	9	4	4
10	8	2.5	2	2	14	5	2	2
11	23	3	3	3	30	5	3	3
12	32	6.5	4	4	39	9	4	4
13	31	7.5	4	4	40	10	4	4
14	22	3	3	3	28	6	3	3
15	35	8	4	4	45	13	4	4
16	33	7.5	4	4	41	12	4	4
17	28	6.5	4	4	33	9	4	4
18	30	6	4	4	39	9	4	4
19	32	7.5	4	4	42	12	4	4
20	29	6.5	4	4	34	9	4	4
21	35	8	4	4	44	13	4	4
22	31	7	4	4	40	12	4	4
23	30	6.5	4	4	40	11	4	4

3 weeks. Five patients developed pointing index which improved with time. Grip strength, pinch strength and 2-point discrimination in the little and index fingers were measured and compared with unaffected side before and after surgery (Table 2). Patients with excellent results could lift 5kg of weight. Extension of elbow was down graded

from M4 to M3 in 6 patients.

At the final assessment, conducted 18 - 48 months after surgery, grip and pinch strength were found to be stronger than before surgery, possibly due to increased use of the hand once elbow flexion was restored.

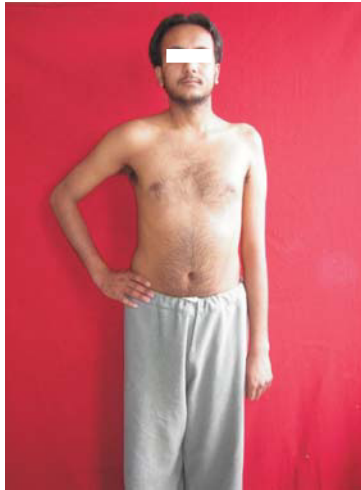

Fig 1: Left sided upper brachial plexus injury

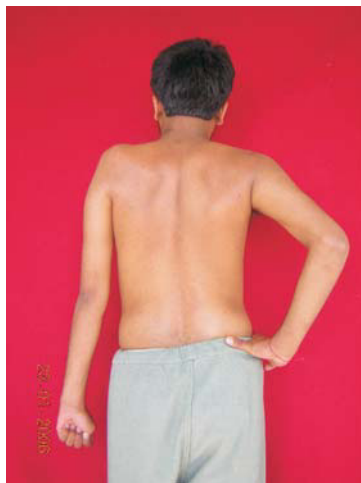

Fig 2: No function at shoulder and elbow, however hand function is good

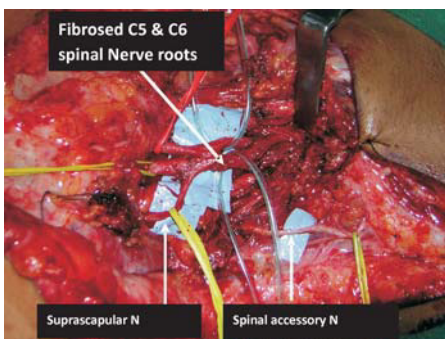


Fig 3: Exploration of supraclavicular brachial plexus

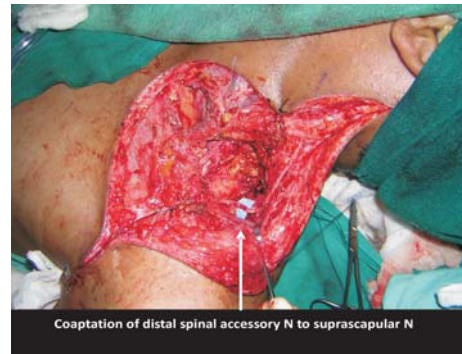


Fig 4: Transfer of distal spinal accessory nerve to suprascapular nerve

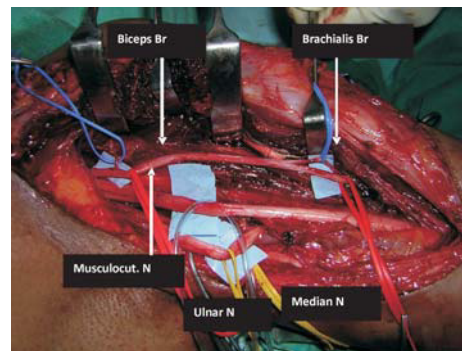


Fig 5: Exploration of nerves for Oberlin transfer

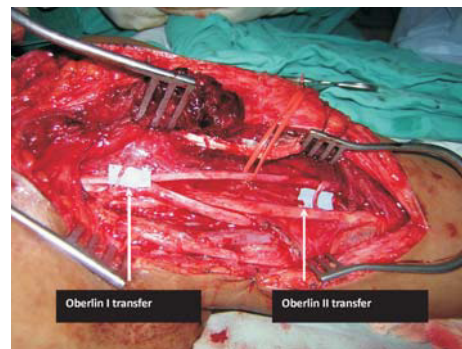


Fig 6: Transfer of ulnar and median nerve fascicles to biceps and brachialis motor branches of musculocutaneous nerve

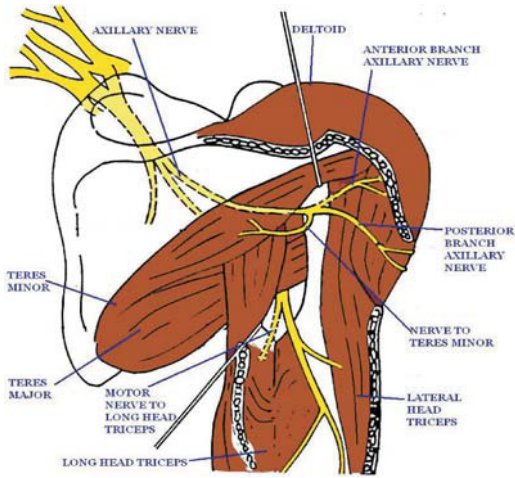


Fig 7: Anatomy of quadrangular and triangular spaces

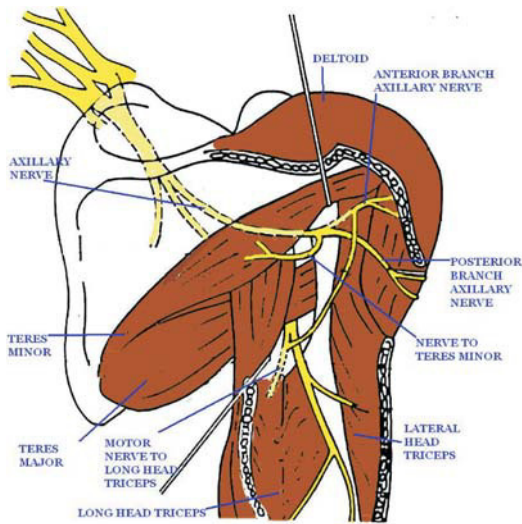


Fig 8: Transfer of radial nerve branch long head triceps to anterior branch of axillary nerve

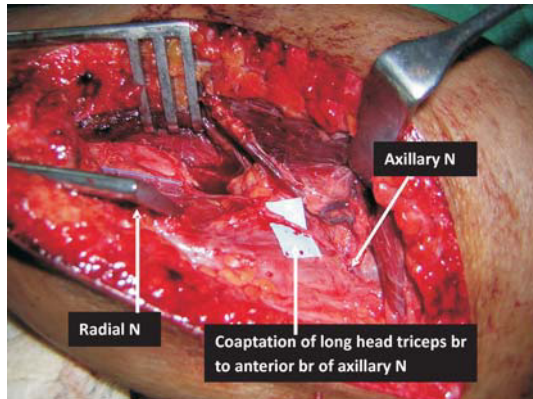


Fig 9 : Transfer of long head triceps branch of radial nerve to anterior branch of axillary nerve

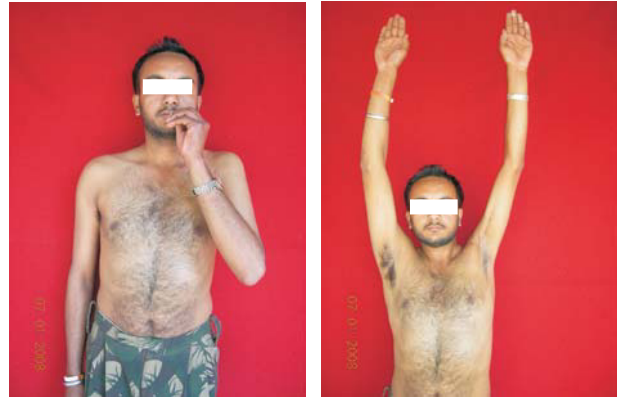

Fig 10 & 11 : Excellent results in elbow flexion and shoulder abduction following multiple nerve transfers

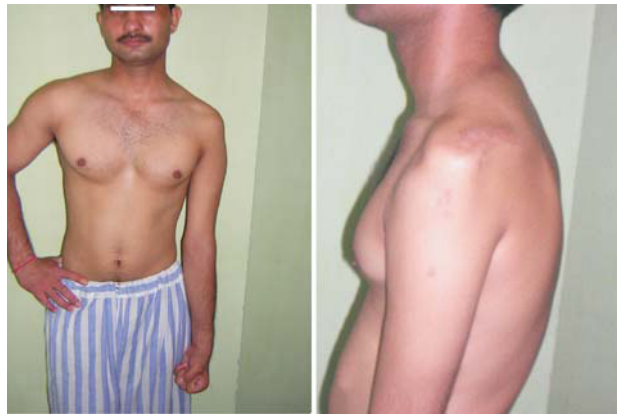

Fig 12: C5 & C6 injury with muscle wasting

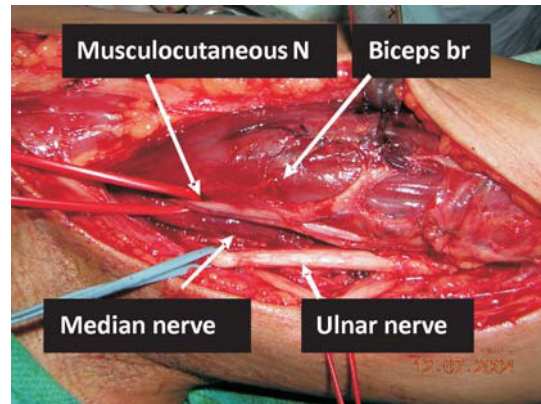


Fig 13: Exploration of nerves for Oberlin 1 transfer

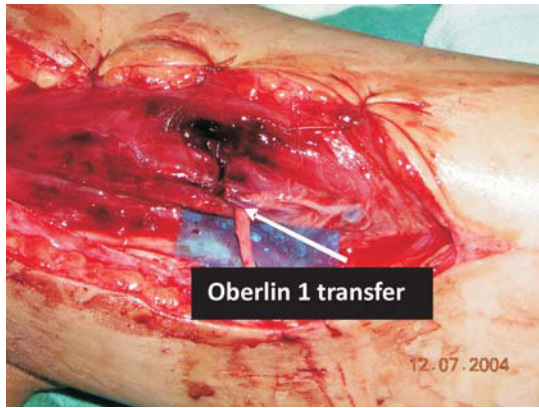

Fig 14: Transfer of ulnar nerve fascicle to biceps motor branch of musculocutaneous N

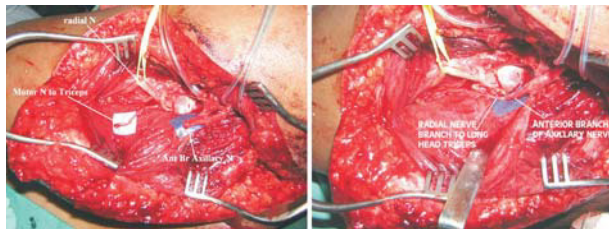


Fig 15: Transfer of radial nerve branch long head triceps to anterior branch of axillary nerve

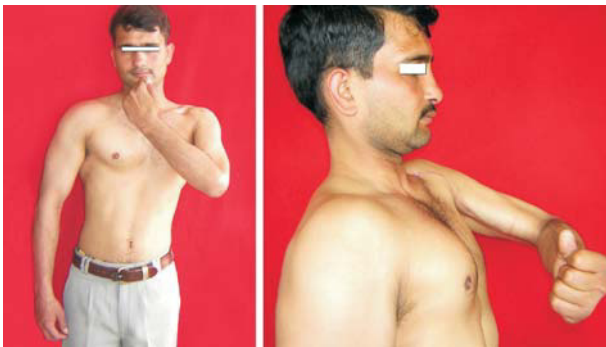

Fig 16: Grade M4 + elbow flexion with contracting biceps muscle

DISCUSSION

C5 and C6 palsies occur in 15 to 20 percent of supraclavicular plexus injuries¹⁶. Repair of these injuries offer good prognosis because the hand functions are preserved. If the injury is in the roots in the scalenic area or upper trunk, there is a good possibility for nerve repair with a satisfactory result. In C5 and C6 root avulsions, nerve repair is not possible and nerve transfers offer far superior results over tendon/ muscle transfers or shoulder arthrodesis¹⁷. Also in some upper truncal injuries extensive fibrosis makes the proximal root stumps of doubtful viability. In such cases nerve transfer



Fig 17: Restoration of full shoulder abduction following nerve transfers to suprascapular and axillary nerves

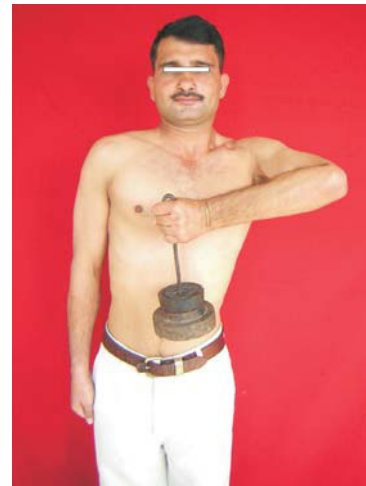

Fig 18: Lifting of 7 Kg weight with elbow flexed

remains the only viable option of rehabilitating the arm. It is well accepted that the two main priorities in nerve transfers are the restoration of elbow flexion and shoulder abduction¹⁵. Elbow flexion has been achieved with many donor nerves including the intercostal nerves^{8,9,17,18-22}, medial pectoral nerve^{4,23}, phrenic nerve^{5,6}, thoracodorsal nerve⁷, spinal accessory nerve^{2,3} and recently introduced Oberlin transfer¹⁰. An intercostal nerve contains no more than 500 motor fibers²¹, hence at least two or three intercostals nerves (T3, T4 and T5) are coapted with the motor component of musculocutaneous nerve. Some surgeons do not recommend intercostals to musculocutaneous transfer²⁵ as the surgery is challenging

and time consuming²⁶, results are not consistent²⁷, and life threatening complications have been observed²⁸.

Transfer of medial pectoral nerve to the musculocutaneous nerve is one of the most controversial procedures⁴. In 1948, Lurje²⁹ described the use of this nerve as a donor in patients with Erb's palsy. Thereafter only a few reports of the use of this nerve transfer were published. Some authors do not recommend this type of nerve transfer at all⁴. Chuang et al¹⁷ and Gu et al^{5,6} have popularized the transfer of phrenic nerve to musculocutaneous nerve (either directly or with a sural nerve graft). This procedure again has not gained wide acceptance amongst the western surgeons as it sacrifices an important motor nerve, contraindicated in children and can not be combined with simultaneous intercostals nerve transfer²⁶.

The spinal accessory nerve has the disadvantage of requiring a long nerve graft to reach the musculocutaneous nerve³².

Transfer of a single fascicle of ulnar nerve to the motor branch of biceps¹⁰ and a fascicle median to the brachialis¹¹ have produced the most promising results as there is no wastage of any donor nerve fibers to the sensory part of musculocutaneous nerve. Since the nerve transfer is performed close to the target muscle, the return of function is faster. This technique requires no special re-education of the muscle. Sparing of 1 or 2 fascicle from the ulnar and median nerves does not result in any subjective deficit of hand function^{11, 12}. Preoperative and postoperative evaluation of pinch strength, grip strength and two point discrimination at the pulp of little and index fingers remain unaltered. In the series reported by Somsak Leechavengvongs et al¹² thirty-two patients with absent elbow flexion underwent nerve transfer using 1 or 2 fascicles of the ulnar nerve to the motor branch of the biceps muscle. Twenty-six patients had root avulsion injury of C5 and C6; 4 had root avulsion injury of C5, C6, and C7; and 2 had lateral and posterior cord injury with distal injury of the musculocutaneous nerve. The mean denervation period was 6 months. At the final follow up thirty patients had biceps strength of M4 and 1 had biceps strength of M3. One elderly patient operated 1 year after injury did not demonstrate any sign of recovery. In Mackinnon series³³ six patients underwent double fascicular transfers. At the final follow up evaluation elbow flexion strength was MRC grade 4+ in four patients and grade 4 in two patients. In the series reported by Liverneaux et al³⁴ fifteen patients underwent

double nerve transfers to restore elbow flexion. The authors had follow up of more than 6 months in 10 of them. Six had C5, C6 injuries, three had C5, C6, C7 palsies and one had sustained an infraclavicular injury. The average delay before surgery was 6.6 months. Grade 4 elbow flexion was restored in each of the 10 patients. In Sungpet series³⁵ thirty six patients with upper root avulsions underwent transfer of a single fascicle from the ulnar nerve to the proximal motor branch of the biceps muscle. Thirty-four patients achieved biceps strength of MRC grade 3 or better. Importantly, they also included 2 patients with C5, C6, and C7 avulsions. All these studies highlight the reliability of fascicular transfers in restoring elbow flexion in upper brachial plexus injuries.

Shoulder stability and abduction can be restored by arthrodesis, muscle tendon transfer and nerve transfers. Shoulder arthrodesis yields a poor range of motion¹⁷. It is difficult to achieve satisfactory abduction by muscle/tendon transfers with use of trapezius, levator scapulae, sternocleidomastoid or latissimus dorsi muscles^{17, 36, 37}. Nerve transfer, however, provides good range of shoulder abduction and stability^{38, 39}. Transfer of distal spinal accessory nerve to the suprascapular nerve restores an average of 45° of abduction and some external rotation by reactivating the supraspinatus and infraspinatus muscles. A simultaneous transfer of suprascapular nerve and axillary nerve yields much better results when adequate donors are available^{17,40,41}. Axillary nerve neurotization can be performed through an anterior approach using phrenic nerve, distal spinal accessory nerve, intercostal nerves or medial pectoral nerve as donor nerves. This approach not only requires nerve grafts but also results in dilution of nerve fibers entering the deltoid muscle⁴². A posterior approach allows the transfer of nerve to the long head of triceps (which contains mainly motor fibers) to the anterior branch of axillary nerve which innervates the anterior and middle deltoid muscle. This transfer avoids the misdirection of the regenerated axons in to the cutaneous branch and teres minor¹⁵. The functional loss is minimal and is compensated by remaining two heads of triceps and the teres muscle group. Amongst the three heads of the triceps, the long head plays the least important role during elbow extension⁴³. The long head of triceps has been transferred for axillary contracture⁴⁴, and as a free functioning muscle transfer⁴⁵. Leechavengvong et al⁴⁶ reported seven patients with C5 and C6 avulsion injuries who underwent double nerve transfers (distal spinal accessory nerve to

suprascapular nerve and long head triceps branch to anterior branch of axillary nerve). The mean shoulder abduction achieved was 124°. Same authors⁴⁷ report a series of 15 patients with 8 patients achieving shoulder abduction in the range of 130° to 160°. Again in all these patients root avulsions were confirmed prior to reconstruction.

In our series of the patients, the indications for nerve transfers has been root avulsion injuries as well as extensive upper truncal and proximal C5 and C6 spinal nerve injuries with possible intact long thoracic and dorsal scapular nerves. This is probably the reason why our patients scored well in restoring good range of shoulder abduction. Instead of dissecting very proximally or performing laminectomies, we favoured distal nerve transfers. Even in the presence of rudimentary viable root stumps, nerve grafting would have been technically difficult in these cases. The other reason could be a shorter denervation period in young, healthy and highly motivated individuals who followed pre and post physiotherapy programmes extremely well.

CONCLUSION

The new nerve transfers as popularized by the Oberlin, Tung, Sungpet, Loy, Leechavengvongs, and Bartelli provide selective neurotization closer to the motor end plates, hence allow an early return of function. The return of power is much superior to the other conventional methods of nerve transfers. The functional loss is minimal. We propose this strategy of multiple nerve transfers as a standard procedure in the management of irreparable lesions of C5,C6 spinal nerves and upper trunk.

REFERENCES

1. Narakas A. Surgical treatment of traction injuries of the brachial plexus. *Clin Orthop* 1978; 133:71 – 90.
2. Allieu Y, Cenac AP. Neurotization via the spinal accessory nerve in complete paralysis due to multiple avulsion injuries of the brachial plexus. *Clin Orthop* 1988; 237: 67 – 74.
3. Songcharoen P, Mahaisavariya B, Chotigavanich C. Spinal accessory neurotization for restoration of elbow flexion in avulsion injuries of the brachial plexus. *J Hand Surg* 1996; 21A: 387 – 90.
4. Samardzic M, Grujicic D, Rasulic L, Bacetic D. Transfer of the medial pectoral nerve : Myth or reality? *Neurosurgery* 2002; 50: 1277 – 82.
5. Gu YD, Wu MM, Zheng YL et al. Phrenic nerve transfer to treat root avulsion of brachial plexus. *Clin Hand Surg* 1989; 5: 1- 3.
6. Gu YD, Wu MM, Zheng YL et al. Phrenic nerve transfer for brachial plexus motor neurotization. *Microsurgery* 1989; 10: 287 – 9.
7. Dai S –Y, Lin D-X, Han Z, Zhoug S-Z. Transfer of thoracodorsal nerve to musculocutaneous or axillary nerve in old traumatic injury. *J Hand Surg* 1990; 15A: 36 – 7.
8. Chuang DCC, Yeh MC, Wei FC. Intercostal nerve transfer of the musculocutaneous nerve in avulsed brachial plexus injuries. *J Hand Surg* 1992; 17A: 822 – 8.
9. Krakauer JD, Wood MD. Intercostal nerve transfer for brachial plexopathy. *J Hand Surg* 1994; 19A: 829 – 35.
10. Oberlin C, Beal D, Leechavengvongs S, Salon A, Dauge MC, Saruj J J. Nerve transfers to biceps muscle using part of ulnar nerve for C5 – C6 avulsion of the brachial plexus; anatomical study and report of four cases. *J Hand Surg* 1994; 19A: 232 – 73.
11. Tung TH, Novak CB, and Mackinnon SE. Nerve transfer to the biceps and the brachialis branches to improve elbow flexion strength after brachial plexus injuries. *J Neurosurg* 2003; 98: 313 – 8.
12. Leechavengvongs S, Witoonchart K, Uerpairojkit C, Thuvasethakul P, Ketmalasiri W. Nerve transfer to biceps muscle using a part of the ulnar nerve in brachial plexus injury (upper arm type): a report of 32 cases. *J Hand Surg* 1998; 23A: 711 – 6.
13. Chuang D C C, Lee G W, Hashom F, Wei F C. Restoration of shoulder abduction by nerve transfer in avulsed brachial plexus injury. Evaluation of 99 patients with various nerve transfers. *Plast Reconstr Surg* 1995; 96: 122 – 8.
14. El-Gammal T A, Fathi N A. Outcome of surgical treatment of brachial plexus injuries using nerve grafting and nerve transfers. *J Reconstr Microsurg* 2002; 18: 7 – 15.
15. Witoonchart K, Leechavengvongs S, Uerpairojkit C, Thuvasethakul P, Wongnopsuwan V. Nerve transfer to deltoid muscle using the nerve to the long head of the triceps, part I: An anatomic feasibility study. *J Hand Surg* 2003; 28A: 628 -32.
16. Alnot J Y. Traumatic brachial plexus lesions in the adult. Indications and results. *Hand Clinics* 1995; 11(4): 623 – 33.
17. Chuang D C C, Lee G W, Hashom F, Wei F C. Restoration of shoulder abduction nerve transfer in avulsed brachial plexus inj: Evaluation of 99 patients with various nerve transfers. *Plast Reconstr Surg* 1995; 96: 122 – 8.
18. Chuang D C C, Yeh M C, Wei F C. Intercostal nerve transfer of the musculocutaneous nerve in avulsed brachial plexus injuries: Evaluation of 66 patients.

- J Hand Surg* 1992; 17A: 822 – 8.
19. Minami M, Ishii S. Satisfactory elbow flexion in complete (preganglionic) brachial plexus injuries; produced by suture of third and fourth intercostals nerves to musculocutaneous nerve.
J Hand Surg 1987; 12A: 1114 – 8.
 20. Nagano A, Tsuyama N, Ochiai N, Hara T, Takshashi M. Direct nerve crossing with the intercostals nerve to treat avulsion injuries of the brachial plexus.
J Hand Surg 1989; 14A: 980 – 5.
 21. Narakas A O, Hentz V. Neurotization in brachial plexus injuries. Clinical orthopaedics and related research.
Clin Orthop 1988; 237: 43 – 56.
 22. Ogino T, Naito T. Intercostal nerve crossing to restore elbow flexion and sensibility of the hand for a root avulsion type of brachial plexus injury.
Microsurgery 1995; 16: 571 – 7.
 23. Brandt K E, Mac Kinnon S E. A technique for maximizing biceps recovery in brachial plexus reconstruction.
J Hand Surg 1993; 18A: 726 – 33.
 24. Gu Y D, Wu M M, Zhang Y L et al. Phrenic nerve transfer for brachial plexus motor neurotization.
Microsurgery 1989; 10: 287 – 9.
 25. Bartelli J A, Ghizoni M F. Reconstruction of C5 and C6 brachial plexus avulsion injury by multiple nerve transfers: Spinal accessory to suprascapular, ulnar fascicles to biceps branch and triceps long or lateral head branch to axillary nerve.
J Hand Surg 2004; 29A: 131 – 9.
 26. Terzis J K, Papakonstantinou K C. The surgical treatment of brachial plexus injuries in adults.
Plast Reconstr Surg 2000; 106: 1097 – 1122.
 27. Alnot JY, Rostoucher P, Oberlin C, Touan C. Les paralysies traumatiques C5 - C6 et C5 - C6 - C7 du plexus brachial de l'adulte par lesions supraclaviculaires.
Rev Chir Orthop 1998; 84: 113 – 23.
 28. Waikakul S, Wongtragul S, Vanadurongwan V. Restoration of elbow flexion in brachial plexus avulsion injury: comparing spinal accessory nerve transfer with intercostals nerve transfer.
J Hand Surg 1999; 24A: 571 – 7.
 29. Lurje A. Concerning surgical treatment of traumatic injury of upper division of the brachial plexus (Erb's type).
Ann Surg 1948; 127: 137.
 30. Gu Y D, Ma M K . Use of the phrenic nerve for brachial plexus reconstruction.
Clin Orthop 1996; 323: 119 – 21.
 31. Terzis J, Verkis M, Soucacos P. Outcomes of brachial plexus reconstruction in 204 patients with devastating paralysis.
Plast Reconstr Surg 1999; 104: 1214 – 40.
 32. Tung T H H, Mackinnon S E. Brachial plexus injuries.
Clin Plast Surg 2003; 30: 269 – 87.
 33. Mackinnon SE, Novak CB, Myckatyn TM, Tung TH. Results of reinnervation of the biceps and brachialis muscles with a double fascicular transfer for elbow flexion.
J Hand Surg 2005; 30A: 978-85.
 34. Liverneaux PA Diaz LC, Beaulieu JY, Durand S, Oberlin C. Preliminary results of double nerve transfer to restore elbow flexion in upper type brachial plexus lesion.
Plast Reconstr Surg 2006; 117: 915-9.
 35. Sungpet A, Suphachatwong C, Kawinwonggowit V, Patradul A. Transfer of a single fascicle from ulnar nerve to the biceps muscle after avulsions of the upper roots of the brachial plexus.
J Hand Surg 2000; 25B: 325-8.
 36. Leffert RD. Peripheral reconstruction of the upper limb following brachial plexus injury. In Leffert RD ed. Brachial plexus injuries. New York: Churchill Livingstone, 1985: 189 – 235.
 37. Warnor C W. Paralytic disorders. In: Canale ST ed. Campbell's Operative Orthopaedics, 9th ed. St Louis, M O: Mosby – Year Book, 1998: 3971 – 4052.
 38. Narakas A O. Thoughts on neurotization or nerve transfers in irreparable nerve lesions. In: Terzis J K ed. Microreconstruction of nerve injuries. Philadelphia Saunders. 1987: 447 – 454.
 39. Kawai H, Kawabata H, Masada K et al. Nerve repairs for traumatic brachial plexus palsy with root avulsion.
Clin Orthop 1988; 237: 75 – 86.
 40. Merrel G A, Barrie K A, Katz D L, Wolfe S W. Results of nerve transfer techniques for restoration of shoulder and elbow flexion in the context of a meta analysis of the English literature.
J Hand Surg 2001; 26A: 303 – 14.
 41. El-Gammal T A, Fathi N A. Outcome of surgical treatment of brachial plexus injuries using nerve grafting and nerve transfers.
J Reconstr Microsurg 2000; 18: 7 – 15.
 42. Zhao X, Hung L K, Zang G M, Lao J. Applied anatomy of the axillary nerve for selective neurotization of the deltoid muscle.
Clin Orthop 2001; 390: 244 – 51.
 43. Travill A A. Electromyographic study of the extensor apparatus of the forearm.
Anat Rec 1962; 144: 373 – 6.
 44. Hallock G G. The triceps muscle flap for axillary contracture release.
Ann Plast Surg 1998; 30: 359 – 62.
 45. Linn A Y T, Pereira B P, Kumar VP. The long head of the triceps brachii as a free functioning muscle transfer.
Plast Reconstr Surg 2001; 107: 1746 – 52.
 46. Leechavengvong S, Witoonchart K, Uerpairojkit C, Thuvasethakul P. Nerve transfer to deltoid muscles using the nerve to long head of triceps, part 2: A report of 7 cases.
J Hand Surg 2003; 28A: 633-8.
 47. Leechavengvongs S, Witoonchart K, Uerpairojkit C, Thuvasethakul P, Malungpaishrope K. Combined nerve transfers for C5 and C6 brachial plexus avulsion injury.
J Hand Surg 2006; 31A: 183-9.