

## Brain fungation

Gurpreet Singh MS, Deepak Singh Panwar MS, Mohammad Kaif MS, Vashdev Chandwani MS,  
Mazhar Husain M Ch, BK Ojha M Ch, Anil Chandra M Ch  
Department of Neurosurgery CSMMU (Erstwhile King George Medical University, Lucknow)

12 year old male child presented to the Department Of Neurosurgery at CSMMU, Lucknow 15 days after he head sustained accidental injury with an axe on his head. Major part of the left frontal lobe was fungating out from the compound injury. (Figure 1 A & B). Glasgow coma score was 15/15, with no neurological deficit. CT brain showed elevated bone flap with external brain herniation.

The child underwent debridement of the protruding brain matter with excision of a part of the left frontal bone. Postoperative period was uneventful and he was discharged without any neurological deficit 4 days later. On follow-up examination, scalp wound had healed well.

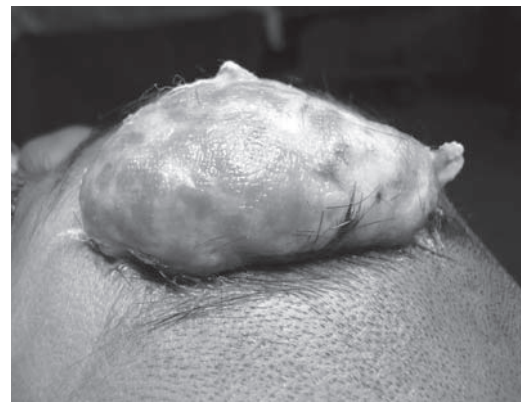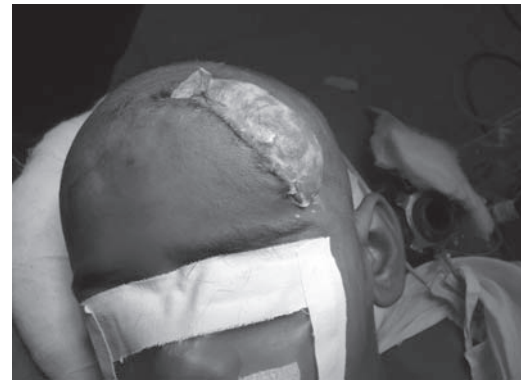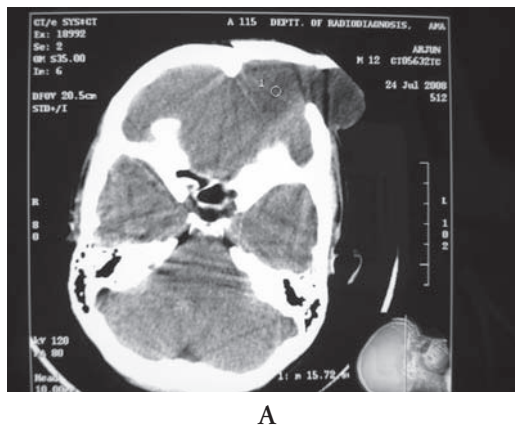


Fig 1 A, B & C: Fungating left frontal lobe.

*Address for Correspondence:*  
Dr. Gurpreet Singh MS,  
Department of Neurosurgery CSMMU  
(Erstwhile King George Medical University, Lucknow)