

## Bifrontal hyperacute extradural hematoma

Deepak Kumar Gupta M Ch, Karanjit Singh M Ch, AK Mahapatra M Ch

Department of Neurosurgery

All India Institute of Medical Sciences and associated Jaiprakash Narain Apex Trauma Center  
Ansari Nagar, New Delhi-110029

**Abstract :** Bifrontal extradural hematomas are uncommon. A 9 year old girl presented with head injury and inoperable intracranial lesion on early CT scan with normal neurological status. A repeat CT scan revealed development of hyperacute EDH without any further neurological worsening. Patient was operated and evacuation of hematoma was carried out. The patient made complete recovery. The present case report emphasizes the need of repeat CT scanning in all head injuries patients if first scanning is done within 6 hours of injury and discusses the bifrontal extradural hematomas.

### INTRODUCTION

The occurrence of bilateral extradural hematomas is an uncommon consequence of craniocerebral trauma and its incidence is variable in various studies ranging from 2-25%. Extradural hematomas are one of the modes of presentation of head injury. Usually, they are unilateral, often occurring in middle meningeal artery territory. Most of these cases demand urgent surgical intervention, aiming at their evacuation. In some cases, there is bilateral occurrence of these extradural hematomas. They are all the more dangerous unless quick evacuation is done. We studied these cases regarding their evaluation, location, clinical profile and outcome.

### CASE REPORT

A 9 yr old girl presented with history of fall from height 2 hours back and complained of headache and vomiting. On examination, she was fully conscious and oriented in time and place and antegrade posttraumatic amnesia of 15 min duration. Pulse rate was 76 per minute, blood pressure was 110/64 mm mercury and there were no other bony or soft tissue injuries. A NCCT scan of head was carried out which was diagnosed as bifrontal acute subdural collection (2 mm thick collection crossing the sutures line), the cisterns were well seen and there was no midline shift (Fig 1a). The patient was planned for conservative management (intravenous fluids, mannitol, antiepileptics with strict monitoring of vital parameters

and sensorium) in Intensive care unit and planned for repeat CT scan 6 –8 hours later as the first scan was carried out within 2 hours of injury. Repeat CT revealed bifrontal hyperacute extradural hematoma causing significant mass effect (Fig 1b). Patient was taken up for surgery immediately and bifrontal craniotomy was made. Intraoperatively, there was a large bifrontal extradural hematoma; there was no evidence of superior sagittal sinus injury. There was no subdural collection and the underlying brain was normal as seen after making a durotomy. Small durotomy opening was closed and dural hitch sutures were taken all around. Bone flap was replaced and secured locally. Scalp was closed in layers over a subgaleal drain. Patient made an uneventful recovery and was discharged 2 days postoperately. Postoperative CT showed complete evacuation of hematoma; mass effect was relieved (Fig 1c).

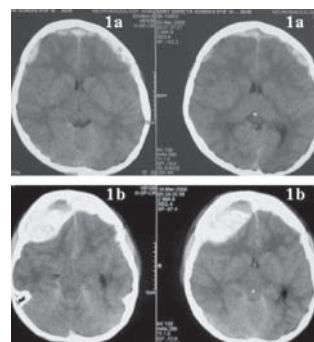


Fig 1

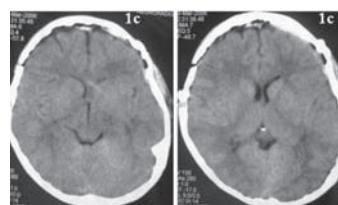


Fig 2

*Address for correspondence:*

Dr Deepak Kumar Gupta

Asst prof neurosurgery

AIIMS and JPN apex trauma centre.

Email : dlkg\_nsurgery@yahoo.co.in

## DISCUSSION

Incidence of bilateral extradural hematomas has been variably reported in various studies ranging from 2-25%<sup>2-6</sup>. Various theories have been put forward, regarding mechanism of occurrence of bilateral hematomas. It has been suggested that dura is detached from two locations by a single directed force. Stripping of dura can occur at site of impact by inbending or outbending of skull<sup>7</sup> or due to motion of skull, further aggravated by the negative intracranial pressure found at the antipode of the compression force<sup>8</sup>. In bilateral hematomas direction of force tends to be anteroposterior rather than lateral<sup>7</sup>, besides it can also occur due to extension of fracture line across midline, leading to bilateral extradural hematomas under fracture line, as was seen in one of our case.

It has also been suggested that the mechanism is same as in the coup and coup injuries<sup>9</sup>. The hematoma in present case was hyperdense with areas of hypodensity reflecting acute bleed. Computerized tomography (CT) scan of epidural hematomas usually show hyperdense biconvex shaped mass lesions. Isodense epidural hematomas are rare features with few cases reported in the neurosurgical literature. Different theories have been proposed to explain this atypical radiological finding, from low hematocrit values to dilution of the epidural blood due to mixture with cerebrospinal fluid (CSF). In the series of 151 patients reported by Tapiero et al., 40% presented hyperacute epidural hematomas but none of these were isodense with the brain<sup>10</sup>. The densities of subdural and epidural hematomas on CT scans are related to the attenuation values of the clot, as a function of the erythrocyte and hemoglobin protein concentration and in a lesser extent related to the iron content of the hemoglobin molecule<sup>11</sup>. Serum hemoglobin concentrations ranging from 9 to 11 g/dl have approximately the same density of the brain on CT scans. The clotting mechanisms are not essential for the CT attenuation, but clot retraction with separation of serum and absorption of fluid acts increasing the focal hemoglobin concentration and the density of acute clots<sup>1</sup>. The “hyperacute” extradural hematomas are usually hyperdense, with some small areas iso- or hypodensity within the lesion<sup>4</sup>. The possible causes of these combined densities are the presence of fresh, unclotted blood (which has a low attenuation coefficient), a low hematocrit or a mix of blood with CSF due to dural lacerations. Another

proposed mechanism is the continuous washout of the blood within the hematoma through the diploic veins after a skull fracture<sup>10</sup>. It is important to state that early diagnosis and treatment of extra-axial traumatic hematomas may result in an important decline in morbidity and mortality and the misdiagnosis is a potentially fatal situation.

Neurosurgeons should be aware of the above discussed condition, so prompt recognition and treatment can be achieved with better outcomes. All head injury patients should have repeat CT scanning especially if first CT scan is done within 6 hours of primary injury as head injury is a dynamic process with constant evolution.

## REFERENCES

1. Frank E, Berger TS, Tew JM.. Bilateral epidural hematomas. *Surg Neurol* 1982; 17 : 218-222.
2. Gallagher JP, Browder EJ. Extradural hematoma, experience with 167 patients. *J Neurosurg* 1968; 19: 1-12.
3. Jain SP, Kankanady VD. A study of 1500 cases of head injury in Delhi. *J Indian Med Assoc* 1969; 52: 204-11.
4. Lake PA, Pitts FW. Recent experience with epidural hematomas. *J Trauma* 1971; 11: 397-411.
5. McCarty CS, Homing ED, Weaver EN. Bilateral extradural hematoma. *J Neurosurg* 1948; 5: 88-90.
6. Dharker SR, Bhargava N. Bilateral epidural hematoma. *Acta Neurochir* 1991; 110: 29-32.
7. Bell. Quoted by Frank E, Berger TS, Jew JM. Bilateral epidural hematoma. *Surg Neurol* 1982; 17 : 218-22.
8. Gurdjian ES. Recent advances in the study of mechanism of impact of injury of the head. A summary. *Clin Neurol* 1972; 11: 1-43.
9. Subrahmanian MV, Rajendra Prasad GB, Rao BD. Bilateral extradural hematoma. *Br J Surg* 1975; 62: 397-400.
10. Tapiero B, Richer E, Laurent F, Guibert-Tranier F, Caille M. Post-traumatic extra-dural haematomas. *J Neuroradiol* 1984;11:213-26.
11. Greenberg J, Cohen WA, Cooper PR. The “hyperacute” extraaxial intracranial hematoma: computed tomographic findings and clinical significance. *Neurosurgery* 1985;17:48-56.