Indian Journal of Neurotrauma (IJNT)
2010, Vol. 7, No. 1, pp. 71-74

Dorsal approach in spinal accessory to suprascapular nerve transfer in brachial plexus injuries: technique details

PS Bhandari M Ch, **LP Sadhotra** M Ch, **P Bhargava** M Ch, **Manmohan Singh** M Ch, **MK Mukherjee** M Ch, **HS Bhatoe** M Ch*
Departments of Plastic and Reconstructive Surgery and *Neurosurgery
Armed Forces Medical College and Command Hospital (SC), Pune - 411040

Abstract: Transfer of spinal accessory nerve to suprascapular nerve is an acceptable technique in the restoration of shoulder functions in devastating brachial plexus injuries. Conventionally, these transfers have been performed by anterior approach with several modifications. With anterior approach dissection of spinal accessory nerve is tedious because nerve lies deep in the fatty tissue, rich in lymphatic vessels and blood vessels. Distal suprascapular nerve injuries may also be missed when plexus exploration and nerve transfer have been performed through anterior approach. We describe a new approach in the exposure of target nerves through a transverse incision placed over the scapular spine. Anatomic dissections were performed on 3 cadavers through dorsal approach. For this purpose a 12 to 15 cm long transverse incision was made over the spine of scapula. Trapezius muscle was detached from the spine and reflected upwards. Distal part of spinal accessory nerve was identified on the anterior surface of trapezius muscle. Suprascapular nerve was taped near the suprascapular notch. Both the nerves were in close vicinity and a direct transfer was possible. Thereafter this technique was clinically tried in 24 consecutive cases of brachial plexus injuries. In all of the cases, the spinal accessory and suprascapular nerves were distinctly located under direct vision and a direct coaptation of both the target nerves was possible. In 2 cases with C5 to T1 root avulsion injuries suprascapular nerve was also injured near the suprascapular notch. This approach allowed a direct transfer of spinal accessory to suprascapular nerve in a relatively safe zone and helped in the identification of other injuries of suprascapular nerve. Since distal part of spinal accessory nerve was used in transfer, function of upper trapezius remained intact.

Keywords: Brachial plexus injuries, Dorsal approach, Nerve transfer, Spinal accessory nerve, Suprascapular nerve

INTRODUCTION

Shoulder stabilization is a high priority in the treatment of patients with brachial plexus injuries. Suprascapular and axillary are the target nerves in achieving this goal. Experience has shown better results when suprascapular nerve is neurotized with spinal accessory nerve than using nerve grafts from a ruptured C5 root[1]. Today transfer of spinal accessory nerve to suprascapular nerve is a standard procedure, being performed through a transverse incision placed just above the clavicle. As pointed out by Bertelli [2], in severe traction injuries distal migration of the origin of suprascapular nerve can occur. Also in healed clavicular fractures with exorbitant callus formation, suprascapular nerve dissection can be difficult and risky. Suprascapular nerve may be injured in scapular neck fractures or avulsed near the suprascapular or spinoglenoid notch in extensive traction injuries [3]. For these difficult cases anterior approach is not suitable and exploration near the notch is highly justified. During anterior explorations of spinal accessory nerve few of its important branches to the upper trapezius muscle may be sacrificed while attempting to gain a sufficient length. Upper trapezius muscle has important function in the stabiliziation and elevation of scapula during shoulder abduction. Hence utmost care is needed in preserving its innervation. In dorsal or posterior transfers innervation of upper trapezius muscle remains intact and this is expected to improve overall function of the shoulder.

Address for correspondence :
Col PS Bhandari
Senior Adviser
Department of Plastic and Reconstructive Microsurgery
Armed Forces Medical College and Command Hospital
Pune – 411040. Maharashtra
Email : doctorbhandari@hotmail.com

PATIENTS AND METHODS

At the beginning anatomic dissections were performed in 3 cadavers placed in prone position. Through a transverse incision over the spine of scapula, trapezius muscle was detached and reflected upwards. Spinal accessory nerve was located on the anterior surface and dissected distally. With a strong downward traction on the upper border of supraspinatus muscle, suprascapular ligament over the notch was identified and sectioned

This document was downloaded for personal use only. Unauthorized distribution is strictly prohibited.

under vision. Suprascapular nerve was isolated proximal to the notch and mobilized. In all the 6 shoulders both the nerves were sizable and could be coapted without tension (Figs 1 & 2). After familiarization with local anatomy this approach was adopted in 24 patients with devastating brachial plexus injuries. The preoperative muscle power of the trapezius muscle was tested and graded by MRC scale. The probable locations of spinal accessory nerve and suprascapular nerve were marked on the back with patient in upright position (Fig 3). The anatomical landmarks considered were; angle of acromion, spine of scapula, medial border of scapula and midline of the back[4]. The spinal accessory nerve was marked at a point approximately 70% of the distance from the angle of acromion to the dorsal midline. The suprascapular nerve was marked at a point approximately 30% of the distance from angle of acromion to the medial

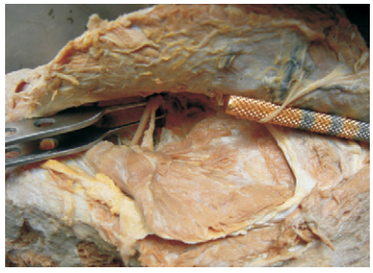

Fig 1 : Cadaveric dissection of spinal accessory and suprascapular nerves

Fig 2 : Direct coaptation of target nerves was feasible

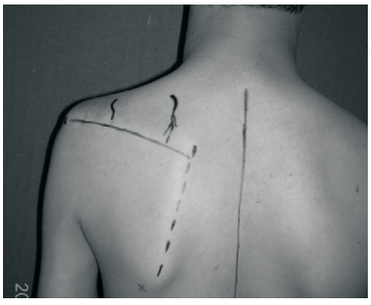

Fig 3 : Pre operative markings

border of scapula. These preoperative markings helped in localizing the nerves during surgery as in lying position bony landmarks are considerably changed.

Patients were operated in lateral position with head of the operating table raised by 40æ%. A 12 to 15 cm long incision was made parallel to the spine of scapula. The trapezius muscle was elevated from the scapular spine with sharp scissors and a plane was dissected between the trapezius and supraspinatus muscles (Fig 4). In some cases a thin fatty layer was observed between the two muscles. Trapezius muscle was gently lifted up revealing the neurovascular bundle on its undersurface. The spinal accessory nerve was isolated and taped. Contractions of the trapezius muscle were observed on its electrical stimulation. With the index finger upper border of scapula was palpaled for suprascapular notch. A strong downward traction on upper border of supraspinatus muscle revealed the glistening white suprascapular ligament overlying the notch (Fig 5). Suprascapular artery and vein were ligated superficial to the ligament. The ligament was sectioned while protecting the underlying suprascapular nerve. The nerve runs within the adipose tissue, sometime giving off a proximal branch to the

Fig 4 : Avascular plane between the trapezius and supraspinatus muscles

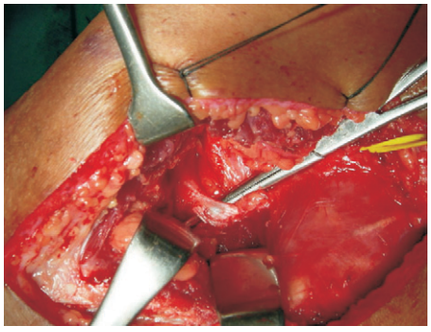

Fig 5 : Suprascapular ligament

This document was downloaded for personal use only. Unauthorized distribution is strictly prohibited.

supraspinatus muscle (Fig 6). The suprascapular nerve was mobilized proximally to allow sufficient length and coapted with distal spinal accessory nerve using 10-0 nylon suture (Fig 7). The trapezius muscle was sutured back to the spine of scapula with 3-0 polyglactin suture (Fig 8). Skin incision was closed without a drain (Fig 9).

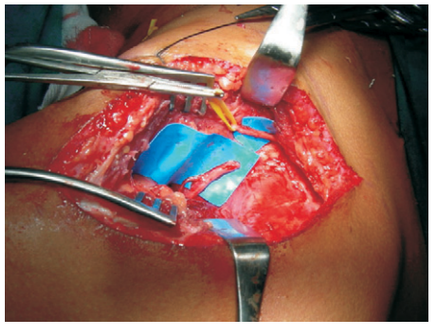

Fig 6 : Both spinal accessory and suprascapular nerves are in close proximity

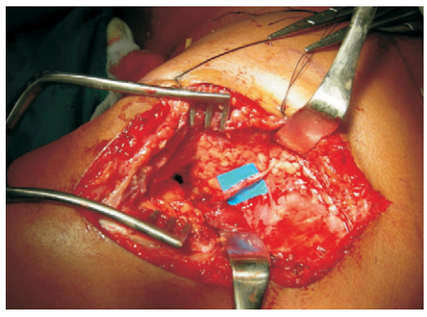

Fig 7 : Tension free coaptation of target nerves

Fig 8 : Trapezius muscle sutured back on to the scapular spine

Fig 9 : Incision closed without a drain

RESULTS

In all of the cases both spinal accessory and suprascapular nerves were identified under direct vision and their coaptation was tension free. Dissection was performed in a relatively avascular plane between the trapezius and supraspinatus muscles. This approach allowed dissection of spinal accessory nerve more distally preserving its important branches to the upper trapezius muscle. Also distal injuries of the suprascapular nerve were recognized in two cases and appropriately tackled. There were no post operative complications. Transverse scar over the scapular spine was initially hypertrophic but settled subsequently in 6 to 8 months of time. Clinically, dorsal transfer was effective in restoring shoulder functions. Examination of muscle power of the trapezius four months after surgery indicated normal power of the upper trapezius muscle. However middle part was weaker and lower part was completely paralyzed. Clinically patients could shrug almost normally.

DISCUSSION

Restoration of shoulder function is an important goal in the management of devastating brachial plexus injuries. Merrell et al reported that the best nerve transfer for restoration of shoulder abduction was the spinal accessory to suprascapular nerve transfer[5]. In the conventional anterior approach, one or two branches of accessory nerve innervating the upper part of trapezius muscle are spared. The nerve is sectioned closed to the clavicle and transferred to the suprascapular nerve. This approach may partially denervate the upper trapezius and will not be effective when supra scapular nerve is injured more distally. Nagano [6] pointed out that double or triple level injury in the suprascapular nerve is not infrequent and poor results for the infraspinatus muscle are due to

This document was downloaded for personal use only. Unauthorized distribution is strictly prohibited.

possible ruptures at the distal portion of the nerve. Mikami et al found a double lesion of the suprascapular nerve in seven out of twenty two patients[7]. In the present series of 24 patients we found distal injury to suprascapular nerve in two cases. These distal injuries to the suprascapular nerve are likely to be missed when nerves are explored only through the anterior approach.

Dorsal approach as described initially by Guan et al[8] and Bahm et al[9] is expected to overcome some of these drawbacks of the anterior transfers. Suprascapular nerve injuries near the notch can be effectively managed by direct transfer of distal spinal accessory nerve. This approach preserved the function of upper trapezius muscle. The nerve transfer being close to the target muscle produced an early reinnervation of the supraspinatus and infraspanatus muscles, as revealed best in the partial palsy group.

In conclusion transfer of spinal accessory nerve to the suprascapular nerve through dorsal scapular approach is a new and effective technique in restoring shoulder abduction and external rotation. This approach to the target nerves avoids nerve grafting in distal suprascapular nerve reconstruction. We consider this a standard approach in suprascapular neurotization in all grades of devastating brachial plexus injuries.

REFERENCES

1. Midha R. Nerve transfers for severe brachial plexus injuries: a review.
Neurosurg Focus 2004; 16: 1-10.

2. Bertelli JA, Ghizoni MF. Transfer of the accessory nerve to the suprascapular nerve in brachial plexus reconstruction.
J Hand Surg 2007; 32 A: 989-98.

3. Mikami Y, Nagano A, Ochiai N, Yamamoto S. Results of nerve grafting for injuries of the axillary and suprascapular nerves.
J Bone Joint Surg Br 1997; 79: 527-31.

4. Colbert, SH, Mackinnon S. Posterior approach for double nerve transfer for restoration of shoulder function in upper brachial plexus palsy.
Hand 2006; 1:71-7.

5. Merrell GA, Barrie KA, Katz DL, Wolfe SW. Results of nerve transfer techniques for restoration of shoulder and elbow function in the context of a meta-analysis of the English literature.
J Hand Surg Am 2001; 26:303-14.

6. Nagano A. Treatment of brachial Plexus Injury.
J Orthop Sci 1998; 3: 71-80.

7. Mikami Y, Nagano A, Ochiai N, Yamamoto S. Results of nerve grafting for injuries of the axillary and suprascapular nerves.
J Bone Joint Surg Br 1997; 79 : 527-31.

8. Guan SB, Chen DS, Fang YS, Cai PQ, Chen L, Peng F, et at. An anatomic study of descending branch of the spinal accessory nerve transfer for the repair of the suprascapular nerve to restore the abduction function of the shoulder through the dorsal approach.
Chin J Hand Surg (Chin) 2004; 20: 55-57.

9. Bahm J, Noaman H, Becker M. The Dorsal approach to the suprascapular nerve in neuromuscular reanimation for obstetric brachial plexus lesions.
Plast Reconstr Surg 2005; 115: 240-44.

This document was downloaded for personal use only. Unauthorized distribution is strictly prohibited.