

## Craniocerebral arrow injury with survival

K Sil DNB (Neurosurgery), S Basu FRCS, LN Tripathy FRCS

Medica Institute of Neurological Diseases, Medica Hospital,

127, Mukundapur, EM Bypass, Kolkata 700099 (WB)

**Abstract:** We report a rare case of a retained sports arrow penetrating the skull where the patient survived with minimal deficits.

**Keywords:** arrow; head injury; penetrating brain injury

A 44-year-old male from a neighbouring country was airlifted with an arrow injury to head sustained during an archery event on the same morning. He had nasal bleeding and vomiting. He was conscious and did not have seizures.

On examination four hours after the accident, the patient's GCS was 15/15. He had no perception of light in left eye, with dilated and non-reacting left pupil. Rear part of the arrow was sticking out behind the left ear the other end was palpable behind the right eyebrow. X-ray of skull revealed a large arrow embedded in skull from left posterior-temporal to right brow (Fig 1). He was taken up for surgery, and small left posterior temporal and right supraorbital craniectomies were made. The arrow could be dislodged and extracted *in toto* without significant bleeding or CSF leak. The patient was put on antibiotics and antiepileptics. A postoperative CT revealed arrow tract with pneumocephalus with no evidence of intracranial haemorrhage (Fig 2). MRI of brain revealed arrow tract and intact orbital nerves and muscles. VEP study did not show any activity. The patient was discharged after seven days without any complication. Three months later, he presented with CSF rhinorrhoea. CT and MRI Cisternography of brain showed leakage through a small hole in the anterior fossa base, which was repaired endoscopically. There was slight improvement of vision in left eye, with finger counting at one foot). There has been no change in his neurological status thereafter.

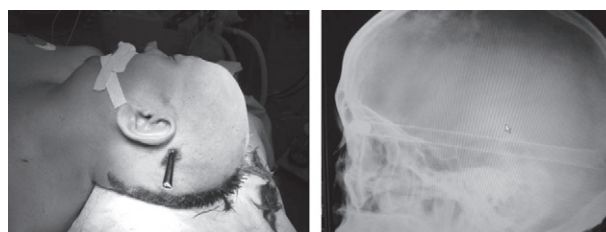


Fig 1: Pre-operative X-ray skull showing the arrow in situ

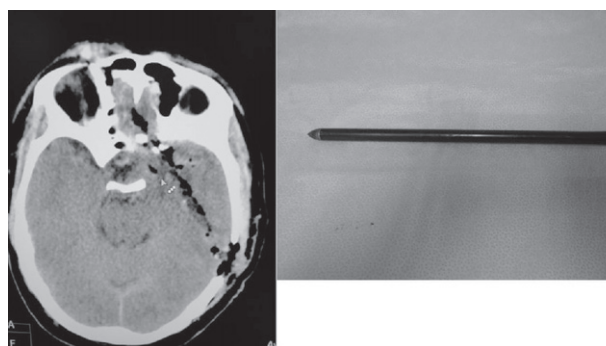


Fig 2: Post-operative CT scan showing the arrow tract

### DISCUSSION

Wikipedia has defined archery as the art, practice or skill of propelling arrows with the use of a bow. Archery has historically been used for hunting and combat. In modern times, however, it is a recreational and sports activity. Modern competitive target archery is usually practiced at outdoors from a range of 30–90 meters. Arrows of carbon fibre and composite materials (Easton X10 and A/C/E) are commonly used.

The huge ratio of length versus cross sectional area of an arrow coupled with high velocity makes it a powerful weapon. The penetrating wound of an arrow closely simulate a gun shot entry wound because of the extremely high velocity and sharp cutting edge of the arrow head<sup>1</sup>. However, the tip of a sports arrow is made as of the same diameter as of its shaft<sup>2</sup>. Such configuration of the

Address for correspondence:

K Sil

Medica Institute of Neurological Diseases, Medica Hospital

127, Mukundapur, EM Bypass, Kolkata 700099

Phone: (033) 66520000, Fax: (033) 66520171

Email: kaushik\_dr@hotmail.com

tip causes less tissue damage because it bores through the tissue instead of cutting. Therefore the damage is restricted only to its direct surroundings. Due to the elasticity of the tissues and the arrow lodged in the tract a tamponade effect may occur which prevents major bleeding<sup>3</sup>.

Our subject in this case was hit by a sports arrow shot by another competitor, while he was collecting his own arrows from the target. The high velocity missile struck his left posterior temporal bone, caused a depressed skull fracture and went in due to its kinetic energy. Inside the brain, it kept on its diagonal tract, went in front of the brain stem, cavernous sinus, optic chiasm and became lodged in the right orbital roof. The soft brain tissue absorbed the impact while the orbital roof prevented its exit outside. So, the arrow became immovable and tamponaded any major bleeding. The primary care physicians took the right decision of not trying to remove the arrow till the patient is stabilized. Once the neurosurgeon made the entry and exit wounds enlarged by doing small craniotomies, the arrow became loose. Fortunately, as the tip of the sports arrow was not larger than the shaft, it could easily be dislodged by gentle manipulation without any twists and turns. The collapsing brain in the arrow tract and the resulting edema prevented any blood or CSF leak. This mechanism probably explained why the patient was conscious and capacitated. The left optic nerve injury was probably due to brushing of the speeding arrow across the chiasm on its way to the right. Delayed CSF leak from the skull base lesion

was evident once the brain edema subsided<sup>4</sup>. Such nonfatal transcranial penetrating arrow injuries, though rare has been described previously<sup>5</sup>.

## CONCLUSION

This rare form of civilian injury should be treated with diligence. The arrow should be kept in wound, secured against displacement during transport and only removed in a proper setup. Neurological and vascular complications may thus be minimized. Delayed complications like pseudoaneurysm, sepsis and CSF leak should be anticipated.

## REFERENCES

1. Ogunleye AOA, Adeley AO, Flyodele KJ, Usman MO, Shakunbi MT. Arrow injury to skull base. *WAJM* 2004; 23: 94-6.
2. Karger B, Sudhues H, Beat P, Kneubuehl MS, Brinkmann B. Experimental arrow wounds; ballistics and traumatology. *J Trauma* 1998; 45: 495-501.
3. Krukemeyer MG, Grellner W, Gehlke G, Koops E, Puschel K. Survived crossbow injuries. *Am J Forens Med Path* 2006;3: 274-6.
4. Katrijn dJ, Dinska D, Rodrigo S, Ozkan O, Johan WMVG, Luc B et al. "William Tell" Injury. MDCT of an arrow through the head. *AJR* 2004; 182:1551-3.
5. Paramhans D, Shukla S, Batra A, Mathew R. Successful removal of an implanted metallic arrowhead penetrating up to brainstem. *J Emerg Trauma Shock* 2010; 3: 303.