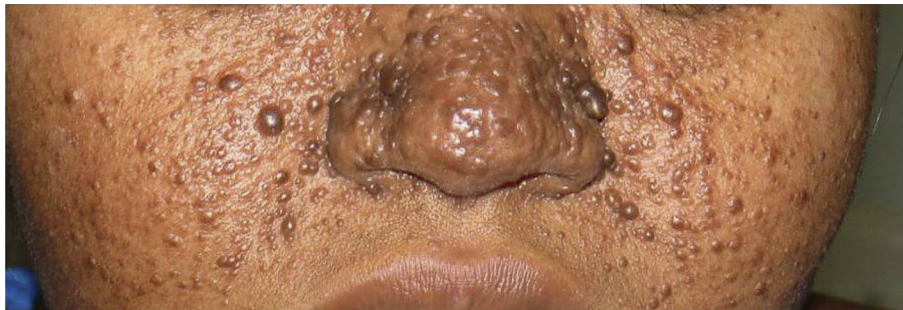


Available online at www.sciencedirect.com**ScienceDirect**journal homepage: <http://www.journals.elsevier.com/international-journal-of-epilepsy>

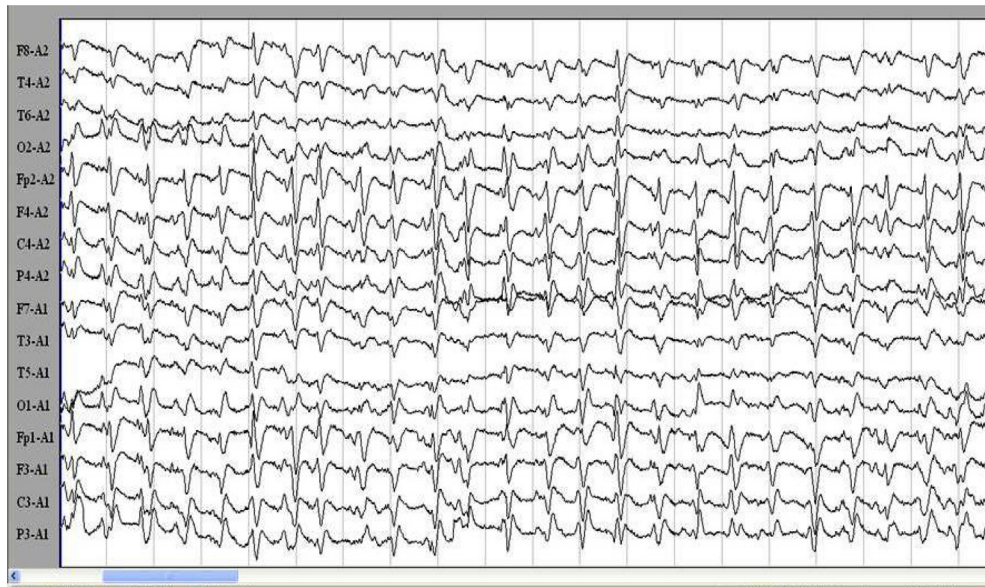MCQs

Epilepsy Quiz

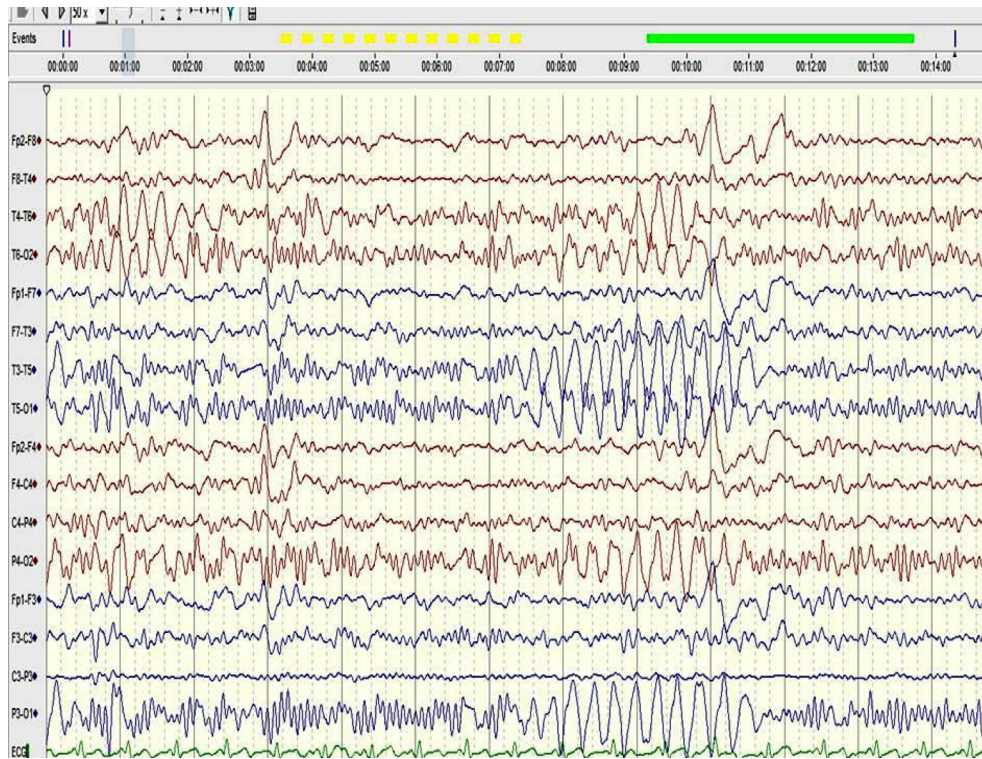
- A 25 year old female patient is suffering from Autosomal dominant epilepsy. Identify the cutaneous lesion.
 - Shagreen Patches
 - Facial Angio fibroma
 - Facial Capillary angioma
 - Epidermal nevi
- With the new practical definition of “Epilepsy” which of the following statement is incorrect.
 - The recurrence risk of seizure should be at least 60% after two unprovoked seizures occurring over the next 10 years to classify as Epilepsy.
 - A 35 year old male with history of two unprovoked seizures spread one year apart is diagnosed as epilepsy



- Which of the following Antiepileptic drug is relatively safer to be used in a patient with porphyria?
 - Lamotrigine
 - Clobazam
 - Carbamazepine
 - Phenobarbitone
- While treating a pregnant lady with epilepsy, the most profound decline in serum concentration of which AED is seen?
 - Valproate
 - Levetiracetam
 - Lamotrigine
 - Carbamazepine
- A patient with left MCA infarct has seizures after 2 months of stroke is diagnosed as epilepsy
- A 22 year male with history of facial twitching in night till age 14. His EEG demonstrated centro temporal spikes. He is off medication since age 16. He is considered to have active epilepsy.
- Level of evidence for use of antiepileptic drug for elderly patients with partial seizures is for
 - Valproic Acid
 - Levetiracetam
 - Lamotrigine
 - Zonisamide



6. 60 year female with 3 month history of confusion and rapid progressive cognitive decline. The clinical picture and EEG pattern is suggestive of
 - A) HSV encephalitis
 - B) SSEP
 - C) CJD
 - D) Brain tumor
7. Investigators have identified CYP 2C9 mutation as genetic factors for which antiepileptic drug induced severe cutaneous drug reactions,
 - A) Carbamazepine
 - B) Lamotrigine
 - C) Phenytoin
 - D) Valproic Acid
8. Which of the following statements is false?
 - A) Pregnant women on AED should undergo a serum alfa fetoprotein and level II Ultrasound at 24 weeks of gestation to rule out NTD's.
 - B) Hematological dysfunction with Valproate usually occurs with serum VPA levels greater than 100µg/ml.
 - C) Lamotrigine has been shown to worsen seizures in severe myoclonic epilepsy.
 - D) Tiagabine has been noted to cause status epilepticus or new-onset seizures in persons without a history of epilepsy
9. Visual auras are common in migraine with aura and visual occipital lobe seizures occasionally making it difficult to differentiate them clinically. Which of the following statement is incorrect?
 - A) Elementary visual hallucinations of occipital seizures are prolonged, slowly developing and last for hours.
 - B) Elementary visual hallucinations of occipital seizures are predominantly colored and circular.
 - C) Visual aura of migraine consists mainly of achromatic zigzag linear patterns, starts in the center of the visual field, it gradually progresses over > 4 min usually lasting <30 min.
 - D) Visual aura of migraine often leaves a scotoma.
10. A 10 year boy presented with brief losses of consciousness with EEG showing generalized 3-Hz spike-wave discharges



with good therapeutic response on medication. His EEG also showed this pattern which is suggestive of

- A) Encephalopathy
- B) Posterior slow waves.
- C) OIRDA
- D) TIRDA

[http://dx.doi.org/10.1016/S2213-6320\(15\)00021-4](http://dx.doi.org/10.1016/S2213-6320(15)00021-4)

Dr Bindu Menon,
 M.D.(Med.), D.M.(Neuro), DNB.(Neuro), PGDCN (Neuro),
 (London), FRCP (Edinburgh)
 Senior Consultant Neurologist, Simhapuri Hospital, Nellore,
 Andhra Pradesh.

bneuro_5@rediffmail.com, +919866223905.