

Teaching EEG 5: A familiar EEG pattern with atypical morphology

Sarma G.R.K.^a, Norman So^b, Soheyl Noachtar^c, Elizabeth V.T.^d

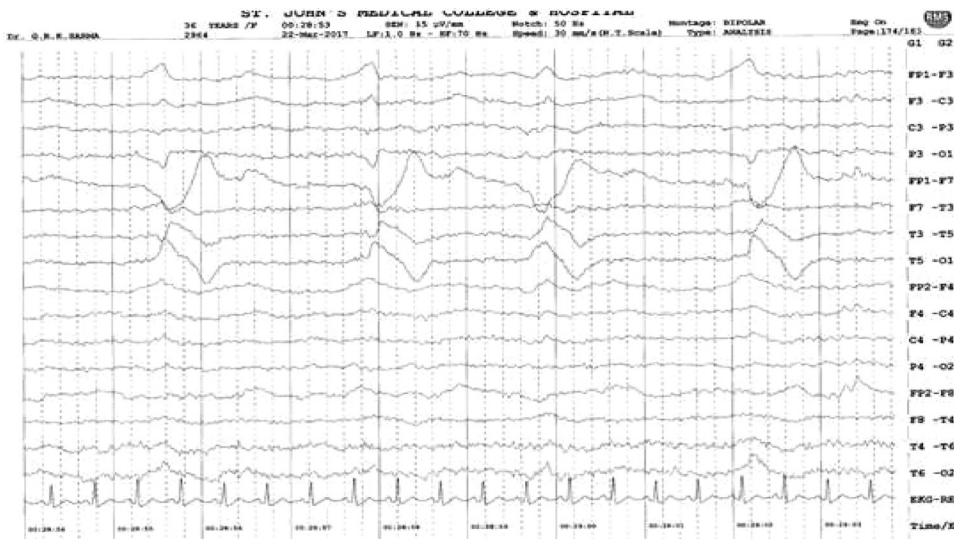
^a Professor of Neurology, St. John's Medical College Hospital, Bengaluru, India

^b Clinical Professor, Department of Neurology, University of Washington Medical Center, USA

^c Professor & Head, Epilepsy Center, Department of Neurology, University of Munich, Germany

^d EEG Technologist, St. John's Medical College Hospital, Bengaluru, India

A 36-year-old lady presented with history of fever 2 weeks ago, followed by confused behavior, hallucinations and recurrent episodes of seizures. She lapsed in to coma from 5th day of illness. Her MRI showed left temporal, frontal and insular T2 hyperintense signal changes with areas of blooming on gradient ECHO MRI sequence. Her EEG done on 17th day of illness is shown in figure:



Questions

1. What is the most likely clinical diagnosis?
2. What is the typical EEG finding expected in this condition?
3. Describe the activity in the left temporal chain? How is it different from the expected activity in this patient?
4. Why is the observed activity different from the expected activity in this patient?

Answers

1. The clinical diagnosis in this patient is encephalitis, most likely, herpes simplex encephalitis viral encephalitis (HSVE). The usual differential diagnosis is limbic encephalitis, but involvement of insula and frontal cortex, with hemorrhagic transformation strongly supports the diagnosis of HSVE.
2. The typical EEG finding described in HSVE is PLEDs (periodic lateralized epileptiform discharges), which are now called LPDs (lateralized periodic discharges). These are surface-negative bi-, tri-, or polyphasic discharges consisting of spike, sharp, polyspike components, variably with slow-wave complexes lasting 60–600 ms (mean 200 ms), of 50–150 μ V (sometimes 300 μ V) in amplitude, usually occur at 0.5–2.0 Hz (ranging from 0.2 to 3 Hz). They must last a minimum of 10 min, and typically, the entirety of a 20-min recording.¹

Depending on their context, PLEDs may represent different points along an ictal–interictal continuum.² The current term LPDs acknowledges this uncertainty of epileptogenic potential of these discharges.

3. In the given EEG trace, large amplitude (300 μ V) periodic (0.4–0.5 Hz) slow wave discharges are seen in the left temporal chain of electrodes with broad phase reversal across F7 and T3. However, they differ from the classical description of PLEDs conspicuous by the absence of sharp/spike component and by their longer duration (600–800 ms).
4. Though a significant work has been recently published on PLEDs/LPDS, including various subtypes and their epileptogenic potential, less attention has been paid to their evolution over a course of time. Such less than classical morphology of PLEDs/LPDs as in this patient can occur towards the later stages of illness as they dwindle into polymorphic slow waves.³ Over a period of time, the discharges become less frequent and longer in duration. In addition they became less complex in wave form, evolving to a paroxysmal delta and then theta waves before eventually disappearing.³ The given EEG was done performed on 17th day of illness and this may account for the atypical appearance of the PLEDs/LPDs.

Learning point: *The morphology of classic EEG patterns may sometimes appear unusual as it evolves over time. This awareness minimizes EEG misinterpretation.*

References

1. Chatrian GE, Shaw CM, Leffman H. The significance of periodic lateralized epileptiform discharges in EEG: an electrographic, clinical and pathological study. *Electroencephal Clin Neurophysiol.* 1964;17:177–193.
2. Chong DJ, Hirsch. Which EEG patterns warrant treatment in the critically ill? Reviewing the evidence for treatment of periodic epileptiform discharges and related patterns. *J Clin Neurophysiol.* 2005;22:79–91.
3. Schwartz MS, Prior PF, Scott DF. The occurrence and evolution in the EEG of a lateralized periodic phenomenon. *Brain.* 1973;96:613–622.