

Teaching EEG 3: Assessing the distribution of a paroxysmal activity

G.R.K. Sarma^a, N. So^b

^a Professor of Neurology, St. John's Medical College Hospital, Bengaluru, India

^b Clinical Professor, Department of Neurology and Neurophysiology, Washington University Medical Center, Washington, USA

Questions:

1. The patient is a 7 year old boy. Describe the paroxysmal activity noted in 4th, 6th and 7th seconds of this page.
2. What features warrant a re-assessment of its distribution?
3. Which other montage will be helpful in this situation?

Answers:

1. In this Cz referential montage, there is an intermittent, 5 Hz slow wave activity in 4th, 6th and 7th seconds. On the first look, it appears to have a generalized distribution.

2. There are certain features that warrant a re-assessment of its distribution:

- a. The waveforms in all the involved leads are monomorphic and “in-phase”. In a referential montage, if there is an in-phase, monomorphic activity in most leads, a contamination from the reference electrode needs to be considered.
- b. The slow wave activity is seen in all the leads except C4, P4. A generalized slow wave activity without involving C4 and P4 is not physiologically plausible and may in fact suggest that C4, P4 and Cz are relatively equipotential.

3. To resolve this issue, a longitudinal bipolar montage was chosen (Fig. 2). In this montage, a slow wave activity involving only the

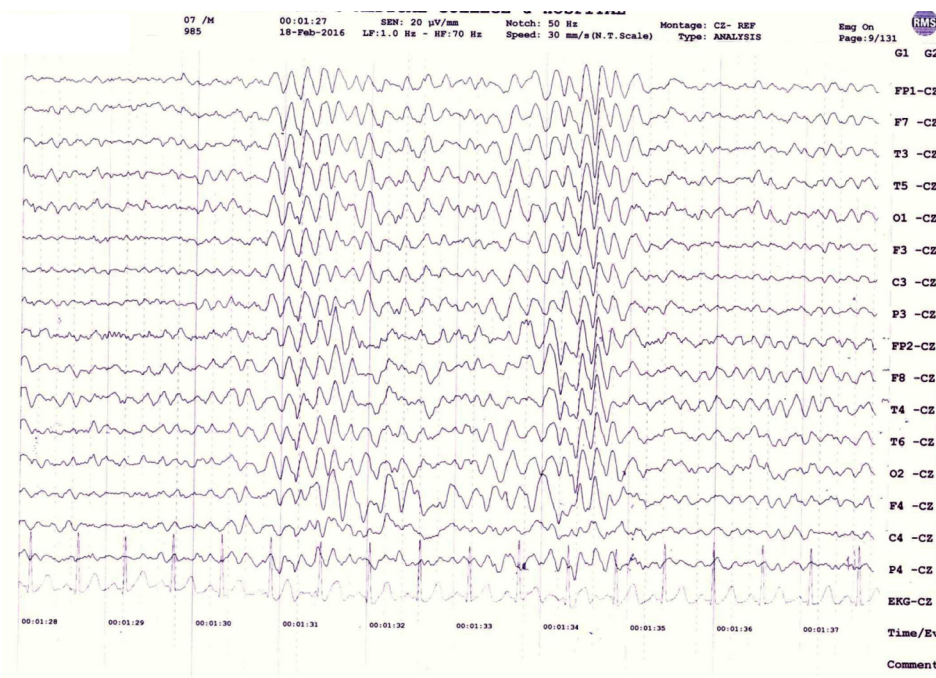


Fig. 1. Cz referential montage showing the paroxysmal activity in 4th, 6th and 7th seconds.

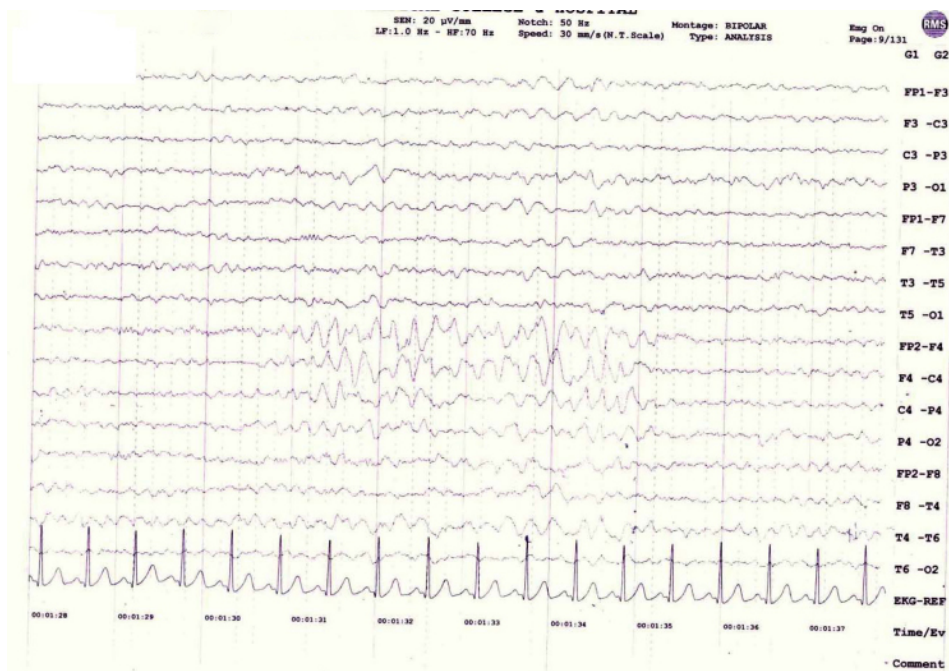


Fig. 2. Longitudinal bipolar montage showing the restricted distribution of the intermittent slow wave activity.

right frontocentral regions is obvious. In the Cz referential montage, the Cz electrode was involved in this slow wave activity and contaminated all the leads except C4 and P4 which were equipotential to Cz.

Learning Point: In a referential montage, a generalized, in-phase, monomorphic activity is likely to be due to a contaminated reference electrode.

Acknowledgements

We thank Mrs. Elizabeth VT, EEG technologist at St. John's medical college, Bengaluru for performing the EEG.