


Available online at www.sciencedirect.com

SciVerse ScienceDirect

journal homepage: www.elsevier.com/locate/ijnt

Original article

Cervical spine injury with bilateral facet dislocation, surgical treatment and outcome analysis: A prospective study of 19 cases

Siddhartha S. Sahoo, Deepak Gupta*, A.K. Mahapatra

All India Institute of Medical Sciences and Jai Prakash Narayan Apex Trauma Centre, New Delhi 110029, India

ARTICLE INFO

Article history:

Received 13 February 2012

Accepted 1 April 2012

Available online 23 April 2012

Keywords:

Facet dislocation

Spinal cord injury

Anterior approach

ABSTRACT

Background: Bilateral cervical facet dislocations present with severe neurological deficits and an unstable spine. Aim of this study was to evaluate the surgical outcome in cervical spine injury with bilateral facet dislocations.

Methods: There were 19 cases of cervical bilateral facet dislocations from Jan 2010 to March 2011. The SLIC scoring was used for surgical decision. Anterior approach with decompression and fixation was done. Postoperative CT/neurological outcome assessment postoperatively/follow up visits.

Results: Mean age was 38 years (range 11–60 years), (M:F 18:1). Fall from height noted in 80% ($n = 15$), road traffic accident in 10% ($n = 2$) and two were domestic violence related. High velocity injury seen in 16% ($n = 3$) and low velocity injury in 84% ($n = 16$). ASIA A noted in majority, one patient had no neurological deficit (ASIA E). C5/6 and C 6/7 were most common injured segments (80%). Disc compression noted in 58% ($n = 11$) patients. Mean SLIC score was 8 (range 6–9) and the mean time from injury to surgery 9 days (range 1–50 days). Mean hospital stay 28 days (range 5–100 days). Realignment and reduction of facets achieved in 84% ($n = 16$) patients. Improvement of ASIA impairment score by >1 score noted in 37% (7/19) patients, mortality was 37% (7/19). Preoperative neurological status was the only significant determinant of neurological outcome ($p = 0.009$).

Conclusion: Bilateral facet dislocations are mostly low velocity injuries related and have poor neurological outcome. Anterior only approach with peroperative reduction of dislocated facets is recommended to stabilize the spine.

Copyright © 2012, Neurotrauma Society of India. All rights reserved.

1. Introduction

Bilateral facet dislocation is the most severe form of cervical spine injury seen in about 5% of cases.¹ Facet dislocation is a hyperflexion-distraction injury with involvement of both the anterior and posterior columns. There is disruption of both the longitudinal ligaments, interspinous ligaments,

ligamentum flavum, the apophyseal joint ligaments and the annulus fibrosus. The vertebral body translation is usually $>50\%$ of the vertebral body width. The inferior facets of the superior vertebra move forward over the superior facets of the inferior vertebra due to hyperflexion. Fracture of facets, laminae and spinous processes may be coexistent. These injuries are inherently unstable. Most of the patients present

* Corresponding author. Department of Neurosurgery, CN Centre, 720, AIIMS, New Delhi 110029, India.

E-mail address: drdeepakgupta@gmail.com (D. Gupta).

0973-0508/\$ – see front matter Copyright © 2012, Neurotrauma Society of India. All rights reserved.

doi:10.1016/j.ijnt.2012.04.002

with severe neurological deficits with cord or root injury. Treatment is not standardized. The consensus is the need of reduction and stabilization to optimize the chances of neurological recovery. Many questions remain to be answered: whether early reduction facilitates neurological recovery? Whether closed reduction should be tried in all patients? In case of open reduction whether combined anterior and posterior approach serves well than only anterior approach? Available literature finds proponents of both the schools of thought. No class I evidence is available.

Our study aims at studying the management of cervical spine injury with bilateral facet dislocation at an apex trauma centre in India focusing on the above issues and the neurological outcome.

2. Methods

A prospective study of 19 cases of cervical spine injury with bilateral facet dislocation who were operated at level I apex trauma centre from Jan 2010 to March 2011. Patients with severe pulmonary complications who succumbed early and

patients with concomitant severe head injury were excluded from the study. Cervical spine X-ray, CT scan with coronal and sagittal reconstruction and MRI of the cervical spine were done in all patients (Fig. 1). The patients were studied to assign all three components of the SLIC score² viz., morphology, discoligamentous complex (DLC) injury and neurological status. The neurological status was also recorded as per ASIA impairment scale. Anterior approach with decompression and fixation was done in all patients. Decompression was done by Corpectomy +/- Discectomy as per the imaging findings. Expandable cage or autologous iliac crest bone graft was used for fusion. After discectomy the vertebrae were distracted with traction already in place with weight about 2.5 kg per level and maneuvered for reduction of the facets. Plate with screw was used for fixation after reduction. Postoperative CT with reconstruction was done in all patients (Fig. 2). No postoperative external immobilization was used. Patients were mobilized early. Follow up was on OPD basis. The neurological outcome in terms of improvement of ASIA impairment scale was noted both postoperatively and on follow up. The successful reduction of facets was studied for any association with young age, low velocity of injury & early surgery (≤ 48 h)

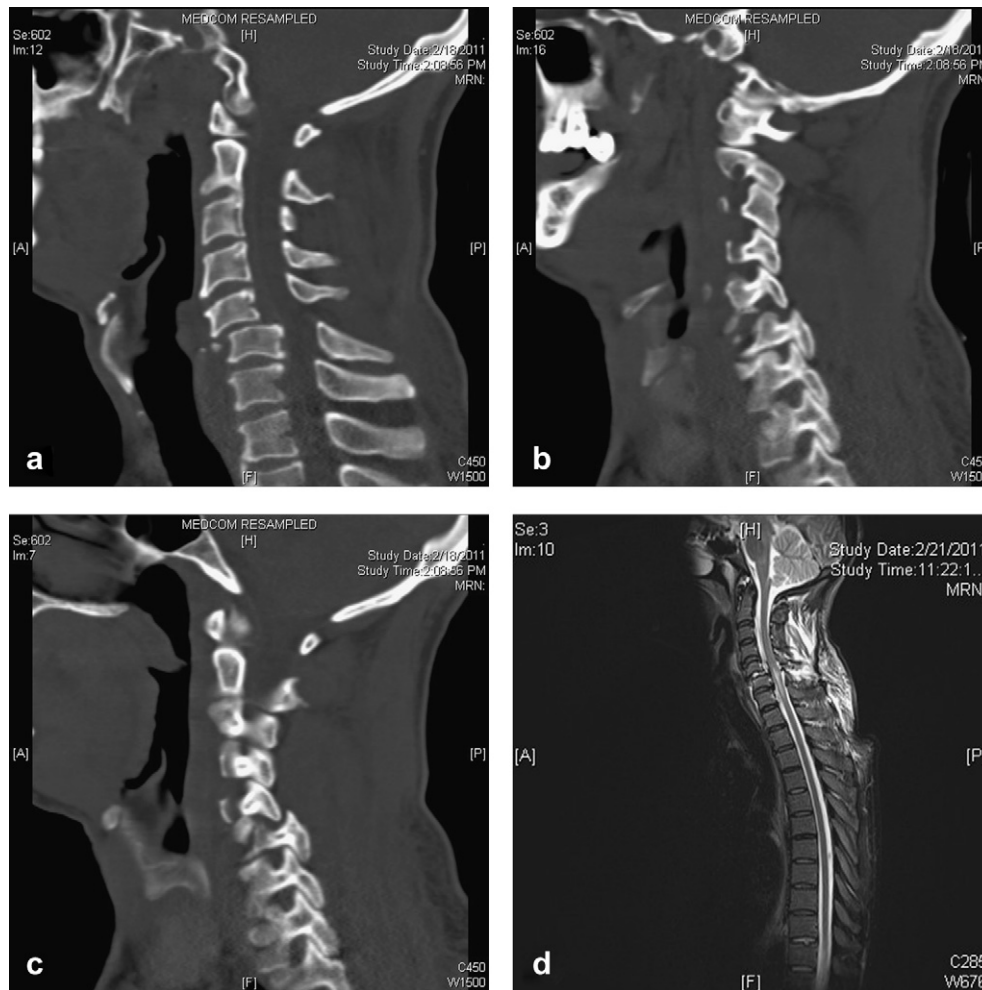


Fig. 1 – Preoperative imaging. a. Sagittal CT scan images showing anterolisthesis of C5 over C6. **b & c.** Right and Left parasagittal sections showing bilateral facet dislocations. **d.** Saggittal MRI T2W images showing thecal sac compression with cord signal changes.

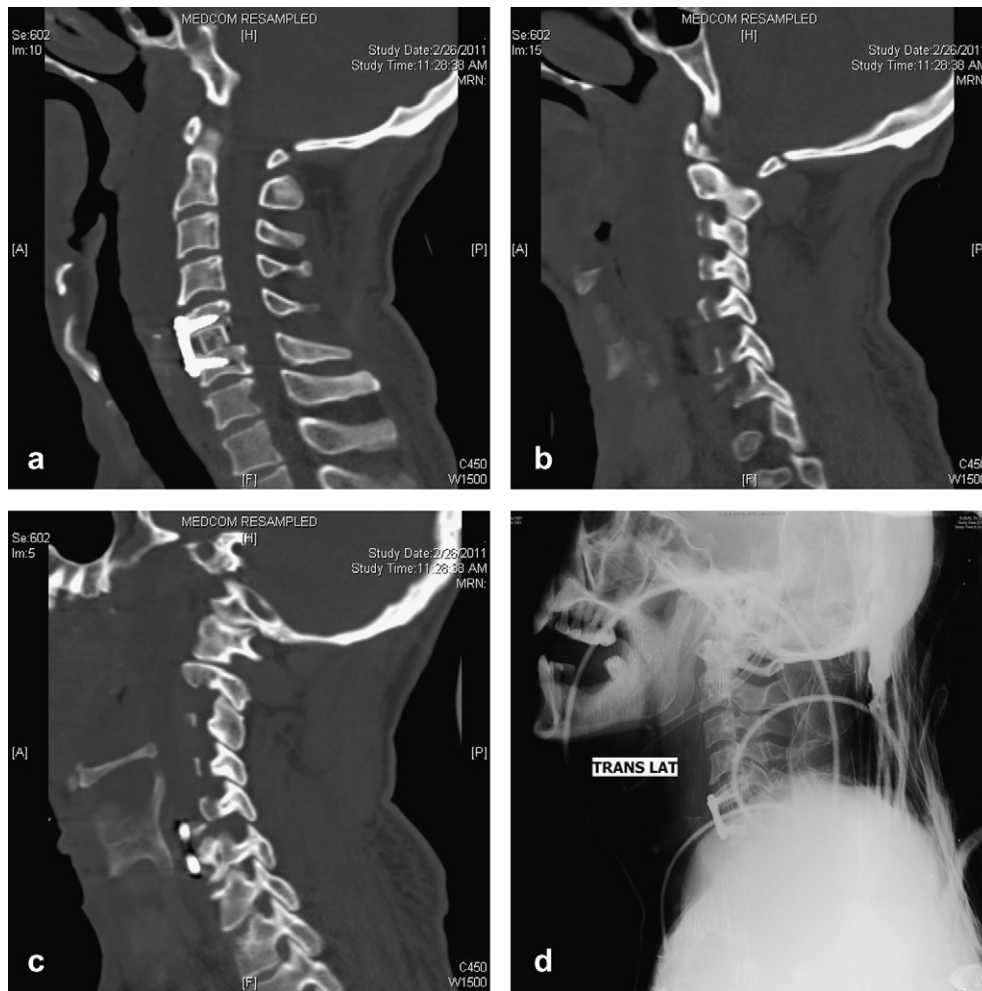

Fig. 2 – Postoperative images. a. Sagittal NCCT showing C5/C6 Discectomy with PEEK cage and plate with restoration of alignment. b & c. Reduction of dislocated facets bilaterally. d. X-ray cervical spine lateral view.

by Chi-square tests. The neurological outcome was also studied for any association with above factors and the preoperative neurological status in addition. SPSS 16 was used for statistical analysis.

3. Results

Total no. of patients was 19 with mean age 38 years (range 11–60 years); there were 18 males and one female. Fall from height was the mechanism of injury in 80% ($n = 15$), with road traffic accident in 10% ($n = 2$). One patient was victim of assault and another with muffler around neck getting entrapped in a sugarcane juice maker. High velocity injury was seen in 16% ($n = 3$) as compared to low velocity injury in 84% ($n = 16$). Eighty percent of patients ($n = 15$) had complete spinal cord injury (ASIA A) and 15% had incomplete spinal cord injury whereas one patient had no neurological deficit (ASIA E). C5-6 and C6-7 were the most common injured segments (80%) whereas C4-5 was involved in 15% and C7–D1 in 5% of cases. Traumatic disc herniation causing significant compression on thecal sac was present in 58% ($n = 11$) cases. The morphology component of SLIC score was translation /

rotation (score 4) in 68% ($n = 13$) and distraction (score 3) in others ($n = 6$). The DLC was disrupted in all (score 2). The neurological status was scored 2 for complete injury and a score of 3 for incomplete injury with a score of 1 added for continuous cord compression in the presence of neurodeficit. Mean SLIC score was 8 (range 6–9). The mean interval from time of injury to surgery was 9 days (range 1–50 days). The mean hospital stay was 28 days (range 5–100 days). Realignment and reduction of facets achieved in 84% ($n = 16$) patients. Mean follow-up was 6 months. Improvement of ASIA impairment score by at least one level was seen in 37% (7/19) patients. Three patients with incomplete cord injury improved whereas three patients with ASIA A were sensory incomplete (ASIA B) on follow up. Overall Mortality was 37% (7/19) whereas in-hospital mortality was 26% (5/19). The details of all 19 patients are described in Table 1.

4. Discussion

Bilateral facet dislocation is a hyperflexion-distraction injury associated with complete spinal cord injury in 65–87% cases, incomplete injury in 13–25% and less than 10% are intact.^{1,3}

Table 1 – Case summary.

S.N	Level	ASIA preop	SLIC score	Disc herniation	Reduction of facets	ASIA score at F/U
1	C6-7	A	9	No	Yes	A
2	C6-7	A	9	No	Yes	B
3	C5-6	D	7	Yes	Yes	E
4	C4-5	A	9	No	Yes	A
5	C6-7	A	9	No	Yes	Death
6	C5-6	A	9	Yes	No	Death
7	C7-D1	A	9	Yes	Yes	A
8	C6-7	B	8	No	Yes	C
9	C6-7	E	7	No	Yes	E
10	C5-6	A	7	No	Yes	A
11	C6-7	B	8	Yes	Yes	C
12	C4-5	A	8	Yes	Yes	Death
13	C4-5	A	8	Yes	Yes	A
14	C5-6	A	7	Yes	Yes	Death
15	C6-7	A	8	Yes	No	Death
16	C6-7	A	8	Yes	No	Death
17	C5-6	A	7	Yes	Yes	Death
18	C5-6	A	8	No	Yes	C
19	C5-6	A	8	Yes	Yes	B

Anatomically the inferior articular processes of the upper vertebra moves forward over the superior articular facets of the lower vertebra because of severe hyperflexion. Adjacent fractures of the vertebral body, facet, lamina, pedicle, or transverse or spinous process have been found in 38.5%–60% of patients.⁴

Fall from height was the cause in majority of the patients contrary to motor vehicle accidents in published literature.^{1,3} This discrepancy can be explained by the poor domestic environment and may be the higher mortality among the road traffic accident victims who fail to reach a tertiary care centre with inadequate and improper transport facility from site to healthcare facility.

C5-6 and C6-7 are the most common involved segments.^{1,3} A combination of lower height, smaller anteroposterior diameter of the superior facet, and a more horizontally oriented superior facet at C6 and C7 levels in vivo may explain the predilection of translation relative to one another in the lower cervical spine.⁵

The goal of treatment is reduction and stabilization for maximum neurological recovery as this injury is inherently unstable with both bony and ligamentous injury and disruption of spinal columns. The need of MRI before reduction is debated since 1990s. It is generally recommended that a pre-reduction MRI is prudent to get an understanding of the status of the spinal cord and any potentially offending soft-tissue or bony structures placing the spinal cord at risk.⁶ In

our series MRI was done in all patients prior to attempted reduction. Joon Y Lee et al has reported the incidence of permanent neurological complications after closed reduction in awake patients was approximately 1%, whereas transient injury occurred in 2% to 4%.⁶ Yu Ze-sheng et al reported a success rate of 88% in dislocation with bilateral locked facet and 15.4% in unilateral locked facets by closed reduction.⁷ In our study group open reduction was done in all patients. Our procedure was on the basis of Stellerman's algorithm.⁸ Whether open reduction should be the first resort or tried only after failure of attempted closed reduction with increasing weight of traction remains a topic of debate. Post-operative CT scans revealed achievement of reduction of facets bilaterally in 84% (n = 16) cases. The association of preoperative factors like age \leq 40 years, low velocity injury (fall from height) & interval of \leq 48 h from injury to surgery with successful reduction of facets was not statistically significant ($p > 0.05$) (Table 2).

The SLIC score was used as a guiding principle.² Invariably all patients had complete disruption of the discoligamentous complex (score 2). The morphological score varied between 3 for distraction injury with dislocation without facet fracture and translation/rotation and score of 4 for translation or rotation with dislocation of facets. The neurological status score varied as per complete/incomplete spinal cord injury. All patients were surgical candidates with a minimum score of 6.

Table 2 – Association between reduction of facets and preoperative factors, neurological improvement and mortality.

		Facets reduced n = 16 (84%)	Facets not reduced n = 3 (16%)	p Value
1	Age < 40	10 (83%)	2 (17%)	0.891
2	Fall	12 (80%)	3 (20%)	0.330
3	Interval \leq 48 h	4 (80%)	1 (20%)	0.764
4	Improvement in ASIA score	7 (100%)	0	0.149
5	Mortality	6 (85%)	1 (15%)	0.891

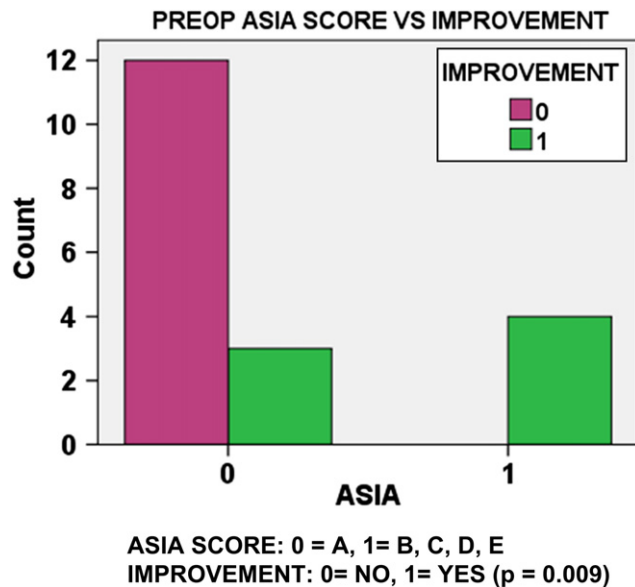


Fig. 3 – Preoperative ASIA score vs neurological improvement.

The surgical approach is not standardized. Combined anterior and posterior fixation is superior in terms of stability at the cost of morbidity. Anterior fixation/fusion alone for bilateral dislocation increases the fusion time with no difference in the degree of neurological recovery.⁹ Stellerman recommended a posterior facetectomy and reduction with fusion if reduction failed after an anterior discectomy and monitored distraction.⁸ In our series anterior decompression and fusion was performed after successful reduction of facets. The three patients where facet reduction was not achieved by anterior approach alone, a posterior reduction and fixation could not be executed due to patient factors like haemodynamic instability.

In most series only limited root function recovery is seen with no improvement below the level of injury^{1,2}. Overall improvement in ASIA score was seen in 37% cases. In our series three patients with incomplete injury showed improvement in ASIA score whereas some sensory score improvement was seen in three patients with initial ASIA A score (Fig. 3). Preoperative ASIA score was the only significant determinant of neurological outcome ($p = 0.009$). No neurological deterioration was seen. However the long tract function recovery was unrelated to the reduction of facets and realignment ($p > 0.05$) (Table 2). Overall mortality was 37%

with all cases having complete spinal injury (ASIA A). The most common denominator was ventilator dependence and associated pulmonary complications. The mortality was independent of reduction of facets and early surgery ($p > 0.05$) (Table 2).

The limitation of the study is small number of cases. The study attempts to address the prevailing controversies. Further large randomized studies are required to standardize the management of cervical spine injury with facet dislocation.

5. Conclusion

Bilateral facet dislocation can present with the entire spectrum of neurological deficits as well as no deficit. Patients with incomplete spinal cord injury show improvement after early decompression of the thecal sac and fixation to ensure stabilization. Anterior decompression and fixation is sufficient to meet both the goals.

REFERENCES

- Maiman Dennis J, Barolat Giancarlo, Larson Sanford J. Management of bilateral locked facets of the cervical spine. *Neurosurgery*. 1986;18:542–545.
- Vaccaro Alexander R, Hulbert R John, Fisher Charles, et al. The sub-axial cervical spine injury classification system (SLIC): a novel approach to recognize the importance of morphology, neurology and integrity of the disco-ligamentous complex. *Spine*. 2007;32:2365–2374.
- Sonntag VK. Management of bilateral locked facets of the cervical spine. *Neurosurgery*. 1981;8:150–153.
- Payer Michael, Schmidt Meic H. Management of traumatic bilateral locked facets of the subaxial cervical spine. *Contemporary Neurosurgery*. 2005;27:5–7.
- Ebrahim NA, Patil V, Liu J, Haman SP, Yeasting RA. Morphometric analysis of the superior facets and implications for facet dislocation. *Int Orthop*. 2008;32:97–101.
- Lee Joon Y, Nassr Ahmad, Jason C Eck, Vaccaro Alexander R. Controversies in the treatment of cervical spine dislocations. *Spine J*. 2009;9:418–423.
- Ze-sheng Yu, Yue James J, Feng Wei, Zhong-jun Liu, Dang Geng-ting Chen Zhong-qiang. Treatment of cervical dislocation with locked facets. *Chin Med J*. 2007;120:216–218.
- Stellerman CB, Roy RS, Weiss MH. Cervical spine injuries; diagnosis and management. In: Wilkins RH, Rengachary SS, eds. *Neurosurgery*. New York: McGraw Hill; 1996:2875–2904.
- Song Kyung-Jin, Lee Kwang-Bok. Anterior versus combined anterior and posterior fixation/fusion in the treatment of distraction-flexion injury in the lower cervical spine. *J Clin Neurosci*. 2008;15:36–42.