


Available online at www.sciencedirect.com

SciVerse ScienceDirect

journal homepage: www.elsevier.com/locate/ijnt

Original article

Management strategy in post traumatic brachial plexus injuries

P.S. Bhandari*, H.S. Bhatoe, M.K. Mukherjee, Prabal Deb

Department of Plastic and Reconstructive Surgery and Neurosurgery, Army Hospital (R&R), Delhi Cantt and Command Hospital Chandimandir, India

ARTICLE INFO

Article history:

Received 4 April 2012

Accepted 23 April 2012

Available online 16 May 2012

Keywords:

Brachial plexus injuries

Neurolysis

Nerve grafting

Nerve transfer

Muscle transfer

Nerve conduits

Fibrin glue

Spinal cord replantation

ABSTRACT

Background: Traumatic brachial plexus injury is a devastating condition resulting mainly from motor cycle accidents and primarily affecting the young adults. In the past there was a pessimistic attitude in the management of these injuries. However in last two decades with the introduction of microsurgical techniques and advances in imaging modalities, these injuries are being explored and repaired early with satisfactory to good functional outcomes.

Methods: Neurolysis, nerve repair, nerve grafting, nerve transfer, pedicle muscle transfer and functioning free-muscle transfer are the main surgical procedures in the management of brachial plexus injury. In the management of these injuries an immediate intervention is considered in penetrating trauma. All other common high velocity traction injuries are initially observed for a spontaneous recovery. If there are no signs of recovery by three months, surgery is indicated, as further delay will affect the ultimate results. In global brachial plexus palsy with all root avulsions, intervention is even earlier, as chances of spontaneous recovery are practically nil.

Results: Good results are expected with early intervention in upper plexal lesions. Results are favorable with short nerve grafts, distal nerve transfers, and intraplexal neurotization. The aim in global brachial plexus palsy is to restore the elbow flexion and provide a stable shoulder. Restoration of a fully functional and sensate hand is still far from being a reality.

Conclusion: The management of brachial plexus injury remains a challenging problem. Functional results have considerably improved in the past two decades with the incorporation of microsurgical techniques in nerve surgery, and advancements in anesthesia. Following microsurgical reconstruction many of these patients are expected to return to their original work and amputation is no longer considered a treatment option.

Copyright © 2012, Neurotrauma Society of India. All rights reserved.

1. Introduction

Brachial plexus injuries are devastating injuries resulting usually from high velocity motor bike accidents. In one report¹

brachial plexus injuries were present in 4.2% of motor cycle accidents. Other motor vehicular accidents accounted for 0.67–1.2% of the lesions. Management of devastating brachial plexus injury is demanding and difficult. Advances in

* Corresponding author. Department of Plastic and Reconstructive Microsurgery, Army Hospital (Research and Referral), Delhi, India. Tel.: +91 9560295002.

E-mail address: doctorbhandari@hotmail.com (P.S. Bhandari).

0973-0508/\$ – see front matter Copyright © 2012, Neurotrauma Society of India. All rights reserved.

doi:10.1016/j.ijnt.2012.04.010

anesthesia, a sound knowledge of nerve anatomy and regeneration, and introduction of microsurgical techniques in nerve surgery, have considerably improved the results in past two decades. Amputation through the arm or arthrodesis of shoulder, which were once preferred techniques,² are no longer considered viable treatment options. Despite these advancements, since most of the victims suffer total palsies where reconstruction aims at achieving basic useful functions, a normal functioning and sensate limb is far from reality. Contrary to this situation is quite hopeful in partial injuries where microsurgical techniques restore good shoulder and elbow functions.

Timing of repair is an important factor in predicting the functional outcome. Most of the surgeons prefer an early repair within three months of injury³ as experience has shown that results of surgery deteriorate with passage of time.

Neurolysis, nerve repair, nerve grafting, nerve transfer, pedicle muscle transfer and functioning free-muscle transfer are the main surgical procedures in brachial plexus injury.

2. Anatomic considerations

Brachial plexus is formed by anterior primary rami of C5, C6, C7, C8 and T1 spinal nerve roots (Fig. 1). Some times C4 (prefixed) and T2 (post fixed) spinal nerves may also contribute to the plexus. The C5 and C6 nerve roots unite to form the upper trunk, C7 root continues as the middle trunk, and C8 and T1 nerve roots form the lower trunk. Suprascapular nerve arises from the upper trunk and courses inferolaterally toward the suprascapular notch. Each trunk divides into an anterior and a posterior division which lie under the clavicle. Infraclavicularly, anterior divisions of upper and middle trunks join to form the lateral cord, anterior division of lower trunk continues as the medial cord, where as all posterior divisions join to form the posterior cord. Major peripheral nerves emerge from the cords, e.g. musculocutaneous nerve from lateral cord, radial and axillary nerves from

posterior cord and ulnar nerve from medial cord. Two roots of median nerve originate from lateral and medial cords.

3. Mechanism of injury

The most common cause of brachial plexus injury is a traction injury sustained in high speed motor cycle accidents. As the victim lands on the ground the head and shoulder are forced apart resulting in an increased acromio-mastoid angle. The stress on plexus may rupture or avulse its roots. The other less common mode of injury is a penetrating trauma sustained in missile or stab injuries. Rarely there is an iatrogenic injury to the plexus during surgical procedures in the neck, e.g. lymph node biopsy, resection of first rib in thoracic outlet syndrome, etc.

4. Clinical presentation

Brachial plexus injuries usually occur in the setting of a poly trauma syndrome. The victim may suffer from major life threatening injuries. e.g. severe head injury, maxillo facial trauma, intra thoracic or intra abdominal injury or compound-comminuted fractures in the extremities. Neurological examination becomes difficult in an unconscious patient and this delays the diagnosis of a brachial plexus lesion. Clinical examination some times helps in the localization of lesion. An associated Horner's syndrome (Fig. 2) indicates a partial or complete avulsion of C8 and or T1 spinal roots. Presence of shoulder abduction signifies an infraclavicular injury. Severe deafferentation pain in the extremity indicates possible lower root avulsions.

5. Management strategy

Clean transections from stab or iatrogenic injuries if treated promptly provide good functional results. An early repair allows a direct approximation of cut ends. Also nerve grafts if

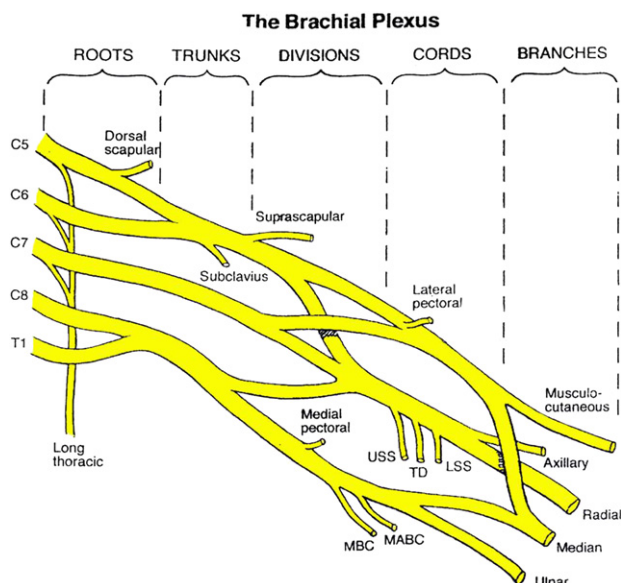


Fig. 1 – 1 Normal anatomy of brachial plexus.

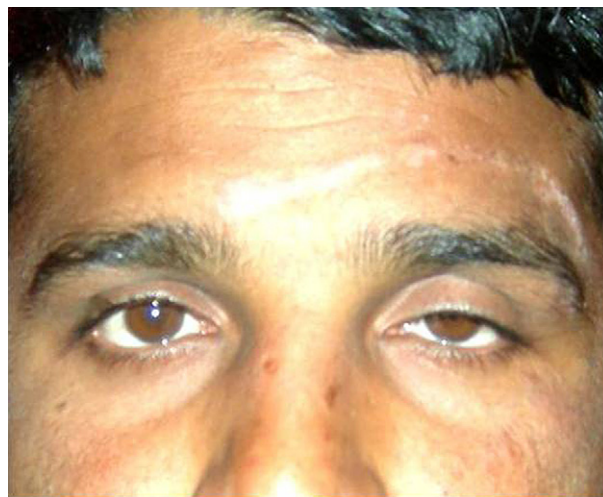


Fig. 2 – A case of all root avulsions with Horner's syndrome.

required are of short lengths as nerve ends had minimally retracted. In missile induced brachial plexus injury with associated vascular trauma it is safer to concentrate in the vascular repair at the initial exploration and leave the brachial plexus for an early secondary repair.⁴

6. Diagnostic modalities

A fracture in the transverse process of cervical spine in a plain radiograph may suggest an injury or avulsion of corresponding root. Similarly fracture of first rib may be associated with lower root injury. A plain chest radiograph showing a raised dome of diaphragm on the injured side suggests an associated phrenic nerve injury. An angiogram of upper extremity is indicated in suspected vascular injury. Presence of fibrillation waves on electromyography performed one month after injury suggests muscle denervation where as motor unit potentials indicate muscle reinnervation.

6.1. CT myelography

Myelography, in the evaluation of brachial plexus injuries, was first introduced by Murphey et al in 1947.⁵ It is a simple and economical modality but involves radiation exposure and adverse effects from contrast material. Immediately after the injury, presence of blood clots may impede the pooling of dye and produce artifact, or if the tear has not yet completely sealed, there will be free flow of contrast dye to surrounding spaces. Therefore myelography is best performed at least 1 month after the injury when the tear has fully sealed and formed a pseudomeningocele. Root avulsions may occur without a meningocele, and a meningocele occasionally exists without a nerve root avulsion.⁶ CT myelography is considered most reliable imaging modality in the diagnosis of root avulsion injuries.⁷ However a recent report mentions almost equal sensitivity (93%) of both CT and MR myelography in the evaluation of root avulsion injuries.⁸

6.2. Magnetic resonance imaging

MRI has the advantage of visualizing all portions of the brachial plexus, whereas CT myelography evaluates mainly the roots. MR myelography performed with FIESTA (fast imaging employing steady-state acquisition) has been claimed to provide good visualization of nerve roots.⁹ Recently two new modalities, diffusion-weighted neurography¹⁰ and Bezier surface reformation¹¹ have been used in the diagnosis of brachial plexus lesions. Diffusion-weighted neurography has been found useful for evaluating post ganglionic brachial plexus lesions, where as with Bezier surface reformation it is possible to demonstrate entire intradural nerve roots on a single image.

6.3. Timing of repair

The commonly seen closed injuries are initially managed conservatively. Some of them are neuropraxic injuries and recover in few weeks time. Other injuries should be observed

up to 10–12 weeks for spontaneous recovery. During this period passive range of joints is maintained. After one month of injury an electromyography and CT myelography/MR myelography is performed. Patients with clinical (flail and anesthetic limb, Horner's sign, severe deafferentation pain) and radiological evidence of root avulsions (pseudomeningoceles, Fig. 3), can be operated at this time. Other patients should be followed for another 6–8 weeks for neurological recovery. If there is no recovery, surgery should not be delayed further as results of surgery deteriorate with passage of time. If partial recovery has occurred, exploration and reconstruction of the nerves that are not recovering is indicated.

7. Surgical technique

The dissection of brachial plexus and other important nerves used in nerve transfers, is performed under general anesthesia. Patient is placed in supine position and plexus is explored through a reverse C-shaped incision starting along

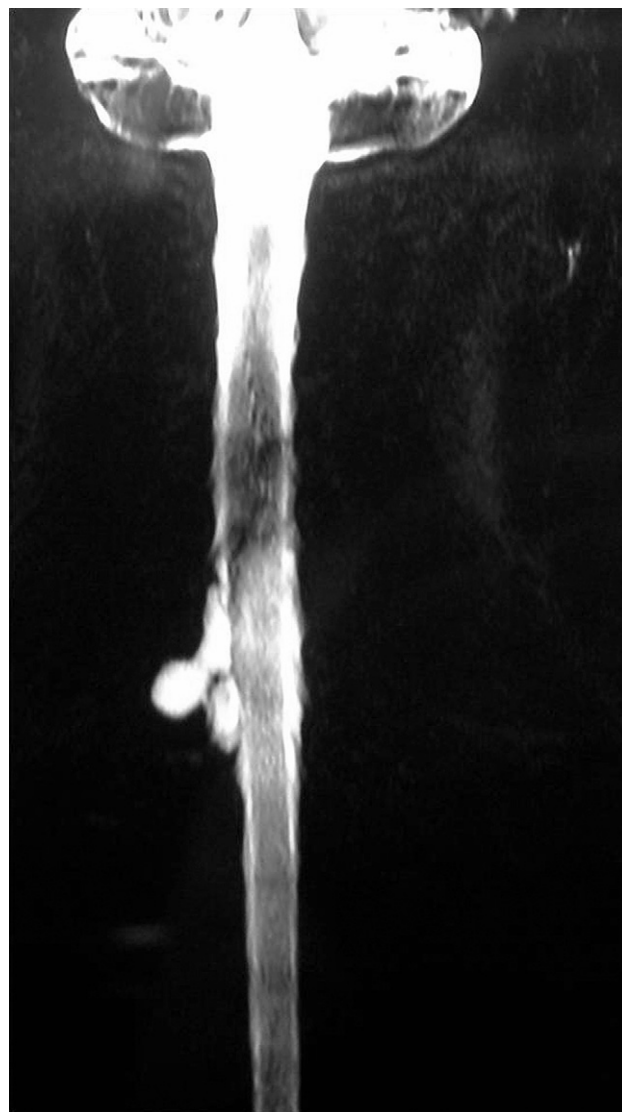

Fig. 3 – Pseudomeningoceles on MR myelogram.

the posterior border of lower part of sternocleidomastoid muscle and then continuing above and parallel to the clavicle. The patient's anesthesia is maintained with short-acting muscle relaxants. A nerve stimulator is used at 0.5, 1.0 and 2.0 mA to identify the motor branches throughout the surgical exploration. The upper brachial plexus spinal nerves are generally present in the space between the anterior middle scalene muscles. Their absence suggests root avulsions. This is correlated with the presence of characteristic pseudomeningoceles on CT myelogram/MR myelogram.

The suprascapular nerve is located along the lateral aspect of the upper trunk. Often the proximal end of the suprascapular nerve is involved in the upper trunk neuroma. To identify the spinal accessory nerve, the anterior border of the trapezius muscle is located 2–3 cm above the clavicle. The fascia over the trapezius muscle is incised and detached from the anterior surface of the muscle. The deep cervical fascia is opened to expose the accessory nerve and its branches. The accessory nerve is dissected and sectioned as distally as possible. The most proximal and prominent branches are always identified and preserved. The suprascapular nerve is usually in vicinity and a direct coaptation is possible between the two nerves. The phrenic nerve is located on the anterior surface of scalenus anterior muscle and identified by its vertical course and contractions of diaphragm on electrical stimulation. It is dissected distally and then divided and moved laterally for transfer.

Infraclavicular plexus is explored through an incision just medial to the deltopectoral groove and extending into the inner arm. Exposure of the cords and their terminal branches requires the division of pectoralis major and minor muscles. For the identification of posterior cord and the axillary nerve, the axillary artery is taped and pulled aside. The proximal part of axillary nerve is usually found near the inferior border of pectoralis minor muscle, where it branches off the posterior cord. A semicircular incision is extended from axillary incision on to the infraareolar region to gain access to the intercostal nerves. The deep central branches of the third, fourth and fifth intercostals nerves are used for transfer to musculocutaneous nerve. Oberlin transfers (partial transfers of the ulnar and median motor branches) are made through a longitudinal incision on the anteromedial aspect of upper arm. The musculocutaneous nerve is identified after it has traversed the coracobrachialis muscle. The motor branch to biceps is usually seen at an average distance of 12 cm from the acromion. The nerve to the brachialis muscle is found at an average of 18 cm below the acromion. The ulnar nerve is identified at the same level, and a longitudinal epineurotomy is made. One or two ulnar nerve fascicles^{12,13} are minimally dissected, sectioned and coapted to the biceps motor branch with 10-0 nylon suture. In a similar fashion one or two fascicles of the median nerve are coapted with the motor branch to the brachialis. Again a tension-free nerve anastomosis is ensured. For the transfer of a motor branch to long-head triceps to the axillary nerve, patient is placed in semilateral position with upper arm over the thorax. An oblique incision is made along the posterior border of deltoid. Axillary nerve is identified in the quadrilateral space, bounded above by the teres minor muscle, below by the teres major muscle, laterally by the humerus and medially by the long head of triceps muscle. After emerging

from the quadrilateral space, the axillary nerve gives branches into teres minor muscle and then divides into 1–3 anterior branch(es) and one posterior branch. The anterior branch or branches provide major motor supply to the deltoid. This branch or branches are dissected intraneurally as proximal as possible and transected. Through the inferior part of incision, the long and lateral heads of triceps muscle are separated and the radial nerve visualized in the triangular space. The motor branch to long head of triceps is usually given off at a distance of 90 mm from the angle of acromion. This branch is sectioned as distally as possible and then flipped 180° for coaptation to the anterior branch or branches of the axillary nerve. In all cases, nerve dissections are done under 4× loupe magnification, and nerve coaptations are made under the operating microscope with 10-0 nylon sutures.

Transfer of the spinal accessory nerve or the phrenic nerve into the musculocutaneous nerve always requires an intervening sural nerve graft. Phrenic nerve can be transferred directly to suprascapular nerve. However, its transfer to axillary nerve requires an intervening sural nerve graft.

Postoperatively, the flexed arm is strapped to the chest for a period of 3 weeks. After that gradually increasing passive exercises are started in the shoulder and elbow joints. Paralyzed muscles are subjected to electrical stimulation till M3 power is achieved.

8. Nerve related procedures

Nerve related procedures are almost always superior to palliative muscle or tendon transfer in adult brachial plexus injury.

8.1. Neurolysis

Neurolysis is the process of freeing the nerve from its bed by removing adhesions and also excising the constrictive scar tissue from around (external neurolysis) and within the nerve (internal neurolysis). It is indicated for lesions in continuity which are conducting on electrical stimulation.

8.2. Direct repair

A direct nerve repair without nerve grafts is possible in only sharply transected injuries (stab and iatrogenic injuries), provided the proximal and distal stumps can be approximated without the tension. In more common traction injuries nerve ends are retracted apart and a direct coaptation is not feasible.

8.3. Nerve grafts

Nerve grafting is the predominant technique employed in brachial plexus repair. Nerve grafts are required in traction injuries to bridge the nerve defects once the neuromas are resected (Figs. 4–8). The commonly used donor nerves are the sural nerve, medial cutaneous nerve of the forearm, lateral cutaneous nerve of the forearm and ipsilateral ulnar nerve as a pedicled vascularized nerve graft in lower root avulsions. In nerve grafting, certain points need elaboration. A tension free nerve graft is better than a primary repair under tension. Thin,

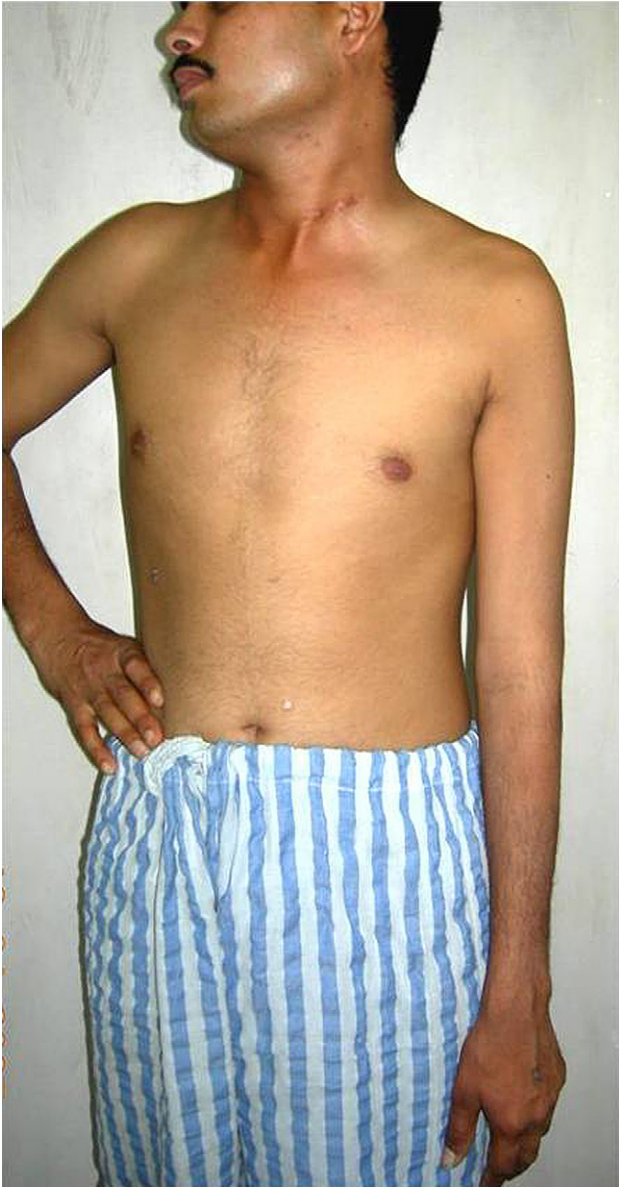

Fig. 4 – A splinter injury neck causing upper trunk injury.

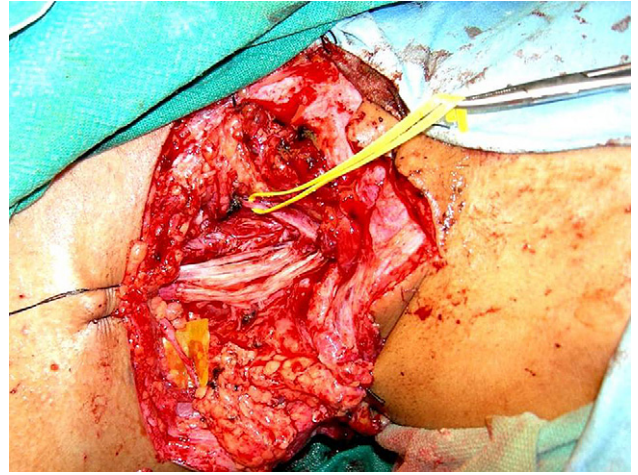


Fig. 6 – Upper trunk sural nerve grafting.

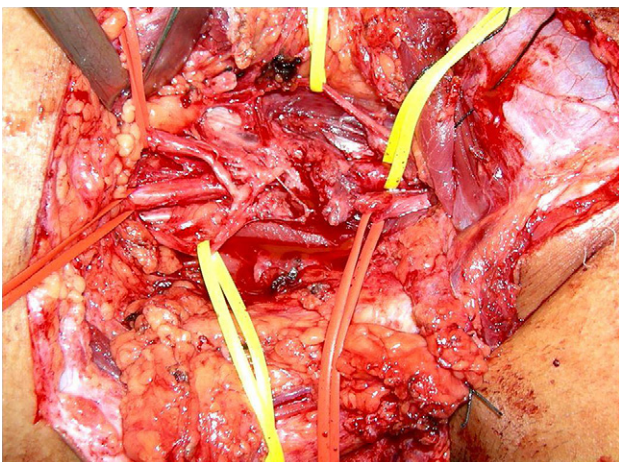


Fig. 5 – Upper trunk injury.

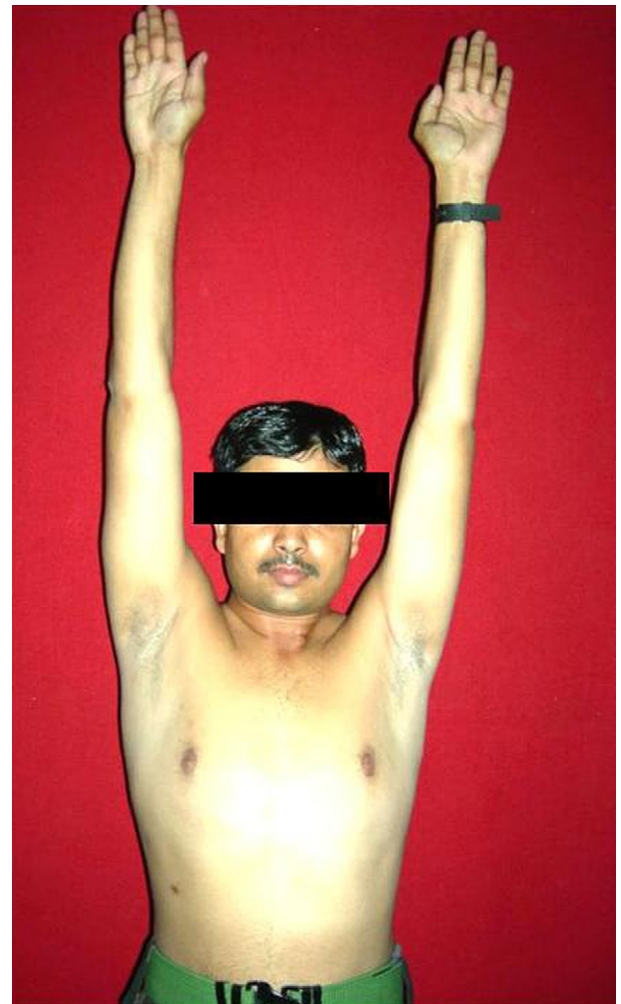

Fig. 7 – Restoration of full range shoulder abduction following upper trunk sural nerve grafting.



Fig. 8 – M4 elbow flexion at 24 months follow up.

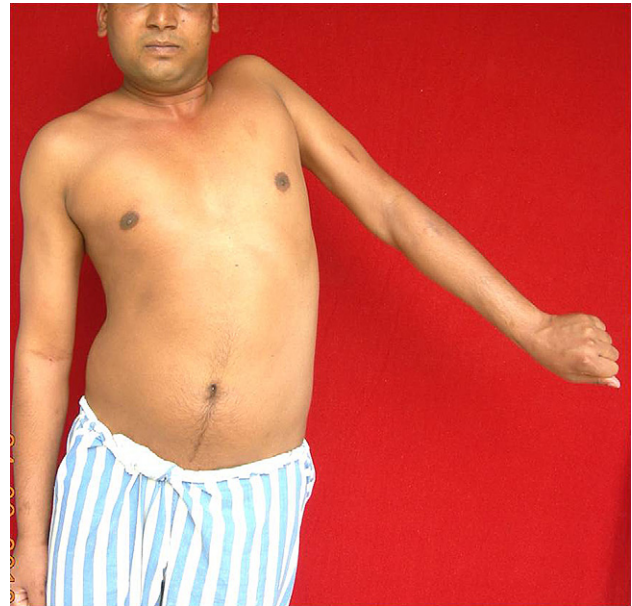

Fig. 9 – Upper brachial plexus injury with loss of shoulder and elbow functions.

cutaneous grafts (e.g. sural nerve) are preferred as they are easily vascularized. If the nerve graft is too thick (e.g. full thickness segments of a major nerve), the central part of the nerve graft will not become vascularized, and the graft will be a failure. Most surgeons are in the agreement that short nerve grafts are more successful than long nerve graft (i.e. more than 10 cm).^{14,15} The nerve graft should be 20% longer than the length of the nerve defect. Vascularized nerve grafts may be more suitable in a scarred bed and at reconstructing large nerve defects. Vascularized nerve grafts were introduced by Taylor & Ham in 1976.¹⁶ Though the initial results were encouraging, but the technique continues to be controversial. A vascular complication might result in the complete loss of the graft. However, for bridging the long defects (30 cm or more), such as in the contralateral transfer, vascularized nerve grafts might prove to be more useful.^{17–19} In global brachial plexus with C8 and T1 root avulsions, pedicled vascularized ulnar nerve has been used for a contralateral C7 root transfer to the median nerve.²⁰

Endoscopic harvesting of the sural nerve graft²¹ has been devised to overcome the potential drawbacks of the open technique. It is associated with less morbidity, more aesthetic advantages, and greater patient satisfaction.

8.4. Nerve transfers

Nerve transfer or neurotization involves transfer of a functional but less important nerve to the distal, irreparable, but more important denervated avulsed nerve usually within a period of 6 months after the injury. Nerve transfers are performed for repair of severe brachial plexus injury, in which the proximal spinal nerve roots have been avulsed from the spinal cord. A proximal healthy nerve is coapted to the distal denervated nerve to reinnervate the latter by the donated

axons. The use of nerve transfers has been a major advance in the field of brachial plexus reconstruction with many different donor nerves being used to restore the desired function (Figs. 9–17).

Ideally nerve transfers should be performed within 6 months post injury and may be better suited than nerve grafting in repairs after the preferred 6 months time frame. Nerve transfer or neurotization includes three major categories, extraplexal neurotization, intraplexal neurotization,

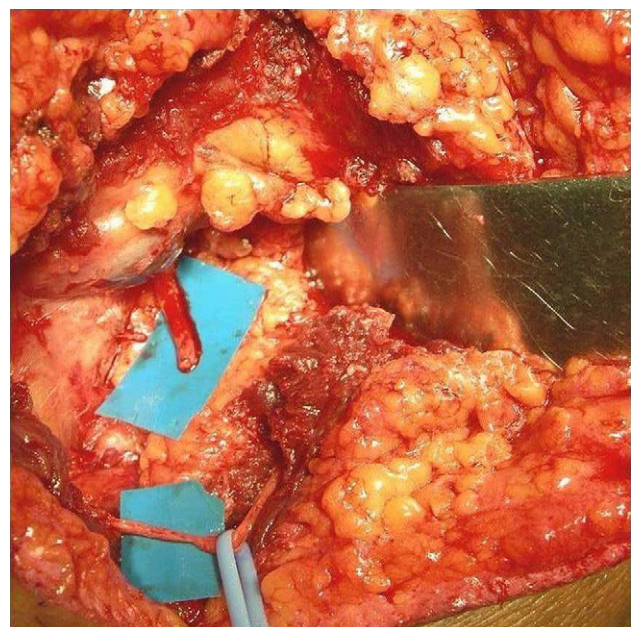


Fig. 10 – Transfer of spinal accessory nerve to suprascapular nerve.

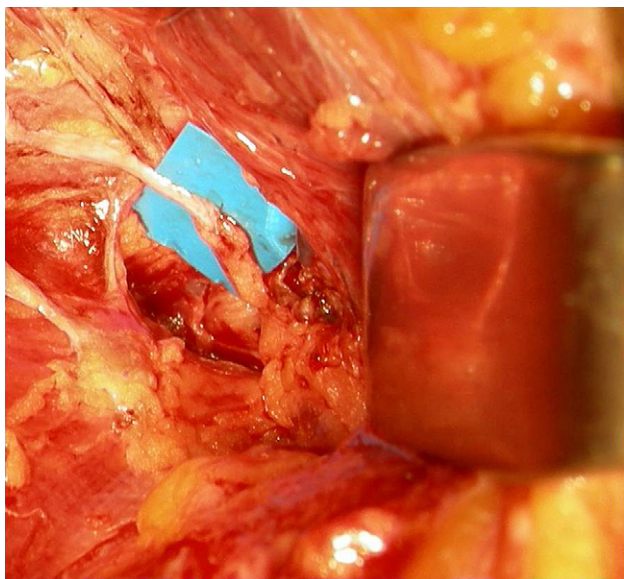


Fig. 11 – Transfer of long head triceps branch(radial nerve) to anterior branch of axillary nerve.

and end-to-side neurotaphy. Extraplexal neurotization is the transfer of a non brachial plexus component nerve to the brachial plexus for neurotization of an avulsed nerve. Sources commonly used include spinal accessory nerve,^{22–24} intercostal nerves,^{25,26} phrenic nerve,²⁷ deep cervical branches,²⁸ and contralateral C7 transfer.²⁹ Intraplexal neurotization is the transfer of a spinal nerve or more distal plexus component with intact spinal cord connections to a more important denervated nerve. In most cases, a ruptured proximal nerve is used. Examples include connecting the proximal stumps of C5 or C6 to the distal aspect of C8, lower trunk, or median nerve. More recently, the use of a fascicle of a functioning ulnar or median nerve (Oberlin transfer), in patients with intact C8 and T1, has allowed a rapid and powerful return of elbow flexion.³⁰ Neuromuscular neurotization³¹ (direct implantation of motor nerve fascicles in to denervated muscle) may also be used from intraplexal sources. In the end-to-side neurotaphy,³²

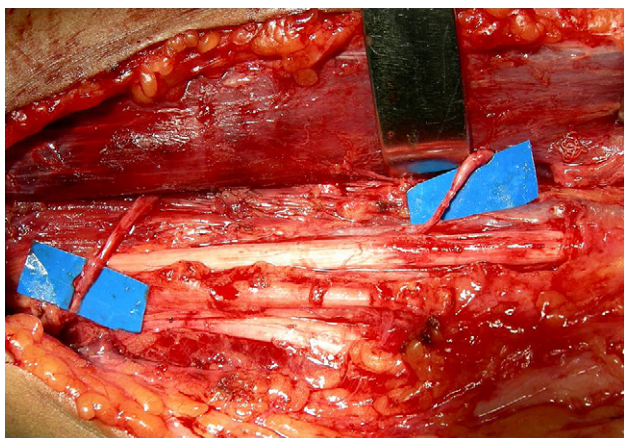


Fig. 12 – Oberlin transfers.

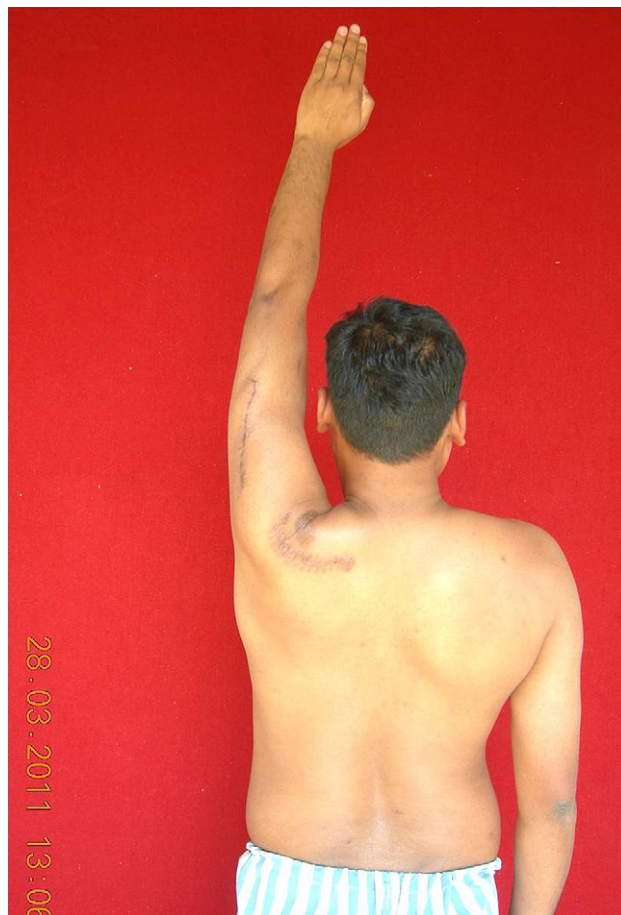

Fig. 13 – Restoration of full range of shoulder abduction at 24 months follow up.

the distal stump of an irreparably injured nerve is implanted into a healthy nerve without injuring the function of the healthy nerve. The method is mostly used for sensory neurotization but at present is seldom practiced.

Intercostal nerves contain a significant amount of sensory fibers. In this instance, its motor rami should be identified before it is connected to the motor recipient. The method of identification includes intraoperative electrical stimulation, dissection of nerve fibers and histochemical staining. Ideally there should be a matching in the number of fascicles in the donor and recipient nerves, but this is rarely possible.

A commonly used donor nerve such as intercostal nerve contains approximately 1300 myelinated fibers, and the spinal accessory nerve, 1700 fibers.^{33,34} Considering the recipient site, the suprascapular nerve contains approximately 3500 fibers, the musculocutaneous nerve contains 6000 fibers, the axillary nerve, 6500 fibers, the median nerve, 18,000 fibers; the ulnar nerve 16,000 fibers; and the radial nerve, 19,000 fibers.³⁵ An ideal motor neurotization of the musculocutaneous nerve that has 60% motor fiber would require two spinal accessory nerves,^{36,37} or five intercostal nerves.³⁸ However, in clinical situations only one spinal accessory nerve or two to three intercostal nerves can reinnervate biceps to a functional level (grade 3 or more) in 70% of patients.²³

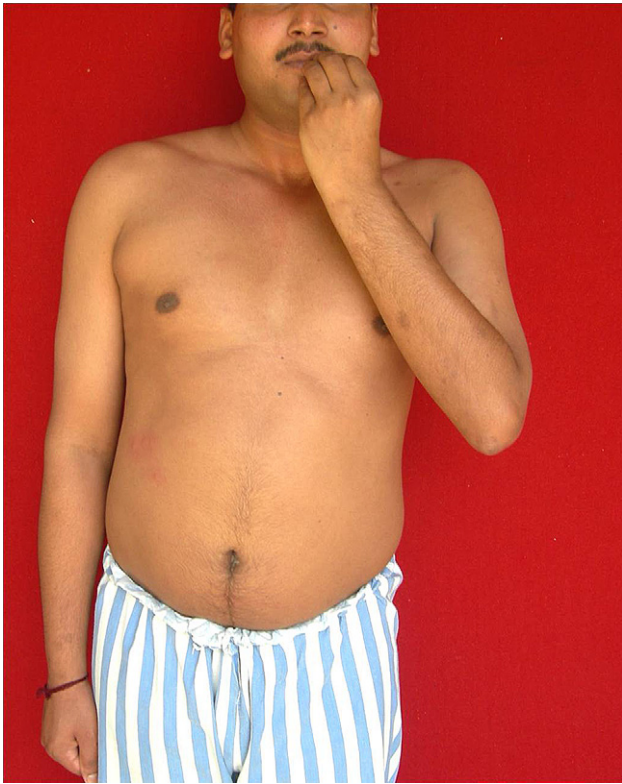

Fig. 14 – M4 elbow flexion at 24 months follow up.

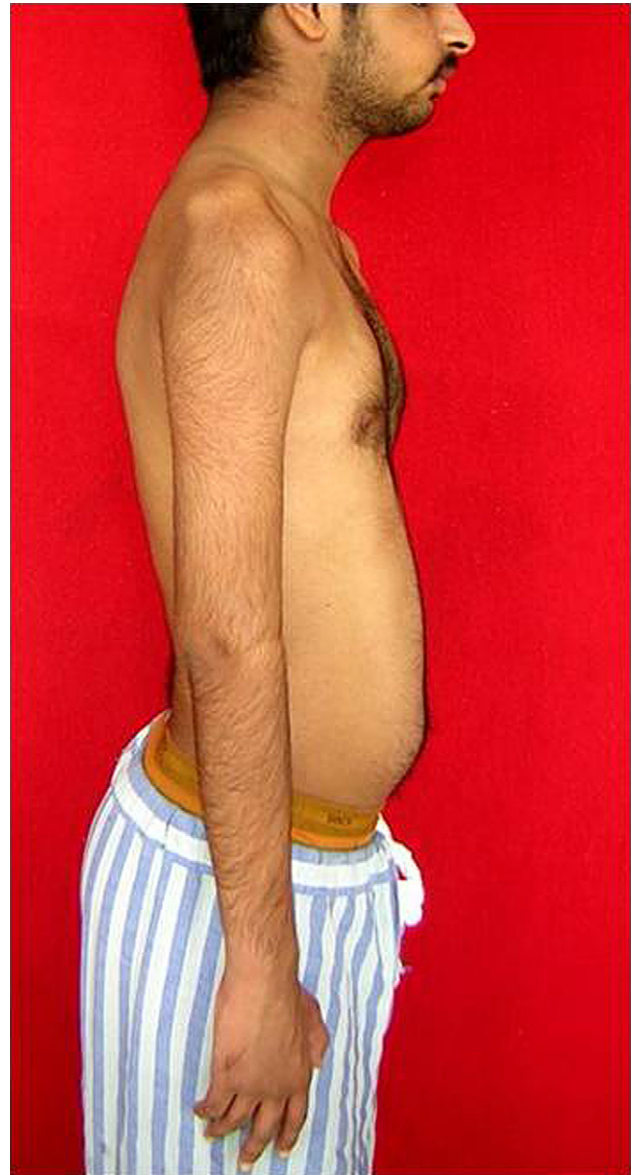

Fig. 15 – Upper and middle trunk injury.

Neurotization to a recipient site at the peripheral part of the plexus such as the musculocutaneous nerve, the suprascapular nerve, or the axillary nerve is more effective than a recipient in the central part such as the posterior cord or the lower trunk.

In the latter situation, the donor fibers are dispersed through branches to several nerves. Scattering of donor fibers over a large area not only makes neurotization insufficient but also causes simultaneous contraction of antagonistic muscles.

Another important aspect of neurotization is to reinnervate the recipient nerve as close to the target muscle as possible. An outstanding example of the latter is the transfer of an ulnar nerve fascicle directly to the biceps branch of the musculocutaneous nerve in close proximity to its entry into the muscle. In a similar fashion distal part of spinal accessory nerve can be transferred in to the suprascapular nerve through an incision placed directly over the scapular spine.³⁹ A direct suture without tension is always superior to indirect suture with a nerve graft. This is especially true for the weak donor nerves such as intercostal nerves and the distal spinal accessory nerve. Ipsilateral nerve transfer is always superior to the contralateral nerve transfer. For example, an ipsilateral C5 to median nerve transfer will be better than a contralateral C7 to median nerve transfer from the functional point of view.

Neurotization sacrifices the donor nerve, at least partially to restore the recipient nerve or muscle function. The net gain in function must be more important to the affected limb than the function that is lost. Theoretically, transferring a pure motor donor nerve to a motor recipient nerve gives the best result of motor neurotization, for example, spinal accessory

suprascapular neurotization. However, not all of the available donor nerves are pure motor nerves.

In general, spinal accessory nerve transfers are most appropriate for the shoulder, intercostal nerve transfer for the elbow flexion and phrenic nerve transfers for shoulder function or arm extensors. When available, partial ulnar nerve transfer is best used for elbow flexion. The contralateral C7 transfer is performed for hand flexors and sensation in global plexopathies.

All patients undergoing neurotization need induction exercises. For example, after intercostal or phrenic nerve transfer patients will be directed to run, walk or perform hill climbing to obtain deep breathing. As recovery progresses, frequent exercise of the reinnervated muscles provides an internal nerve impulse that is always superior to the external electrical stimulation. The patient must be motivated and able to cooperate with surgical pre-and postoperative care recommendations.

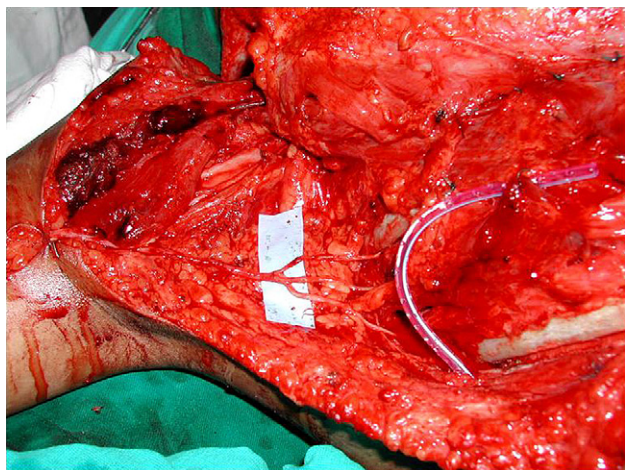


Fig. 16 – 3rd, 4th and 5th intercostal nerves transferred to musculocutaneous nerve.

9. Secondary procedures in brachial plexus injury

A sizable number of patients fail to recover following primary nerve reconstruction. Also there is a group of patients who report more than a year after injury when primary reconstruction is not feasible. Such cases can be rehabilitated by secondary procedures such as tendon or pedicled muscle transfers, free functioning muscle transfers, osteotomies and arthrodesis. Arthrodesis of shoulder joint is indicated if function of thoracoscaphular muscles is intact.⁴⁰ The glenohumeral joint is fixed at 45° of ante-position, 30° of abduction and 40° of internal rotation. Transfer of trapezius muscle with a segment of acromion to the surgical neck of humerus provides stability of the shoulder joint and in some cases restores up to 20° of abduction.⁴¹ The muscle transfers aimed in restoration of elbow flexion include proximal transfer of forearm flexor-pronator mass (Steindler flexoplasty),⁴² anterior transfer of triceps tendon,⁴³ latissimus dorsi transfer,⁴⁴ pectoralis major transfer⁴⁵ and free functioning muscle

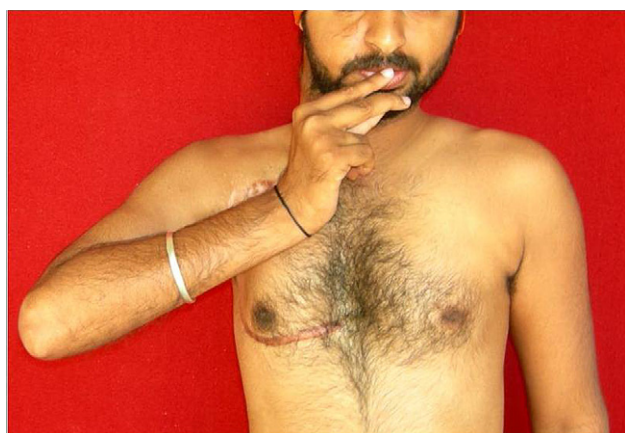

Fig. 17 – M4 elbow flexion 36 months after intercostal nerves to musculocutaneous nerve transfer.

transfer using gracilis muscle.⁴⁶ Other secondary procedures mainly applicable to global brachial plexus palsy are derotation osteotomy of radius to correct severe forearm pronation contracture, arthrodesis of flail wrist, arthrodesis of thumb and fingers in functional position.

10. Reimplantation of avulsed spinal roots into the spinal cord

Complete avulsion of all roots of the brachial plexus is a serious problem. In the 1980s, several workers^{47,48} observed in animal models that implantation of a peripheral nerve graft into the spinal cord can induce regeneration of spinal motor neurons. Carlstedt⁴⁹ was the first to apply these observations in human beings. He treated a patient with C6 to T1 root avulsion injury by implanting two ventral roots into the spinal cord through slits in the piamater, C6 directly and C7 via a nerve graft. At 3 years power in biceps was M4 and patient had voluntary activity also in the deltoid (M2), triceps (M1-2) and brachioradialis (M1-2). In 2000, Carlstedt and others⁵⁰ published the results of the reimplantation technique in a larger group of patients. Bertelli et al⁵¹ noticed the improvement in proximal muscle function and opined that this improvement is limited and does not justify the use of spinal implants. In 2005, Fournier et al⁵² concluded that the outcomes of root implantation were modest and results were better when the diagnosis of avulsion was made within 10 days and reparative surgery undertaken within 3 weeks of injury.

11. Conclusion

Brachial plexus injuries represent devastating injuries with a poor prognosis. Introduction of microsurgical techniques in neurolysis, nerve repair, nerve grafting and nerve transfer has made possible to restore a functioning limb in many of the patients with brachial plexus injuries, which was considered a difficult or an impossible task just two decades back. An early repair within 6 months of injury is important for a successful outcome. Patients reporting late may be benefited with secondary muscle and skeletal procedures. Direct replantation of avulsed spinal roots into the spinal cord is a new area of research in brachial plexus reconstruction.

REFERENCES

1. Midha R. Epidemiology of brachial plexus injuries in a multitrauma population. *Neurosurgery*. 1997;40:1182–1189.
2. Yeoman PM, Seddon HJ. Brachial plexus injuries: treatment of the flail arm. *J Bone Jt Surg*. 1961;43B(3):493–500.
3. Tung THH, Mackinnon SE. Brachial plexus injuries. *Clin Plast Surg*. 2003;30:269–287.
4. Bhandari PS, Sadhotra LP, Bhargava P, et al. Management of missile injuries of the brachial plexus. *Ind J Neurotrauma*. 2006;3:49–54.
5. Murphey F, Hartung W, Kirkin JW. Myelographic demonstration of avulsing injury of the brachial plexus. *Arm J Roengenol*. 1947;58:102–105.

6. Ochi M, Ikuta Y, Watanabe M, Kimori K, Itoh K. The diagnostic value of MRI in traumatic brachial plexus injury. *J Hand Surg (Br)*. 1994;19:55–59.
7. van Es HW. MRI of the brachial plexus. *Eur Radiol*. 2001;11:325–336.
8. Doi K, Otsuka K, Okamoto Y, et al. Cervical nerve root avulsion in brachial plexus injuries: magnetic resonance imaging classification and comparison with myelography and computerized tomography myelography. *J Neurosurg Spine*. 2002;96:277–284.
9. Yoshikawa T, Hayashi N, Tajiri N, et al. Can MR myelography using FIESTA replace CT myelography to assess preganglionic nerve roots in traumatic brachial plexus injuries(abstract). In: *Radiological Society of North America Scientific Assembly and Annual Meeting Programme*. Oak Brook, III: Radiological Society of North America; 2004:394.
10. Takahara T, Yamashita T, Yanagimachi N, Iino M, Koizumi J, Imai Y. Imaging of peripheral nerve disease using diffusion weighted neurography (DMN) (abstr). In: *Radiological Society of North America Scientific Assembly and Annual Meeting Program*. Oak Brook, III: Radiological Society of North America; 2004: 394.
11. Yoshikawa T, Hayashi N, Yamamoto S, et al. Brachial plexus injury: clinical manifestations, conventional imaging findings, and the latest imaging techniques. *Radiographics*. 2006;26:S133–S143.
12. Bhandari PS, Deb P. Fascicular selection for nerve transfers: the role of the nerve stimulator when restoring elbow flexion in brachial plexus injuries. *J Hand Surg*. 2011;36(12):2002–2009.
13. Bhandari PS, Bhattoe HS. Is fascicular selection by nerve stimulation techniques a necessity in selective nerve transfers targeted at restoration of elbow flexion? *Ind J Neurotrauma*. 2011;8(2):99–104.
14. Millesi H. Surgical management of brachial plexus injuries. *J Hand Surg Am*. 1977;2:367.
15. Blezberg AJ, Dorsi MJ, Storm PB, Morlarity JL. Surgical repair of brachial plexus injury: a multinational survey of experienced peripheral nerve surgeons. *J Neurosurg*. 2004;101:265–276.
16. Taylor G, Ham F. The free vascularized nerve graft. *Plast Reconstr Surg*. 1975;57:413–426.
17. Bonney G, Birch R, Jamieson A, et al. Experience with vascularized nerve grafts. In: Terzis J, ed. *Microreconstruction of Nerve Injuries*. Philadelphia: W B Saunders; 1986: 403.
18. DOI K, Kuwata N, Kawakami F, et al. The free vascularized sural nerve graft. *Microsurgery*. 1984;5:175–184.
19. Hasegawa T, Nakamura S, Manabe T, et al. Vascularized nerve grafts for the treatment of the large nerve gaps after trauma to an upper extremity. *Arch Orthop Trauma Surg*. 2004;124:209–213.
20. Waikukul S, Orapin S, Vanadurongwan V. Clinical results of contralateral C7 root neurotization to the median nerve in brachial plexus injuries with total root avulsion. *J Hand Surg Br*. 1999;24:556–560.
21. Park SB, Cheshier S, Michaels D, Murovic JA, Kim DH. Endoscopic harvesting of the sural nerve graft: technical note. *Neurosurgery*. 2006;58(ONS supp 1). ONS 180.
22. Allieu Y, Cenac P. Neurotization via the spinal accessory nerve in complete paralysis due to multiple avulsion injuries of the brachial plexus. *Clin Orthop Relat Res*. 1988;237:67–74.
23. Songcharoen P, Mahaisavariya B, Chotigavanich C. Spinal accessory neurotization for restoration of elbow flexion in avulsion injuries of the brachial plexus. *J Hand Surg Am*. 1996;21:387–390.
24. Chuang DC, Lee GW, Hashem F, Wei FC. Restoration of shoulder abduction by nerve transfer in avulsed brachial plexus injury: evaluation of 99 patients with various nerve transfers. *Plast Reconstr Surg*. 1995;96:122–128.
25. Chuang DC, Yeh MC, Wei FC. Intercostal nerve transfer of the musculocutaneous nerve in avulsed brachial plexus injuries. *J Hand Surg Am*. 1992;17:808–822.
26. Krakauer JD, Wood MB. Intercostal nerve transfer for brachial plexopathy. *J Hand Surg Am*. 1994;19:829–835.
27. Gu YD, Wu MM, Zhen YL, et al. Phrenic nerve transfer for brachial plexus motor neurotization. *Microsurgery*. 1989;10:287–289.
28. Brunelli G, Monini L. Neurotization of avulsed roots of brachial plexus by means of anterior nerves of the cervical plexus. *Clin Plast Surg*. 1984;11:149–152.
29. Gu YD, Zhang GM, Chen DS, Yan JG, Cheng XM, Chen L. Seventh cervical nerve root transfer from the contralateral healthy side for treatment of brachial plexus root avulsion. *J Hand Surg*. 1992;17B:518–521.
30. Oberlin C, Beal D, Leechavengvongs S, et al. Nerve transfer to biceps muscle using part of ulnar nerve for C5–C6 avulsion of the brachial plexus: anatomical study and report of four cases. *J Hand Surg*. 1994;19(A):232–237.
31. Brunelli G. Direct neurotization of severely damaged muscles. *J Hand Surg*. 1982;7(6):572–579.
32. Zhang F, Fischer KA. End-to-side neurotization. *Microsurgery*. 2002;22(3):122–127.
33. Narakas A, Hentz V. Neurotization in brachial plexus injuries: indication and results. *Clin Orthop*. 1988;237:43–56.
34. Thomear RTWM, Malessy MJA. Surgical repair of brachial plexus injury. *Clin Neurol Neurosurg*. 1993;95:65–72.
35. Narakas AO. Thoughts on neurotization or nerve transfer in irreparable nerve lesions. *Clin Plast Surg*. 1984;11:153–159.
36. Merrel GA, Barrie KA, Katz DL, et al. Results of nerve transfer techniques for restoration of shoulder and elbow function in the context of a meta-analysis of the English literature. *J Hand Surg*. 2001;26:303–314.
37. Samardzic M, Rasulic L, Grujicic D, et al. Results of nerve transfer to the musculocutaneous and axillary nerves. *Neurosurgery*. 2000;46:93–103.
38. Nagano A, Yamamoto S, Mikami Y. Intercostal nerve transfer to restore upper extremity functions after brachial plexus injury. *Ann Acad Med Singapore*. 1995;24(suppl 4):42–45.
39. Bhandari PS, Deb P. Dorsal approach in transfer of the distal spinal accessory nerve into the suprascapular nerve; histomorphometric analysis and clinical results in 14 cases of upper brachial plexus injuries. *J Hand Surg*. 2011;36A:1182–1190.
40. Cofield RH, Briggs BT. Glenohumeral arthrodesis. Operative and long-term functional results. *J Bone Jt Surg*. 1979;61A:668–677.
41. Saha AK. Surgery of paralysed and flail shoulder. *Acta Orthop Scand*. 1967;97(suppl):5–90.
42. Liu T, Yang R, Sun J. Long term results of the Steindler flexorplasty. *Clin Orthop*. 1993;296:104–108.
43. Hoang P, Mills C, Burke F. Triceps to biceps transfer for established brachial plexus palsy. *J Bone Jt Surg*. 1989;71B(2):268–271.
44. Zancolli E, Mitre H. Latissimus dorsi transfer to restore elbow flexion. An appraisal of eight cases. *J Bone Jt Surg*. 1973;55A(6):1265–1277.
45. Matory W Jr, Morgan W, Breen T. Technical considerations in pectoralis major transfer for treatment of the paralytic elbow. *J Hand Surg*. 1991;16A(1):12–18.
46. Doi K, Kuwata N, Muramatsu K, et al. Double muscle transfer for upper extremity reconstruction following complete avulsion of the brachial plexus. *Hand Clin*. 1999;15:757–767.
47. Aguayo AJ, David S, Bray GM. Influences of the glial environment on the elongation of axons after injury; transplantation studies in adult rodents. *J Exp Biol*. 1981;95:231–240.
48. Richardson PM, Issa VM, Aguayo AJ. Regeneration of long spinal axons in the rat. *J Neurocytol*. 1984;13:165–182.

49. Carlstedt T, Grane P, Hallin RG, Norén G. Return of function after spinal cord implantation of avulsed spinal nerve roots. *Lancet*. 1995;346:1323–1325.
50. Carlstedt T, Anand P, Hallin R, Misra PV, Norén G, Seferlis T. Spinal nerve root repair and reimplantation of avulsed ventral roots into the spinal cord after brachial plexus injury. *J Neurosurg*. 2000;93:237–247.
51. Bertelli JA, Ghizoni MF. Brachial plexus avulsion injury repairs with nerve transfers and nerve grafts directly implanted into the spinal cord yield partial recovery of shoulder and elbow movements. *Neurosurgery*. 2003;52:1385–1390.
52. Fournier HD, Mercier P, Menei P. Repair of avulsed ventral nerve roots by direct ventral intra spinal implantation after brachial plexus injury. *Hand Clin*. 2005;21:109–118.