


Available online at [www.sciencedirect.com](http://www.sciencedirect.com)

SciVerse ScienceDirect

journal homepage: [www.elsevier.com/locate/ijnt](http://www.elsevier.com/locate/ijnt)

## Case report

# Post-traumatic infection induced scalp necrosis – An unusual complication

Amandeep Kumar<sup>a</sup>, Sumit Sinha\*, Ashok Kumar Mahapatra<sup>b</sup>

Department of Neurosurgery, All India Institute of Medical Sciences, Room Number 720, 7th Floor, Cardioneurosciences Centre, Ansari Nagar, New Delhi 110029, India

### ARTICLE INFO

#### Article history:

Received 16 February 2012

Accepted 25 March 2012

Available online 21 April 2012

#### Keywords:

Post-traumatic

Scalp necrosis

Superficial temporal artery

Thrombosis

Infection

### ABSTRACT

**Introduction:** Scalp wounds usually heal very well and necrosis of scalp is very rare due to its extensive vascularity. We present a case of scalp necrosis as an unusual complication of road traffic injury.

**Case report:** A 50-year old male with post-traumatic quadriplegia due to C5 fracture dislocation and scalp laceration presented to us. Patient developed scalp necrosis after 5 days. Wound cultures grew *Acinetobacter baumannii*.

**Conclusion:** Despite extensive vascularity, post-traumatic wounds with superadded infection can rarely lead to scalp necrosis. Thorough early wound debridement can help in preventing this rare but devastating complication.

Copyright © 2012, Neurotrauma Society of India. All rights reserved.

## 1. Introduction

Scalp has a very rich vascular supply. Necrosis of scalp is a very rare condition due to this richness of vascularity. We present an unusual case of post-traumatic scalp necrosis.

## 2. Case report

A 50-year old male was admitted to our trauma centre with post-traumatic quadriplegia due to C5 fracture dislocation. The patient was initially treated at another hospital and came

to us after 48 h of injury. Patient had a linear lacerated scalp wound involving right fronto-parietal area, without any associated fracture of the underlying bone. The wound was contaminated with dirt particles lying inside the wound. Patient had received intravenous methylprednisolone after injury for 24 h. On 5th day, patient started developing scalp discoloration which spread over the next 2 days to involve the entire right fronto-temporo-parietal area with a clear line of demarcation suggestive of scalp necrosis (Fig. 1). Ultrasound doppler revealed thrombosis of right superficial temporal artery with normal external carotid artery flow. *Acinetobacter baumannii* was grown from the wound.

\* Corresponding author. Tel.: +91 9868398244.

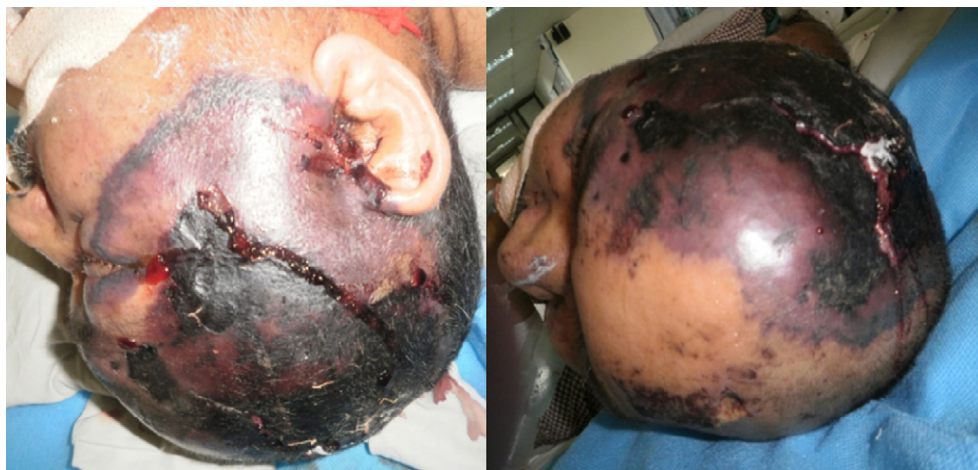E-mail addresses: [aman\\_jagdevan@yahoo.co.in](mailto:aman_jagdevan@yahoo.co.in) (A. Kumar), [sumitneuro@gmail.com](mailto:sumitneuro@gmail.com) (S. Sinha), [akmahapatra\\_22000@yahoo.com](mailto:akmahapatra_22000@yahoo.com) (A.K. Mahapatra).

<sup>a</sup> Tel.: +91 9958873574.

<sup>b</sup> Tel.: +91 11 26593291, +91 9868398073.

0973-0508/\$ – see front matter Copyright © 2012, Neurotrauma Society of India. All rights reserved.

doi:10.1016/j.ijnt.2012.04.011



**Fig. 1 – Photographs showing lacerated wound and well demarcated scalp necrosis.**

### 3. Discussion

Scalp is a highly vascular structure. Due to this extensive vascularity, scalp wounds heal very well even in cases of avulsion injuries. Infection of scalp wounds is usually limited and easily controllable and scalp necrosis is very rare.

In the present case, scalp necrosis started 5 days after injury. At the time of presentation, there was no evidence of compromised vascularity of the scalp. Thus, direct injury to STA leading to scalp necrosis is unlikely. The possible mechanism of scalp necrosis is related to infection of the lacerated wound. There was a delay of ~48 h in the debridement of the wound after injury. Delay in the cleansing/debridement of these wounds leads to increased risk of infection. Steroid induced immunosuppression further predisposes to infection. Infection induced microvascular thrombosis, spreading in a retrograde fashion and leading to STA thrombosis can explain the development of necrosis despite the rich vascularity of the scalp.

Though, necrotizing fasciitis of scalp is a well known entity,<sup>1</sup> to the best of our knowledge, post-traumatic scalp necrosis has not been previously described in the literature. We report first such case of scalp necrosis occurring in a delayed manner after injury. Scalp necrosis, however, has been reported as a rare manifestation of giant cell arteritis<sup>2</sup>

and as a complication of external carotid artery embolization for meningeal tumors.<sup>3</sup>

### 4. Conclusion

This case demonstrates that scalp lacerations which usually heal well, can develop serious complication. It also highlights the importance of early cleansing/debridement of the wound to prevent the development of this rare but devastating complication.

### REFERENCES

1. McMahon J, Lowe T, Koppel DA. Necrotizing soft tissue infections of the head and neck: case reports and literature review. *Oral Surg Oral Med Oral Pathol Oral Radiol Endod.* 2003 Jan;95(1):30–37.
2. Tsianakas A, Ehrchen JM, Presser D, et al. Scalp necrosis in giant cell arteritis: case report and review of the relevance of this cutaneous sign of large-vessel vasculitis. *J Am Acad Dermatol.* 2009 Oct;61(4):701–706.
3. Chan RC, Thompson GB. Ischemic necrosis of the scalp after preoperative embolization of meningeal tumors. *Neurosurgery.* 1984 Jul;15(1):76–81.