Available online at www.sciencedirect.com

SciVerse ScienceDirect

journal homepage: www.elsevier.com/locate/ijnt



Original article

NTSI-Alfred Trauma Research Development Award Paper

Hemostatic effect of human fibrin glue on bleeding surface of the brain: An experiment on albino Wistar rats

Vivek Agarwal[a,*], *Vernon Velho*[a], *Kundan S. Gosavi*[b], *Akash A. Khobragade*[c], *Rajendra Aher*[a], *Rachana S. Binayke*[d]

[a] *Department of Neurosurgery, Grant Medical College and Sir J. J. Group of Hospitals, India*
[b] *Department of Anesthesia, Grant Medical College and Sir J. J. Group of Hospitals, India*
[c] *Department of Pharmacology, Grant Medical College and Sir J. J. Group of Hospitals, India*
[d] *Department of Pathology, Grant Medical College and Sir J. J. Group of Hospitals, India*

ARTICLE INFO

Article history:
Received 11 December 2011
Accepted 14 March 2012
Available online 21 April 2012

Keywords:
Hemostasis
Fibrin glue
Animal experiment
Brain

ABSTRACT

Background: Achieving and maintaining hemostasis in neurosurgical procedures is critical to the outcome and challenging especially in cases of coagulopathy with diffuse oozing. After trauma to the brain, a cascade of events initiated by tissue factor (TF) or thromboplastin results in a defective coagulation process that even may lead to disseminated intravascular coagulation (DIC). Fibrin glue is sealant made up of fibrinogen and thrombin used for dural defect repair at the base, convexity, anastomosis of the nerve and nerve graft, reinforcing microvascular anastomosis. This study was carried out to determine the hemostatic effect of human fibrin glue on bleeding surface of brain and compare the effect with conventional methods of hemostasis.
Method: Thirty (30) white rats (*Rattus novergicus*) were divided equally into study and control group. After craniotomy and dural opening a stab incision was made on right frontal region of brain. In case group the bleeding was controlled with fibrin glue (average 0.5 ml) and in control group conventional method of hemostasis (cautery, cottonoid patty, and saline wash, surgicel) was used. Both the groups were studied for bleeding time, seizure, neurological deficit, wound complications and mortality.
Results: Outcome was assessed as 1) Bleeding in both the groups 2) Complications in both the groups. It was observed that in study group the time taken in hemostasis was significantly less in comparison to the control, No significant difference in the post procedure clinical outcome and inflammatory reaction/gliosis reaction was found in both the groups.
Conclusion: Human fibrin glue is simple, easy and safe alternative to conventional methods of hemostasis.

Copyright © 2012, Neurotrauma Society of India. All rights reserved.

* *Corresponding author*. Tel.: +91 9867647125 (mobile).
E-mail addresses: neuro.vi@gmail.com (V. Agarwal), vernonv7@hotmail.com (V. Velho), Kundangiri@rediffmail.com (K.S. Gosavi), Akash.khobragade@gmail.com (A.A. Khobragade), Vi.agrawal@yahoo.co.in (R. Aher), sbinayke@yahoo.com (R.S. Binayke).
0973-0508/$ – see front matter Copyright © 2012, Neurotrauma Society of India. All rights reserved.
doi:10.1016/j.ijnt.2012.04.014

This document was downloaded for personal use only. Unauthorized distribution is strictly prohibited.

1. Introduction

Achieving and maintaining hemostasis in neurosurgical procedures is critical to the outcome and challenging, especially in cases of coagulopathy with diffuse oozing. After trauma to the brain, a cascade of events initiated by tissue factor (TF) or thromboplastin results in a defective coagulation process that even may lead to disseminated intravascular coagulation (DIC).[1]

Fibrin glue has been used as a sealant for repair in situations such as dural defects at the base and convexity of the brain, nerve grafts, nerve anastomoses, reinforcing of microvascular anastomoses, carotico-cavernous fistulae and fixation of bone fragments.[2–6] In addition, it is known to have a hemostatic potential on the bleeding surface of the brain which might prove to be of special interest in cases with defective coagulation and excessive oozing where conventional methods of hemostasis are less effective.[1] In this study, we have evaluated the hemostatic action of fibrin glue in comparison with the conventional method of hemostasis i.e. bipolar cautery followed by pressure with a cottonoid patty and saline wash followed by surgicel.

2. Material and methods

After obtaining the prior approval of the institutional animal ethics committee, albino Wistar rats of either sex, weighing 250 g on an average, were procured from the central animal house of Grant Medical College and Sir JJ Group of Hospitals, Byculla, Mumbai-08. A pilot study conducted on 4 rats found the mean bleeding time using the conventional methods was 150 (+57) seconds. To demonstrate a reduction in bleeding time by at least 60 s using the fibrin glue a sample size of 15 was determined. The animals were randomly divided into two groups (study and control) of 15 animals each, and were maintained in clean polypropylene cages with clean husk bedding which was changed every three days. Food and water were given *ad libitum*.

On the day of the procedure, the rats were anesthetized using intraperitoneal Ketamine (50–100 mg/kg) (Fig. 1).[7] Blood loss was compensated with intraperitoneal Ringers Lactate. After fixing the head of rats over a specially designed dissection table (Figs. 2 and 3), a linear incision was taken over the right frontal region of the scalp under aseptic conditions. With the underlying bone exposed, a right frontal craniectomy was performed using a drill and a fine nibbler and the dura was exposed just anterior to the coronal suture. After opening the dura, a stab incision was made over the right frontal lobe and bleeding was induced. In the rats of the study group an average 0.5 ml of fibrin glue was applied over the bleeding area. In the rats of the control group, hemostasis was achieved by conventional method employing bipolar cautery, pressure with cottonoid patty and saline wash and surgicel. Bleeding from the brain was assessed in form of bleeding time in both the groups. The incision was then closed with Vicryl 4, 0. Rats were given antibiotics (Cefuroxime IM) and analgesia, local xylocaine at surgical site postoperatively and were monitored for up to 3 weeks post procedure for any neurological or behavioral derangement, seizures or any signs of impending death.[8]



Fig. 2 – Rat dissection board.

3. Results

The comparative bleeding times of the rats in the control and study groups are tabulated in Table 1, and the means

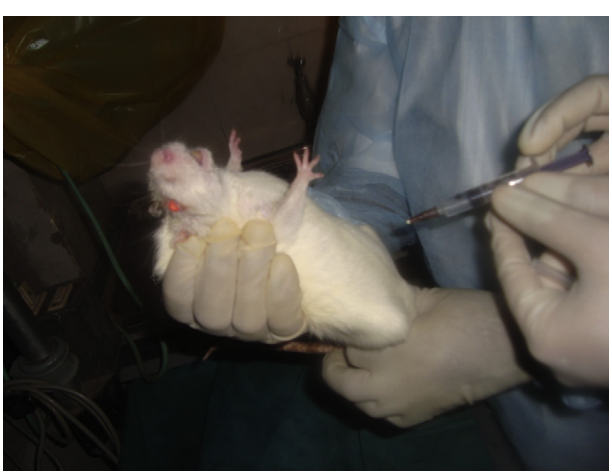

Fig. 1 – Intraperitoneal ketamine injection for general anesthesia.

Fig. 3 – Rat fixed over the dissection board with help of jaw holder and body clamp.

This document was downloaded for personal use only. Unauthorized distribution is strictly prohibited.

Table 1 – Comparison of bleeding time in both the groups.

Code no.	Study group bleeding time (sec)	Control group bleeding time (sec)
1	35	90
2	40	120
3	42	90
4	30	145
5	35	120
6	45	105
7	47	225
8	25	90
9	25	150
10	28	160
11	30	280
12	35	150
13	40	90
14	25	210
15	30	150
Mean	34.13	145
S.D.	7.35	56.12

compared in Bar Chart 1. The statistical significance was calculated using Unpaired *t* test, and a *p* value of <0.0001 was obtained.

All the rats in immediate post operative period showed a decreased physical activity which promptly reversed after 2 days. Post procedure, 2 rats from study group and 4 rats from control group developed weakness in their left anterior limbs (which was statistically not significant). No other complication was noted. One rat from each group succumbed in the 3rd week of observation, the study group rat on day 15 and the control group rat on day 21 post procedure. The reason of the mortality remained unclear; brain tissues taken from the operated site were examined histopathologically (Figs. 4 and 5), and the slides showed an abundance of inflammatory cells in both the groups and no difference in the gliosis. Post operative complications and mortality observed in both the groups are summarized in Table 2.

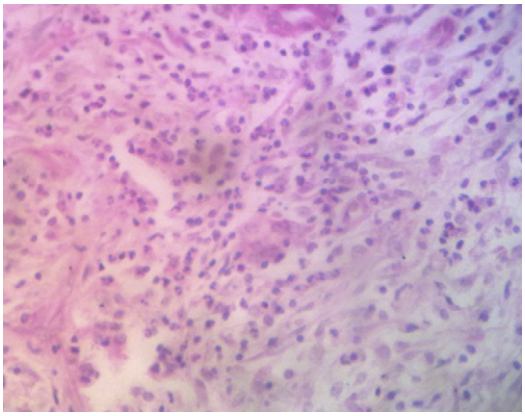

Fig. 4 – Histopathological slide of rat brain (study group) showing gliosis and inflammatory cells.

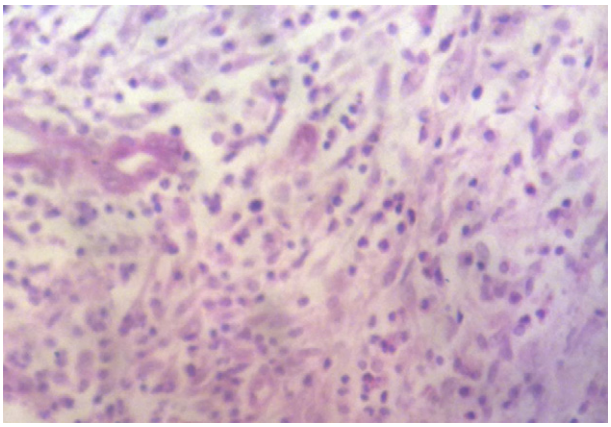

Fig. 5 – Histopathological slide of rat brain (control group) showing gliosis and inflammatory cells.

4. Discussion

Fibrin glue consists of two main components: 1. Fibrinogen 2. thrombin. It also contains aprotinin to delay the fibrinolytic action of plasmin. When injected the two components of fibrin glue meet in equal volume at the point of delivery

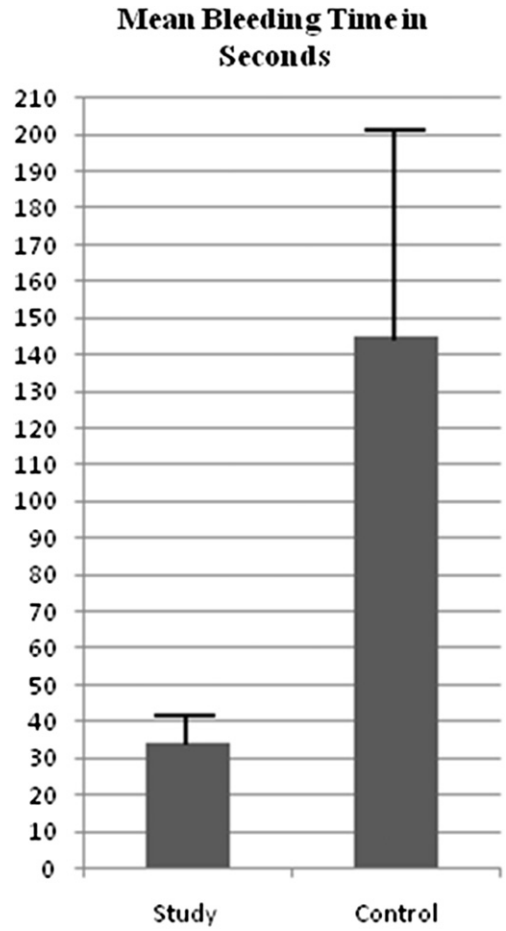

Bar Chart 1

This document was downloaded for personal use only. Unauthorized distribution is strictly prohibited.

Table 2 – Comparison of complications in two groups.

Complication	Study group	Control group
Neurological deficit	2	4
Seizure	Nil	Nil
Wound complication	Nil	Nil
Mortality	1	1

where thrombin converts the fibrinogen to fibrin. Depending on the concentration of the thrombin fibrin glue acts in 2 ways

(1) Fast acting –10 s
(2) Slow acting –60 s

Since it forms coagulum bypassing both the extrinsic and the intrinsic mechanisms of coagulation it is very helpful in achieving hemostasis in cases of coagulation disorder.

In cases of diffuse oozing controlling hemostasis with fibrin glue by spreading over the oozing surface takes lesser time as in our study, less damage to brain than by cautery, and less amount of blood loss.

Fibrin glue contains thrombin, a serine protease enzyme, which has antigenic properties. It might be expected to induce a variety of pathologic responses, including edema, seizures, and apoptotic changes.[9–12] However, we found no significant difference in neurological deficit in both the groups and the histological study was also comparable without significant difference in inflammation and gliosis. There remains the risk of transmitting serological disease from pooled and single – blood donors.

5. Summary

The use of fibrin glue as hemostatic agent over the bleeding surface of brain study in a controlled rat model demonstrated that the time taken for hemostasis in the study group was significantly less in comparison to control.

No significant difference in post operative clinical output was found in both groups.

No difference in the inflammatory reaction/gliosis reaction found in both the groups.

6. Conclusion

In our animal model fibrin glue offers a simple, easy and safe alternative to conventional method of hemostasis on bleeding surface of the brain.

REFERENCES

1. Gerald AG. Update on hemostasis: neurosurgery. *Surgery*. 2007;142:55–60.
2. Herter T. Problems of fibrin adhesion of the nerves. *Neurosurg Rev*. 1988;11:249–257.
3. Shaffrey CI, Spotnitz WD, Shaffrey ME, Jane JA. Neurosurgical applications of fibrin glue: augmentation of dural closure in 134 patients. *Neurosurgery*. 1990;26:207–210.
4. Krayenbuhl N, Hafez A, Hernesniemi JA, Krisht AF. Taming the cavernous sinus: technique of hemostasis using fibrin glue. *Neurosurgery*. 2007;61:52.
5. Fukumoto T, Matsushima Y, Tomita S, Inaba Y. The use of fibrin glue in neurosurgical operations. *No Shinkei Geka*. 1985;13:367–373.
6. Schafer M, Klein HJ, Richter HP. Fibrin glue in neurosurgery. Area of use and experiences. *Fortschr Med*. 1985;23:545–547.
7. Book 2. Pharmacology of injectible anesthesia Robert E. Meyer and Richard E. Fish anesthesia and analgesia in laboratory animals, Richard E. Fish, Marilyn J. Brown, American college of laboratory animal medicine series.
8. Edwards KC, Atkinson RM, Pratt DA, Patterson GG, Wheeldon JM, Foord RD. The toxicology of cefuroxime. *Proc R Soc Med*. 1977;70:11–18.
9. Kassam A, Nemoto E, Balzer J, et al. Effects of tisseel fibrin glue on the central nervous system of nonhuman primates. *Ear Nose Throat J*. 2004;83:246–248.
10. de Vries J, Menovsky T, van Gulik S, Wesseling P. Histological effects of fibrin glue on nervous tissue: a safety study in rats. *Surg Neurol*. 2002;57:415–422.
11. Brennan M. Fibrin glue. *Blood Rev*. 1991;5:240–244.
12. Thompson DF, Letassy NA, Thompson GD. Fibrin glue: a review of its preparation, efficacy, and adverse effects as a topical hemostat. *Drug Intell Clin Pharm*. 1988;22: 946–952.

This document was downloaded for personal use only. Unauthorized distribution is strictly prohibited.