


Available online at www.sciencedirect.com

SciVerse ScienceDirect

journal homepage: www.elsevier.com/locate/ijnt

Original Article

Missile injuries of spine and spinal cord in civilian Kashmir – Analysis and outcome evaluated by new Modified SKIMS-Functional Scales

Abdul Rashid Bhat^{a,*}, Mohammed Afzal Wani^{b,e}, Altaf Rehman Kirmani^{c,f},
Shafiq Alam^{d,g}, Tariq Raina^d, Sajad Arif^{d,h}, Altaf Ramzan^{a,i}, Masood A. Lahawal^d

^a Additional Professor, Department of Neurosurgery, Sher-i-Kashmir Institute of Medical Sciences (SKIMS), Srinagar, Kashmir, India

^b Head & Professor of Neurosurgery, SKIMS, Srinagar, Kashmir, India

^c Professor, Department of Neurosurgery, SKIMS, Srinagar, Kashmir, India

^d Senior Resident, Department of Neurosurgery, SKIMS, Srinagar, Kashmir, India

ARTICLE INFO

Article history:

Received 3 September 2012

Accepted 2 November 2012

Available online 2 January 2013

Keywords:

Spinal missile injuries

Modified SKIMS-Functional
ClassificationModified SKIMS-Functional
Outcome scale

ABSTRACT

Aims: Since the emergence of missile injuries of spinal cord is a major management-challenge due to its vulnerable vascularity, narrowly-packed neurons and tracts, associated injuries caused by kinetic-energy of missiles, we sought analysis and evaluation of missile injuries of spinal cord with the application of indigenously devised Modified SKIMS-Functional Classification, SKIMS-injury types and Modified SKIMS-Functional Outcome scale.

Methods: The study was conducted retrospectively in Neurosurgery, SKIMS, single tertiary unit in Jammu and Kashmir State of India, over a period of 22 years (January 1989–December 2010). The missile injuries of spine and spinal cord were managed under a standard medical and uniform protocol. The civilians, injured due to firing of metallic-bullets, pellets, tear-gas shells etc, received within 24 h of injury. Temporary spinal immobilization, resuscitation (ABC-Guidelines), methyl prednisolone infusion and clinico-imaging evaluation were carried out. Triaging was done by indigenous Modified SKIMS-Functional Classification and SKIMS-injury types, while results assessed by Modified SKIMS-Functional Outcome scale.

Results: Among 334 spinal missile injuries, penetrating injuries were 55.08%, SKIMS-injury type-a (musculo-skeletal neural) 61.07% and metallic-bullets were commonest (69.76%) missiles causing 44.63% dorsal injuries. The Modified SKIMS-Functional Classification rapidly triaged and prognosticated spinal missile injuries. The CT-myelography was study

* Corresponding author. B-4 Faculty Quarters, Sher-i-Kashmir Institute of Medical Sciences, Srinagar 190011, Kashmir, India. Tel.: +91 9419081377.

E-mail addresses: seven_rashid@rediffmail.com (A.R. Bhat), waniafzal@rediffmail.com (M.A. Wani), kirmanialtaf@rediffmail.com (A.R. Kirmani).

^e Tel.: +91 9419000313 (mobile).

^f Tel.: +91 9419006376 (mobile).

^g Tel.: +91 9419081343 (mobile).

^h Tel.: +91 9419081385 (mobile).

ⁱ Tel.: +91 9419081142 (mobile).

of choice. The intrathecal and intramedullary missile migration, "Second-Flight of Bullet" occurred in 1.49%. About 80.83% underwent surgery. The new indigenous Trans-axillary Approach was applied in 3.33% D2-3 spinal-fixation. Meningitis and CSF leak were common. However Modified SKIMS-Functional Outcome scale showed that 47.30% (158/334) of all spinal missile injuries improved neurological grade, 14.97% (50/334) died, most of these in group A Modified SKIMS-Functional Classification, and 37.72% (126/334) patients had no improvement by the end of 6 months. Among all groups, group C was most salvageable. **Conclusion:** The prognosis of missile injuries of spine stays grim with only 7.18% (24/334) patients improved to Modified SKIMS-Functional Outcome group D (good-recovery). The multi-factorial criteria, not alone complete/incomplete injury-concept, ought to be framed in favour of or against surgery. The Modified SKIMS-Functional Classification, SKIMS-injury types and Modified SKIMS-Functional Outcome scale helped in rapid triaging and prognosticating the spinal missile injuries.

Copyright © 2012, Neurotrauma Society of India. All rights reserved.

1. Introduction

The anatomical and physiological predisposition of spinal cord is so sensitive in space and time that it demands immediate decompression of compressive elements. The management of missile injuries (high velocity – >700 m/s; low velocity – <700 m/s) of spine and spinal cord, in presence of associated injuries, was refined slowly and fearfully in war surgeries till the advances in modern technology.¹ The volley of sophisticated imaging gadgetry, presenting holistic view of spinal canal containing roots, dura, CSF and spinal cord, has encouraged the present day neurosurgeons, equipped with state of art instruments, to take daring steps in surgical and medical treatment of these injuries. Once upon a time, Harvey Cushing 1918 did not allow surgical treatment of the clinically paraplegic and quadriplegic patients, except for injuries below first lumbar level.^{2,3} But the present-leap of imaging has made us believe that even in the apparent trans-section of the spinal cord some neural-fibres and tracts may be preserved which need in-time chance-decompression to neural recovery. The mere clinical impression of complete or incomplete injury should not deter us from treating the patient either way, surgical or non-surgical. Eventually, appropriate and successful surgical procedure is guided by, not only imaging and clinical condition but also by psychological, social and economic demands of the patient. However the experience, of treating 334 missile injuries of spine and spinal cord at SKIMS, Kashmir, proves Harvey Cushing still relevant in that all patients do not need surgery in the presence or absence of associated injuries and complications.

2. Subjects and methods

This study is conducted by the department of Neurosurgery, Sher-i-Kashmir Institute of Medical Sciences (SKIMS), as a single tertiary care hospital in the state of Jammu and Kashmir. The department admitted all the cases of missile injuries of spine and spinal cord over a period of twenty two years from January 1989 to December 2010 under a standard medical and uniform protocol. The civilian spinal missile injuries, which occurred as a result of firing of metallic-bullets

and pellets from rifles, pistols, hand-guns and shotguns, splinters from bomb blasts, exploding shrapnel from shells, grenades and improvised explosive devices (IED) and firing of tear-gas shells (owing to armed conflict in the northern Indian region) were Kashmiris. Both low and high velocity missile injuries of the spine were managed. All the patients were received within 24 h of the injury. The patients on admission were resuscitated immediately by temporary spinal immobilization and ABC-guidelines (airway, breathing, bleeding, circulation, catheterization of bladder etc). The patients were allotted to Modified SKIMS-Functional System, devised at SKIMS, Kashmir. The Modified SKIMS-Functional Classification and Modified SKIMS-Functional Outcome scale for the triaging and prognostication of missile injuries of the spine, is a short, simple and quick method of clinically classifying the spinal injuries.

The Modified SKIMS-Functional Classification has 4 clinical groups as under:

Functional group	Neurological (functional) status
A	Functionally paralytic below the level of spinal injury
B	Non-functional movement (un-coordinated and useless movements without any direction and quality) on exclusion of the gravity below the level of spinal injury
C	Functionally active against gravity as well as resistance with or without support, but uncontrolled sphincters below the level of spinal injury
D	Functionally normal sphincters but mild or no functional deficit below the level of spinal injury

The Modified SKIMS-Functional Outcome Scale includes Group A, B, C, D and mortality after assessment at six months. All patients were given intravenous fluids, antibiotics and steroids. The steroids were received by all patients, except injuries below the level of L1 body, in the form of methyl

prednisolone succinate (bolus of 30.5 mg/kg infusion over 15 min followed by normal saline for 45 min and then maintenance as 5.4 mg/kg/h for next 23 h in those who were admitted within 8 h of injury. However, steroids were continued till 48 h in patients who arrived within 8–24 h after the spinal injury) except patients in SKIMS-Functional Group D. The cervical injuries were immobilized by a rigid and high collar; the dorsal spine was immobilized in a spinal jacket and lumbo-sacral region in a corset. The patients were shifted for investigations on rigid spinal-boards like a log of wood. The vital functions like consciousness, breathing, pulse rate, blood pressure, thorough neurological examination and bladder status were checked and recorded. The basic haematological and biochemical investigations were performed in all patients. All the patients were subjected to double view radiography. The plain myelography, plain reconstructive or 3-D CT-scan and CT-myelography of the spinal region was carried out in most patients. The MRI was used only in cases where patients were evaluated and found as foreign body or metal free. After the clinico-radiological evaluation, the patients were either managed surgically or conservatively. The associated injuries (trachea, oesophagus, thoracic, gut etc) were dealt with, on priority basis, by the concerned surgeons. Based on the clinical, radiological and intra-operative findings, all the spinal missile injuries were divided into two SKIMS-injury types for the outcome and mortality; Type-a) clean (musculo-skeletal neural) injuries were cases where missiles did not traverse any viscus, cavity or a solid organ but muscle, vessel or bone. While Type-b) contaminated (esophago-thoraco-abdominal neural) injuries were patients with associated organ injuries. The patients were assessed at different intervals of time using Modified SKIMS-Functional Outcome scale. The final observations were considered only at six months after the injury to spine. The results were compiled and analysed using statistical law of variance.

3. Results

A total of 334 patients had high and low velocity missile injuries of the spine and spinal cord. The perforating injuries (presence of wounds of entrance and exit) were found in 44.91% (150/334) patients and the penetrating injuries (presence of wound of entrance) in 55.08% (184/334) patients. Most of the perforating injuries were observed in straight trajectory para-spinal/para-midline site to para-umbilical site, from antero-lateral thoraco to para-spinal and latero-lateral in posterior part of neck region fracturing transverse and spinous processes of a vertebral body and subsequent cord injury. The missile trajectories in penetrating injuries were mostly anterior or posterior with oblique as well as straight trajectory. The spinal level most commonly injured was dorsal spine (41.31% = 138/334) and most common missiles were bullets and pellets, with high infective potential, in mostly young males (Tables 1–3). The longest metallic-bullet measured approx. 60 mm in length with a diameter of 12 mm in upper lumbar region causing lieno-renal and gut injury (Figs. 1–5). The decubitus ulcers and pneumonias were frequent complications. The cervical missile injuries (37.72%) comprised of 83.33% (105/126) quadriplegias and 16.66% (21/

Table 1 – Application of Modified SKIMS-Functional classification to missile injuries of spine and spinal cord at admission.

SKIMS-Functional group	Neurological (functional) status	No. = % of patients
A	Functionally paralytic below the level of spinal injury	277/334 = 82.93
B	Non-functional movement (un-coordinated and useless movements without any direction and quality) on exclusion of the gravity below the level of spinal injury	29/334 = 8.68
C	Functionally active against gravity as well as resistance with or without support, but uncontrolled sphincters below the level of spinal injury	25/334 = 7.48
D	Functionally normal sphincters but mild or no functional deficit below the level of spinal injury	3/334 = 0.89

126) quadriplegias of which 36.50% (46/126) died up to 6 months. The dorsal and dorso-lumbar missile injuries caused 39.82% (133/334) paraplegias. The preoperative mortality of 4.19% (14/334) out of all (50/334) deaths was recorded (Table 4). The most spinal injuries were SKIMS Type-a i.e. clean (musculo-skeletal neural) spinal injuries = 61.07% (204/334). The rest were SKIMS Type-b i.e. contaminated (esophago-thoraco-abdominal neural) spinal injuries (Table 5).

4. Investigations

All patients were subjected to plain radiography in antero-posterior and lateral views, although oblique views were achieved in special circumstances. The X-rays helped in ascertaining the level and column of bony injury and also

Table 2 – Age, sex and the mortality in spinal missile injuries.

Age in years	Number of patients (cases)	Males	Females	Children ^a	Deaths
0–10	2	0	0	2	0
11–20	62	34	2	26	8
21–30	182	176	6	0	28
31–40	58	58	0	0	12
41–50	22	22	0	0	2
Above 50	8	8	0	0	0
Total	334	298	8	28	50

a Children: aged 18 years and below.

Table 3 – Associated injuries and complications related to level of spinal missile injuries.

Spinal level	No. of patients	Associated injuries							Major complications					
		Tracheo-oesophageal	Lungs	Thoracic	Hepatobiliary	Gastro-intestinal	Genito-urinary	Spleen	CSF leak	Meningitis	Septicaemia	Faecal fistulas	Urinary fistulas	
Sub-Atlas cervical region														
C2-C4	24	0	0	0	0	0	0	0	14	10	2	0	0	
C5-C6	62	4	0	0	0	0	0	0	30	22	16	0	0	
Cervico-dorsal Junction														
C7- D1	40	2	0	7	0	0	0	0	6	4	24	0	0	
Dorsal region														
D2-6	74	0	18	22	6	0	0	0	10	0	42	0	0	
D7-11	64	0	34	0	2	6	0	2	14	0	24	0	0	
Dorso-lumbar junction														
D12-L1	52	0	0	0	0	16	6	0	6	2	10	4	0	
Lumbar region														
L2-5	14	0	0	0	0	3	0	0	2	0	4	0	2	
Sacral	4	0	0	0	0	0	2	0	0	0	2	0	2	
Total	334	6	52	29	8	25	8	2	82	38	124	4	4	

*All cases of craniovertebral junction (including odontoid) were excluded from the study.

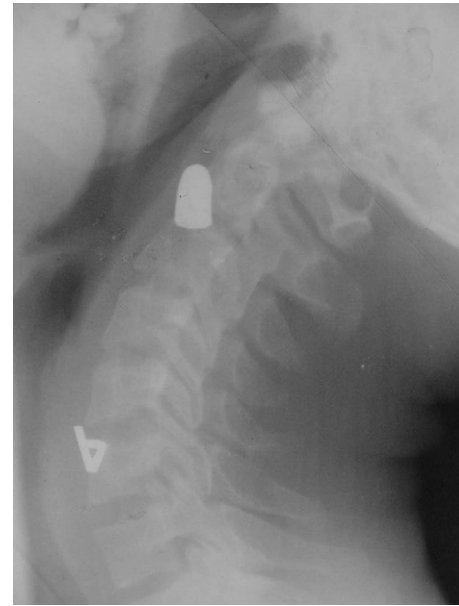

Fig. 1 – Plain X-ray cervical spine showing a metallic-bullet lodged at C2–3 vertebral bodies.

ensured if the patient was foreign body (metallic)-free in case MRI was necessary (Figs. 1–3). More than two-thirds (230/334) of all the patients underwent initial plain, reconstructive and 3-D CT scanning of the inflicted region to assess the depth of missile and bony fragments and also to rule out multi-organ injuries (Figs. 4–6). However, CT-scan was converted into CT-myelography urgently in about 30% (70/230) of these to rule out neural compression. The early and delayed CT-myelography was performed in 87.12% (291/334) of all

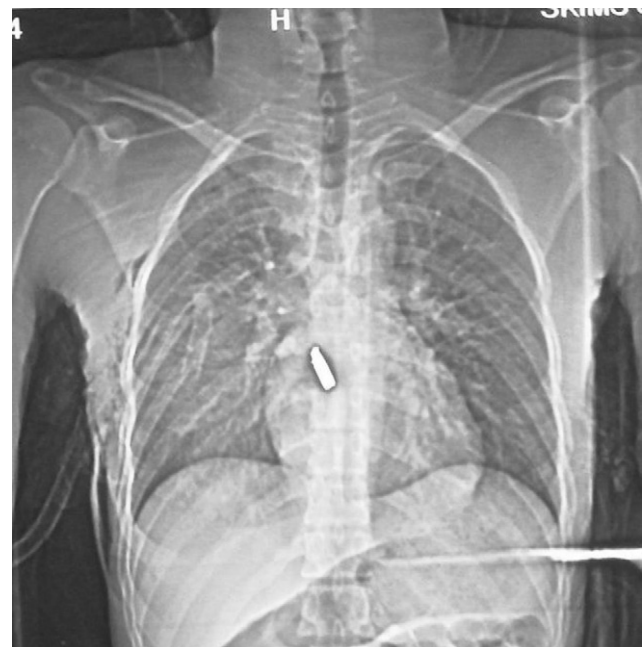

Fig. 2 – Plain X-ray dorsal spine reveals a metallic-bullet at D6–7 level.

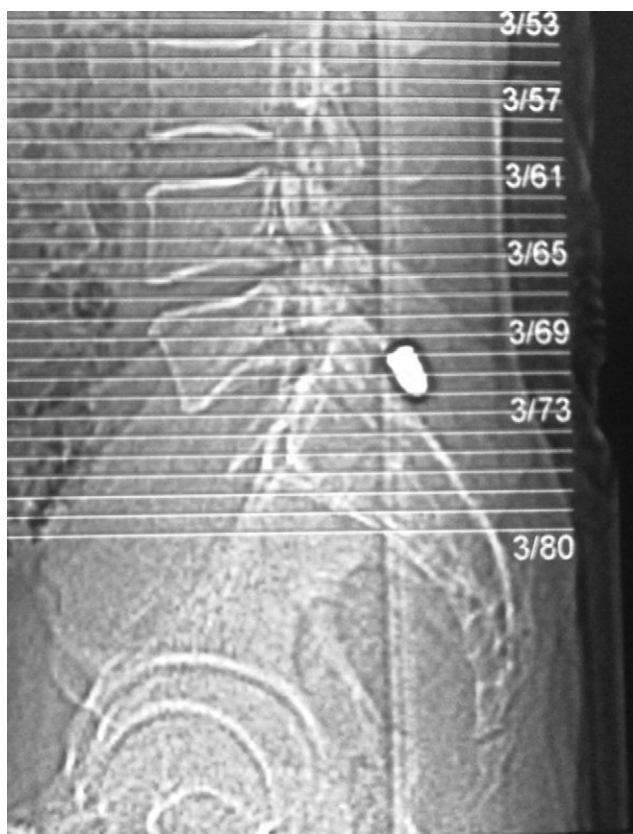

Fig. 3 – Digital view of lumbo-sacral spine depicts a metallic-bullet at S1 laminar level.

missile injuries. The anatomical location of missiles, their tracks, osseous and neural damage was well ascertained by CT-myelography (Fig. 7). The metallic and non-metallic-bullets, splinters, bone and missile projectiles, trapped air and debris could be detected on the CT-myelography. The plain myelography defined the anatomical compression or

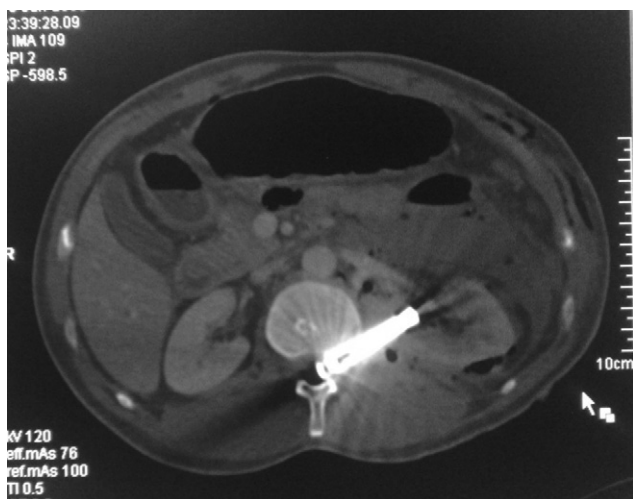


Fig. 4 – Axial view of plain CT-scan of upper lumbar spine shows metallic-bullet (approx 60 mm long) embedded in spinal canal and pedicle of vertebra in a paraplegic patient.

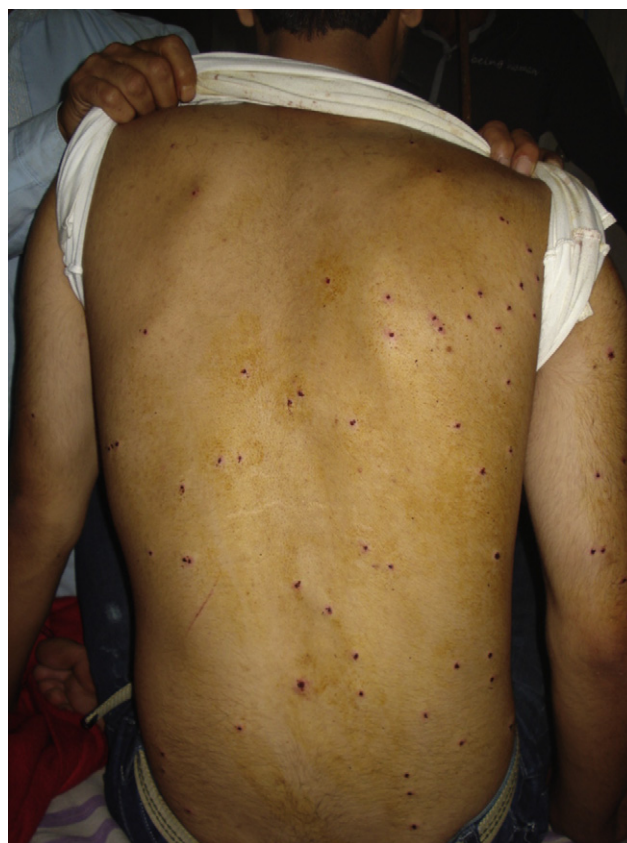

Fig. 5 – Clinical photograph of a multiple pellet injury patient fired from shotgun.

continuity of the cord (Fig. 8). The spinal MRI in presence of metallic missile injuries was not possible (fear of potential neural damage and missile migration) except in 8.68% [29/334] patients whose radiography and plain CT-scanning did neither show any metallic foreign bodies nor any skeletal abnormalities. And of these 89.65% (26/29) i.e. 7.78% (26/334) of all spinal missile injury patients had intramedullary contusions and 0.89% (3/334) had apparently normal imaging. The cord contusions were caused by remote effects of missile cavitation and blast waves leading to radial churning of cord tissue. About 50.00% (167/334) patients had two column injury and 29.04% (97/334) had one column injury while 12.27% (41/334) patients had three column injury.

5. Intrathecal and intramedullary missile migration (second-flight of a bullet)

There were 1.49% (5/334) patients of intra-spinal missile migration (Figs. 9 and 10). The two of these patients were wounded by shotgun with multiple pellet injuries, one of them in cervical spine and the other one in dorsal spine. The pellet migration was detected on the plain radiographs which were asked after complaint of shifting of radicular pain which the patients rated as mild. However these were managed conservatively. Among the rest were one bullet injury to cervical spine and two dorsal spine bullet injuries. The cervical

Table 4 – Modified SKIMS-Functional Classification and mortality related to type of missile injury at different spinal levels.

Spinal region	No. of patients	Missile type				Modified SKIMS-Functional classification groups at admission				Deaths
		Bullet	Splinter	Tear-gas shell	Pellet	A	B	C	D	
Sub-Atlas cervical region										
C2–C4	24	11	7	4	2	22	2	0	0	14
C5–C6	62	48	5	3	6	50	12	0	0	28
Cervico-dorsal junction										
C7–D1	40	28	8	0	4	33	6	1	0	4
Dorsal region										
D2–6	74	54	6	0	14	64	3	7	0	3
D7–11	64	50	12	0	2	58	2	4	0	1
Dorso-lumbar junction										
D12 - L1	52	36	10	0	6	45	2	5	0	0
Lumbar region										
L2–5	14	4	4	2	4	5	2	7	0	0
Sacral	4	2	0	0	2	0	0	1	3	0
Total	334	233	52	9	40	277	29	25	3	50

*4.19% (14/334) injuries died preoperatively and 10.77% (36/334) postoperatively.

*Of all pellet and splinter injuries 34.04% (32/94) had multiple pellets and splinters.

bullet migrated intra-theccally from C4-5 disc space, in which it was lodged, to C7 body level. The patient developed progressive neurodeficit from Modified SKIMS-Functional Classification Group B to Group A in the process of investigations. The patient underwent surgical removal of the bullet and dural repair. One of the dorsal missile injury patients with dorsal 3rd vertebral level intra-spinal bullet underwent intra-operative fluoroscopy for confirmation, however the projectile was found to be lying at lumbar 2nd vertebral body level and it was removed by laminectomy. The fifth case of intra-spinal migratory missiles was a 15-year-old paraplegic male child who was hit in upper dorsal region by a stray bullet, fired, from about 300 m away, by a self-loading rifle. The clinical examination showed an entrance wound, in the upper interscapular midline area, at the spinous process of 4th dorsal vertebra. However plain CT and CT-myelogram showed a metallic foreign body (bullet), pointing caudally in the centre of dorsal spinal cord at D10–11 level, with its long axis in sagittal direction (Figs. 9 and 10). But, surprisingly, on operation table the X-rays and surgical exploration revealed presence of 30 mm long bullet lodged in central canal of spinal

cord (intramedullary bullet) at D12–L1 vertebral body level (Figs. 11 and 12). Since the bullet was caught in the act of migration on CT-myelogram, the migration process was called “Second-flight of a Bullet” in the body. The missile migrations took place mostly via intra-dural and extra-dural spaces but the intramedullary migration like this one was rare. The causes of missile migration were gravity, CSF and cord pulsations, tissue necrosis (in delayed removal) around the projectile, frictionless slimy surface of the bullet and potential and negotiable CSF-laden central canal of spinal cord in rare cases.

6. Intra-discal bullets

About 1.19% patients (4/334) had intra-discal location of bullets and one of these migrated. All the intra-discal bullets were removed, 2 by laminectomy in the lower lumbar region, one in cervical region by anterior corpectomy and another one through antero-lateral thoracotomy in the dorsal region.

Table 5 – SKIMS types of penetrating and perforating spinal missile injuries and relation to Modified SKIMS-Functional classification at admission.

Modified SKIMS Group	SKIMS-injury type-a	SKIMS-injury type-b	No. of cases with neural recovery	No. of cases with no change in neurodeficit	Deaths
A	201 (61.07%)	76 (22.75%)	129	105	43
B	0	29 (8.68%)	6	18	5
C	0	25 (7.48%)	23 (92%)	0	2
D	3	0	0	3	0
Total	204 (61.07%)	130 (38.92%)	158	126	50

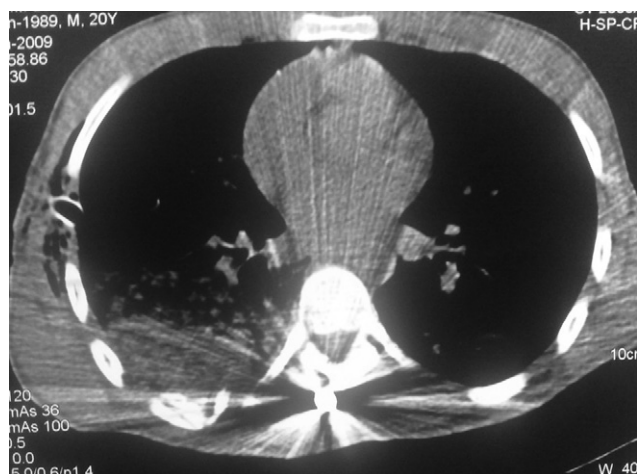

Fig. 6 – Plain CT-scan of upper dorsal spine reveals subcutaneous emphysema, pneumothorax, lung contusion and shattered vertebral lamina and canal in a missile injury patient.

6.1. Management

All patients were given intravenous fluids, antibiotics, steroids, bladder catheterization, skin and joint care. The spinal-boards were used to shift and transport patients and temporary spinal immobilization was provided by the orthoses and orthotic support while planning for definitive stabilization.

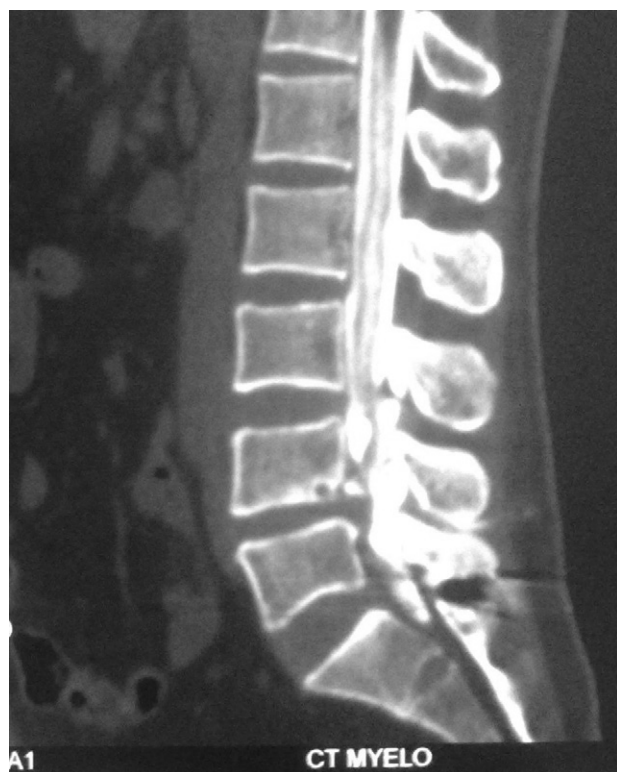

Fig. 7 – CT-myelogram in sagittal reconstruction of a missile victim depicting disruption of L5 lamina and myelo-block downwards from L4 vertebral level.

About one-fifth ($64/334 = 19.16\%$) of all spinal missile injuries were managed conservatively. These patients had no bony abnormalities, no instability, no CSF leaks or fistulas, 7.78% ($26/334$) had intramedullary contusions without bony fractures, no retained missile fragments in cervical, dorso-lumbar junction and lumbo-sacral region and were having either complete neurodeficit or a mixed sensory-motor and incomplete deficit.

6.2. Surgical management

The surgical intervention was performed on 80.83% ($270/334$) patients of spinal missile injuries (Table 6 and 7). All the lumbo-sacral injuries and more than 86% cervical injuries underwent surgical treatment. The indications of surgery were; progressive neurological deterioration in incomplete injuries from higher grade to lower or Modified SKIMS-Functional Classification Group C and B to A, all incomplete and complete injuries with spinal cord compression, CSF leaks and fistulas, spinal instability, pneumo-myelia, retained missiles, missile and bone fragments in the dorso-lumbar junction (cauda equina) and bleeding missile tracks, migrated projectiles and intra-discal bullets (Figs. 11 and 12). An incomplete or complete spinal injury without above associations was conservatively managed. The aims of surgery were; to hope for the improvement in the neurological grade of incomplete spinal injuries; recovery or improvement in complete spinal injuries; to avoid wound infection, CSF leaks and fistulas and meningitis; to prevent spinal abscess and osteomyelitis and to rehabilitate the patients by preventing spinal deformity, gibbus formation and chronic pain. The scope of surgery was; to do a complete debridement of missile track; removal of accessible missile and bone fragments from the spinal canal; decompression of spinal cord; spinal stabilization; dural repair and duroplasty. However, spinal cord was

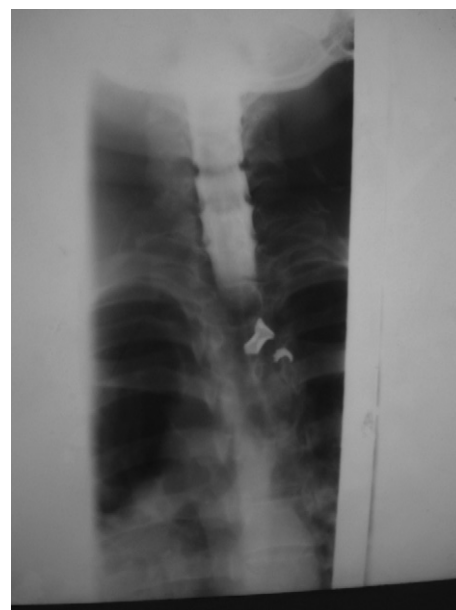

Fig. 8 – Plain myelogram of a patient displays myelo-block due to splinter injury at cervico-dorsal junction.

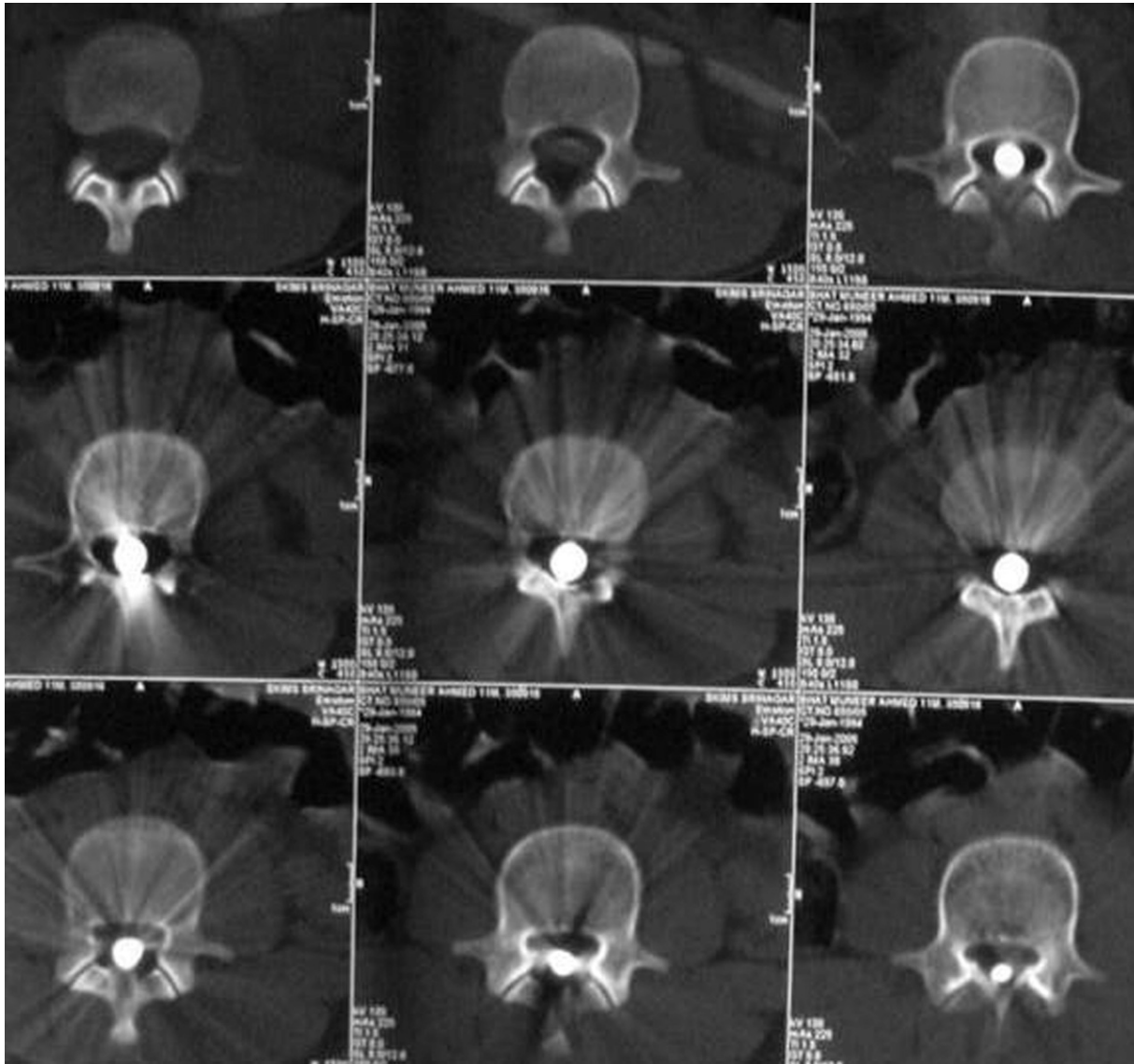


Fig. 9 – Plain axial CT-scan reveals, Second-Flight of a Bullet, process of migration of a metallic-bullet with its long axis sagittally inside lower dorsal spinal canal (See Fig. 10).

not visualized in patients where dura was intact or dura was torn in absence of intra-dural retained missile and bony projectiles.

6.3. Mortality

An overall mortality of 14.97% (50/334) was recorded and most of these, 12.87% (43/334), occurred in the Modified SKIMS-Functional Classification Group A as compared to B and C groups. The average length of hospital stay of all patients was 21 days and it ranged from as short as 7 days in some cases to as long as 119 days in others.

6.4. Outcome

The Modified SKIMS-Functional Outcome scale was used to assess the neurological condition of patients and final observations were recorded at six months after the spinal missile

injury (Table 8). Among all groups, Group C was most (92%) salvageable.

6.5. Discussion

Since the spinal canal (containing dura, CSF, spinal cord and its roots) is ventrally covered by the air-filled and food-product containing hollow, tubular and solid organs like nasopharynx, oral cavity, oropharynx, larynx, oesophagus, trachea etc and dorso-laterally by the muscular, skeletal and vascular components, so the spinal missile injuries were divided into two SKIMS-injury types; a) Clean spinal (musculo-skeleto neural) injuries = 61.07% (204/334) and b) Contaminated spinal (esophago-thoraco-abdomino-neural) injuries = 38.92% (130/334). By this division, from the type-a (clean) spinal injuries 61.07%, about 60.17% (201/334) were bad/worst admission grade classified as Group A of Modified SKIMS-Functional Classification and had 5.88% (12/204) deaths. While 0.89% (3/334) type-a spinal

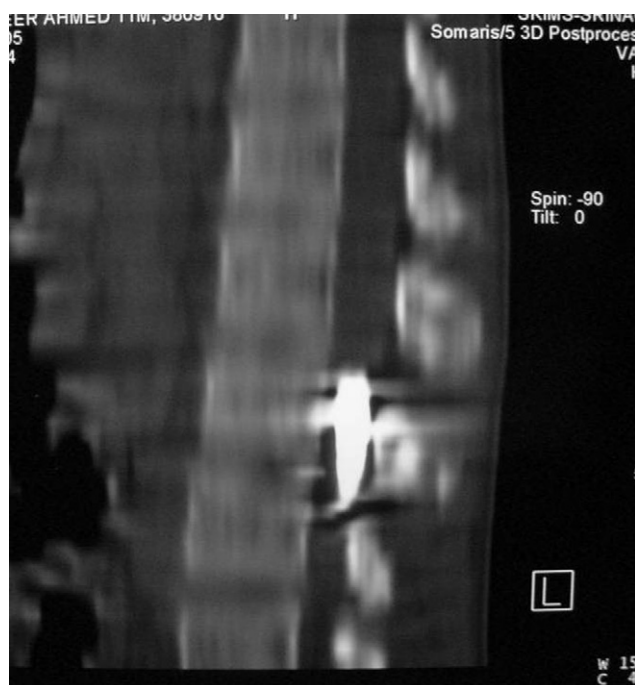


Fig. 10 – CT-scan sagittal reconstruction shows, Second-Flight of a Bullet, a metallic-bullet of 3° mm long × 10 mm dia. in the process of migration inside lower dorsal spinal canal (See Fig. 9).

injuries were Group D Modified SKIMS-Functional Classification. Of all type-b or contaminated spinal injuries 38.92%, about 22.75% (76/334) patients were in Modified SKIMS-Functional Classification Group A and had a mortality of 40.79% (31/76). The rest, 16.16% (54/334), were in Modified

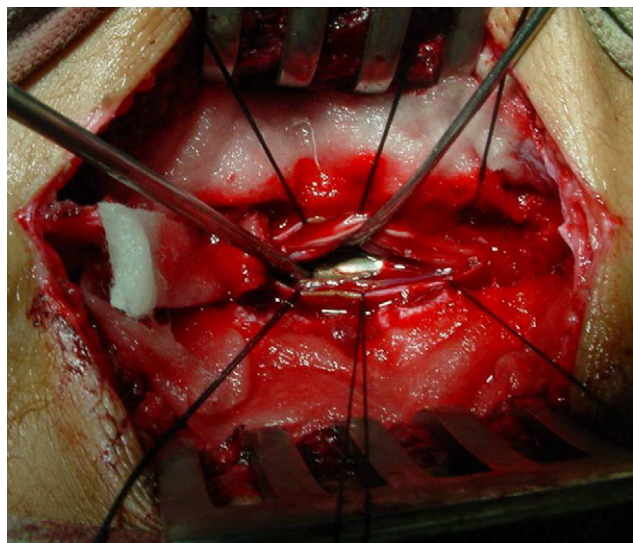


Fig. 11 – An intra-operative photograph, post-laminectomy, shows the metallic-bullet embedded within the spinal cord at L1 level.

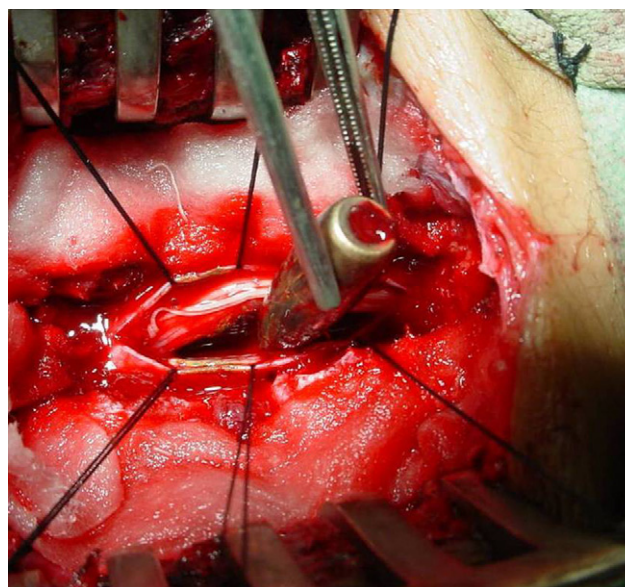


Fig. 12 – An intra-operative photograph showing removal of a metallic-bullet from within the spinal cord.

SKIMS-Functional Classification Group B and C with a mortality of 12.96% (7/54).

6.6. Incidence

The gunshot wounds of the spinal cord account for 13–17% of all spinal cord injuries every year. These injuries are reported to occur most commonly in dorsal region and in young males.^{4–8} Gunshot wound is the second commonest cause of the spinal cord injury (SCI) in USA after the road traffic accident⁸. In Italy latest epidemiological data shows that ballistic injuries to spine comprise 1% of all spinal cord trauma.⁹ In a study of 22 cases of spinal missile injuries, there were 18% bullet injuries, 66% > one splinter.¹⁰ A retrospective study on Croatian spinal injuries, in 96 patients in four years period, showed mean age for civilian injuries as 38.5 years and soldiers as 28.5 years with an overall range of 15–59 years. However most patients, 55%, had injuries in lumbar spine and only 17.7% had cervical and dorsal injuries. The most common, (51%), types of missiles were projectiles fired from automatic rifles and sniper; explosive devices 39% and blast injuries 10%.¹¹ However a previous study of Croatian civil war reported that most of the patients were injured due to exploding shells and all patients had postoperative neurological.¹² In SKIMS, the metallic-bullets were the most common type of missiles (69.76%) causing spinal injuries especially in the dorsal region (44.63%), followed by cervical spine (25.32%). The metallic splinters (15.56%) and lead pellets (11.97%) were the next common missile injuries and the dorsal spine injuries outnumbered all other regions in both missile types i.e. splinters (34.61%) and pellets (40.00%). The young males were most common victims. All the patients were triaged according to the Modified SKIMS-Functional Classification in four groups A, B, C and D. Most of the patients (82.93%) were found to fit in the worst neurological Group A.

Table 6 – Types of surgical procedures and approaches in 270 spinal missile injuries.

Procedure	Location	Approach	No. of patients
1. Decompressive Corpectomy and >inter-body fusion/fixation	C2–C6 bodies	Anterior cervical	28
	C7–D2 (cervico-dorsal junction)	Lateral clavico-sternotomy	7
	D2–D3	(a) ^a Trans-axillary (through axillary-pit between 2nd and 3rd ribs)	9
		(b) Midline sternotomy	4
	D3–D11	^b Modified poster-lateral Inter-costal/Rib-resection extra-pleural approach	44
	D12–L4	Modified postero-lateral extra-pleural retro-peritoneal	10
2. Non-decompressive posterior trans-pedicular fixation	L5, S1	Percutaneous posterior midline	11
3. Decompressive laminectomy and laminotomy	Any level	Posterior midline	133 (49.25%)
4. Missile tack debridement and haemostasis	Any level	Locally	24
Total			270

a An indigenous and special Trans-Axillary Approach (laterally between second and third ribs; indigenously developed and usually used for D2 tubercular spondylitis).

b Though closed suction drains and chest tubes were used in all surgically treated cases but no specific lumbar drains for CSF diversion were used in any case.

6.7. Associated injuries

The present study at SKIMS observed that the lungs were the most common, (15.56%), injured organ in association with spinal missile injury, that is about 40.00% among associated injury group. The lungs were mostly injured in lower dorsal region i.e. D7–D11 (65.38%). The next common injury occurred to the thoracic cavity (8.68%), more so in the upper dorsal region i.e. D2–D6 (75.86%). However, of all (7.48%) gastrointestinal tract injuries, most (64.00%) were associated with the dorso-lumbar junctional (D12–L1) injuries. Other associated injuries like tracheo-oesophageal, Hepatobiliary, genito-urinary and splenic were less common (Table 3). A

series of 22 cases of spinal missile injuries reported 31% associated injuries.¹⁰ The authors of a study reported 114 patients with 23.7% having gut injury. The surgical treatment significantly increased wound and spinal infections while the patients on conservative treatment for GI tract injury, did well.¹³

6.8. Investigations

The present SKIMS study avoided general use of MRI in spinal missile injuries for the reasons of fear of potential neural damage and missile migration. The early and delayed CT-myelography was performed in 87.12% (291/334) of all

Table 7 – Management and Modified SKIMS-Functional outcome scale.

Spinal level	No. of cases	Management		Modified SKIMS-Functional Outcome scale – 6 months post-missile injury spine				
		Conservative	Surgical	Group A	Group B	Group C	Group D	Mortality
Sub-Atlas cervical region								
C2–C4	24	4 ^a	20	5	3	1	1	14
C5–C6	62	8	54	8	5	17	4	28
Cervico-dorsal junction								
C7–D1	40	10 ^a	30	22	6	7	1	4
Dorsal region								
D2–D6	74	16 ^a	58	47	7	14	3	3
D7 D11	64	8	56	35	8	16	4	1
Dorso-lumbar region								
D12–L1	52	18 ^a	34	26	7	15	4	0
Lumbar Region								
L2–L5	14	0	14	0	1	10	3	0
Sacral	4	0	4	0	0	0	4	0
Total	334	64 (19.16%)	270 (80.83%)	143 (42.81%)	37 (11.07%)	80 (23.95%)	24 (7.18%)	50 (14.97%)

a 7.78% (26/334) spinal missile injury patients had intramedullary contusion without any skeletal injury and were managed conservatively.

Table 8 – Outcome and mortality of 334 spinal missile injuries.

No. of missile injuries of spine	Modified SKIMS-Functional outcome scale				Deaths	Total
	A	B	C	D		
At Admission	277	29	25	3	–	334
No change in neurodeficit at 6 months	105	18	0	3	–	126
Deaths	43	5	2	0	50	50
Neurological improvement at 6 months	129	6	23 (92.0%)	0	–	158
Group total at 6 months	105	75	80	24 (7.18%)	50	334

missile injuries. A study shows that the myelogram was performed on 18%, CT-myelogram on 50% and MRI on 18% of spinal missile injuries.¹⁰ The reporters have advised to obtain double orthogonal plain radiographs of the spine to detect missile fragments and fractures of vertebrae followed by CT-scan which is the study of choice for precise localization of bullets and bone fragments. However MRI is not used for the potential neural damage it might cause.^{14,15} The Croatian war study observed that diagnostic tools of choice were plain radiography, computed tomography and computed tomography myelography.¹¹

6.9. Treatment

The treatment of these injuries is dictated by the clinical, radiological, socio-economical and psychological demands and needs of the patients. This study included several young patients from both sexes who developed behavioural disorders and anti-psychotics did not improve their condition. These were deeply depressed and mere surgery, an indicated procedure, did not help them to get ready for postoperative physiotherapy, a must activity. The complete or incomplete injury-concept must not be the lone factor in decision making for management of spinal missile injuries. A cavitation injury of cord with dural tear and CSF fistula, caused by closely traversing bullet, needs surgery in an apparently normal looking cord with complete injury. About one-fifth (19.16%) of all spinal missile injuries at SKIMS were managed conservatively. These patients had no bony abnormalities, no instability, no CSF leaks or fistulas, no retained missile fragments in cervical, dorso-lumbar junction and lumbo-sacral region, but had intramedullary contusions (7.78%) without any bony fractures and were having either complete neurodeficit or no deficit at all. The surgical intervention was performed on 80.83% patients of spinal missile injuries (Table 7). A study reported that conservative treatment was given to 9% and operative treatment to 77% while all patients were put on the steroids.¹⁰ According to North Atlantic Treaty Organization (NATO) doctrine, indications for the surgical treatment of war spinal injuries are progressive neurologic deficit and spinal instability.¹⁶ The authors of a study followed advocates of the

view that war spinal injuries should be treated conservatively.¹¹ Although other investigators opine that patients with progressive or new-onset neurologic deficit with a radiologically identifiable cause like missiles, bones, haematomas should be treated with urgent decompression. The indications for surgery include persistent CSF leak, dural tear to avoid meningitis and lead intoxication^{6,14,17–20} Studies performed on soldiers wounded in combat zones, where the majority of injuries are high energy, have shown surgical debridement as the most efficacious factor in preventing secondary complications^{12,21} A study on 65 cases of bullet injuries reported no difference in conservative and surgical management.²² While other study indicates surgery an option in all cases.²³ Some advise surgery for partial neurodeficit or incomplete injury as essential for neurological recovery, however management for complete injury is debatable in their view.²⁴ It is reported that surgical exploration for removal of retained missiles and bone fragments in cauda equina injuries for the recovery of roots is mandatory, but primary and severe spinal cord injury do not stand a chance in the worse admission neurological grade. However decompression of even one root in cervical cord makes a lot of difference in rehabilitation^{11,22,23,25,26} The SKIMS study observed that an indigenous and special technique of Trans-Axillary Approach (between second and third ribs) was used to decompress the D2, 3 vertebral bodies with corpectomy and fixation in 3.33% patients. The 28% patients of Croatian war were treated surgically and 72% conservatively, broad spectrum antibiotics were used in all patients.¹¹ It was revealed in a series of 24 spinal missile injuries with neurodeficit that half of these were operated and half managed conservatively. The 50% of those operated improved neurologically and 25% died, while 66.66% of conservatively managed patients improved neurologically and none had died.²⁷ The trans-sectioned spinal cord was not being operated upon unless injury occurred below L1.² An author does not give steroids and projectile migration rare.²⁸ At SKIMS, the Modified Postero-lateral Trans-thoracic Trans-pleural Approach was used for the dorsal bodies of third to eleventh vertebrae. The dorso-lumbar junction (D12–L1) and lumbar 2nd and 3rd bodies were approached through Modified Postero-lateral Extra-pleural Retro-peritoneal Approach.

7. Missile migration or Second-Flight of Bullet

While reviewing literature for migratory missiles, Moon et al. advised to remove intra-spinal/intrathecal bullets to avoid lead toxicity and continuous nerve rootlet micro-trauma and irritation.²⁸ The retained bullet fragments should be removed surgically if progressive and worsening neurodeficit occurs or if fear of missile migration is there.²⁹ The causes of missile migration are gravity, CSF and cord pulsations.³⁰ The retained accessible projectiles were removed because intrathecal migration of missiles can lead to neurodeficit due to hemorrhages and physical pressure. The present SKIMS study detected one intact missile (Bullet) in live migration through potential-path of central canal of spinal cord and hence was called Second-Flight of Bullet (Figs. 8 and 9). However removal of small pellets of 2–3 mm size could produce more iatrogenic

(surgical) neurodeficit than recovery so were left alone. But all four (1.19%) patients of intra-discal bullets were subjected to surgery for projectile removal. The process of migration of bullets could be suspected and detected as soon as neurodeficit sets in (Figs. 9 and 10).

8. Complications and mortality

The present study recorded an overall mortality of 14.97%. The cervical spine missile injuries had 48.83% deaths. The average hospitalization length was 21 days with a range of 7–119 days. The length of stay in SKIMS patients and mortality was increased due to cervical and dorsal cord injury and projectile most involved being bullet and fatal postoperative complications. Among major complications (75.44%), the most frequent was septicaemia (49.20%). This was followed by CSF fistulas (32.53%). The meningitis was also common (15.07%). The urinary and faecal fistulas were found in the lumbo-dorsal, lumbar and sacral regions only (Table 3). The decubitus ulcers and pneumonias were frequent complications. Although there are reports of no CSF leak and no meningitis in one study of 22 cases.¹⁰ But in another study of 153 patients, the wound infection is reported in 9.8%, retained bullet related infection 7.4%, penetrating track infection 12.5% and 8.4% spinal infection in associated colonic injuries. These authors believe that retained bullets in the spine are not a significant risk factor for the development of local septic complications.³¹ It is also reported that septic complications after gunshot wounds of the spine, such as osteomyelitis, meningitis, intra-thoracic or intra-abdominal abscess, often lead to catastrophic consequences.²⁵ The authors of a series doubt whether factors like site of injury, retained bullets and a bullet passing through colon are full of risk in promotion of sepsis or not.^{32–34} The mortality of Croatian war patients was 4.16% with a 17 day average length of hospital stay and a range of 14–93 days. The complications noted were wound infection, urinary tract infection, decubitus ulcers and pneumonias.¹¹ The reported operative mortality is as less as 1%.³⁵ The author of a study revealed total 18% death of which, 13% occurred preoperatively and 4.6% postoperatively.¹⁰ Others reported 25% operative deaths and no deaths in conservatively treated group.²⁷ In Vietnam war aggressive surgical methods paid in improvement of mortality.³ At SKIMS, the doubt and debate about the sterility of a bullet passing through colon into the spinal cord is not as important as is the demonstrable fistulous bullet-track causing fatal spinal infection. Moreover bullets have been associated with reasonably high damaging and infective potential. Whether biological (to induce or increase infectivity) and explosive warfare has been mingled together, by the manufacturers, to leave the target (victim) absolutely irreparable is not known. Why the immune breakdown, of the subjects is so quick to let infection grow into septicaemia, is debatable.

9. Outcome

The Modified SKIMS-Functional Outcome Scale noted a total of 47.30% spinal missile injuries improved their neurological

grade and 14.97% died, by the end of 6 months. The 37.72% patients had no improvement and survived in severe handicap. The Modified SKIMS-Functional Outcome in missile injuries of spine showed that Group C and D had the best prognosis with improvement in 23 out of 25 patients and no deterioration in Group D (3 patients) respectively. The post-operative improvement of 15 patients to group D from group A was noteworthy. Of the all groups, Modified SKIMS-Functional group A was most affected by the mortality with 15.52%. A study noted 82% quadriplegics, 18% partial deficits and 9% intramedullary contusions.¹⁰ About 43% of Croatian war injury patients survived with severe disability.¹¹ Waters and Adkins in a review of 90 patients stated that bullet removal from D12 to L5 level led to significant neurologic motor improvement.³⁶ Yoshida and Lindsey suggested that bullet removal from upper lumbar region may not produce pain-reduction or sensory improvement but may significantly influence motor recovery.^{8,37}

10. Conclusion

The precarious, vulnerable position and vascularity of the spinal cord inside the bony rigid spinal canal is such that its very anatomical integrity and physiological functions are vulnerable and threatened due to dissipation of kinetic energy of low and high velocity missiles, leave alone devastation caused by physical injury of missiles. The short and simple Modified SKIMS-Functional Classification, SKIMS-injury types and Modified SKIMS-Functional Outcome scale helped rapid triaging and prognosticating the spinal missile injuries. The new and indigenous Trans-Axillary Approach to D2, 3 bodies for fixation is a novel approach. The multi-factorial criteria, not alone complete/incomplete injury-concept, ought to be framed in favour or against surgery. The rapidly progressing, precise and accurate technological advances may lead hopefully to better answer to these injuries tomorrow.

Conflicts of interest

All authors have none to declare.

Acknowledgement

Sincere thanks to Huwa, Aisha, Saim, Imam and Adam for their assistance.

REFERENCES

1. Barach E, Tomlanovich M, Nowak R. Ballistics: a pathophysiologic examination of the wounding mechanisms of firearms: part 1. *J Trauma*. 1986;26:225–235.
2. Surgeon General: US Army Medical Department: Review of War Surgery. 1918; 1 (5).
3. Jacobson SA, Bors E. Spinal cord injury in Vietnamese combat. *Paraplegia*. 1970;7:263–281.

4. Benzel EC, Larson SJ. Functional recovery after decompressive spine operation for cervical spine fractures. *Neurosurgery*. 1987;20:742–746.
5. Farmer JC, Vaccaro AR, Balderston RA, Albert TJ, Cotier J. The changing nature of admissions to a spinal cord injury center: violence on the rise. *J Spinal Disord*. 1998;11:400–403.
6. Bishop M, Shoemaker WC, Avakian S, et al. Evaluation of a comprehensive algorithm for blunt and penetrating thoracic and abdominal trauma. *Am Surg*. 1991;57:737–746.
7. Isiklar ZU, Lindsey RW. Gunshot wounds to the spine. *Injury*. 1998;29:SA7–SA12.
8. Yoshida GM, Garland D, Waters RL. Gunshot wounds to the spine. *Orthop Clin North Am*. 1995;26:109–116.
9. Barros TEP, Zigler J, Aito S, Di Lorenzo N, Wing P. Gunshot wound to the spine. *Spinal Cord*. 2001;39:541–544.
10. Bhatoe HS, Singh P. Missile injuries of the spine. *Neurol India*. 2003;51:507–511.
11. Jankovic S, Primorac D, Busic Z. Spine and spinal cord war injuries during the war in Croatia. *Mil Med*. 1998;163:847–849.
12. Splavski B, Vrankovic D, Saric G, Blagus G, Mursic B, Rukovanjski M. Early management of war missile spine and spinal cord injuries: experience with 21 cases. *Injury*. 1996;27:699–702.
13. Quigley KJ, Place HM, Cannada LK, Toohey J. The role of debridement and antibiotics in gunshot wounds to the spine. *J Trauma*. 2006;60:814–820.
14. Bono CM, Heary RF. Gunshot wounds to the spine. *Spine J*. 2004;4:230–240.
15. Bashir EF, Cybulski GR, Chaudhri K, Choudhury AR. Magnetic resonance imaging and computed tomography in the evaluation of penetrating gunshot injury of the spine. Case report. *Spine*. 1993;18:772–773.
16. Bowen TE, Bellamy RF. *Emergency War Surgery. Second US Revision of the Emergency War Surgery NATO Handbook*. Washington, DC: US Government Printing Office; 1988.
17. Roffi RP, Waters RL, Adkins RH. Gunshot wounds to the spine associated with a perforated viscus. *Spine*. 1989;14:808–811.
18. Romanick PC, Smith TK, Kopaniky DR, Oldfield D. Infection about the spine associated with low-velocity-missile injury to the abdomen. *J Bone Joint Surg Am*. 1985;67:1195–1201.
19. Grogan DP, Bucholz RW. Acute lead intoxication from a bullet in an intervertebral disc space. A case report. *J Bone Joint Surg Am*. 1981;63:1180–1182.
20. Linden MA, Manton WI, Stewart RM, Thai ER, Feit H. Lead poisoning from retained bullets, pathogenesis, diagnosis and management. *Ann Surg*. 1982;195:305–313.
21. Parsons TW, Lauerman WC, Ethier DB, et al. Spine injuries in combat troops-Panama, 1989. *Mil Med*. 1993;158:501–502.
22. Yashon D, Jane JA, White RJ. Prognosis and management of spinal cord and cauda equina bullet injuries in sixty five civilians. *J Neurosurg*. 1970;32:163–170.
23. Stauffer ES, Wood RW, Kelly EG. Gunshot wounds of the spine: the effects of laminectomy. *J Bone Joint Surg Am*. 1979;61-A:389–392.
24. Jacobs GB, Berg RA. The treatment of acute spinal cord injury in war zones. *J Neurosurg*. 1971;34:163–167.
25. Benzel E, Hadjen TA, Coleman JE. Civilian gunshot wounds to the spinal cord and cauda equina. *Neurosurgery*. 1987;20:281–285.
26. Hammoud MA, Haddad FS, Moufarij NA. Spinal cord missile injuries during the Lebanese civil war. *Surg Neurol*. 1995;43:432–442.
27. Tandon SC, Goel SC, Srivastava A, Mohanty S, Gupta SK. Missile injuries of the spine and spinal cord. *Ind J Orth*. 1984;18:93–97.
28. Moon E, Kondrashov D, Hannibal M, Hsu K, Zucherman J. Gunshot wounds to the spine: literature review and report on a migratory intrathecal bullet. *Am J Orthop*. 2008;37:E47–E51.
29. Waters RL, Sie IH. Spinal cord injuries from gunshot wounds to the spine. *Clin Orthop Relat Res*. 2003;408:120–125.
30. Bhat AR, Wani MA, Kirmani AR, et al. Disaster management of civilian gunshot head wounds in north Indian State. *Ind J Neurotrauma*. 2009;6:27–42.
31. Velmahos G, Demetriades D. Gunshot wounds of the spine: should retained bullets be removed to prevent infection? *Ann R Coll Surg Engl*. 1994;76:85–87.
32. Bricker DL, Waltz TA, Telford RJ. Major abdominal and thoracic trauma associated with spinal cord injury. *J Trauma*. 1971;11:63–75.
33. Jones RE, Bucholz RW, Schaefer SD, Mumme M, Carder HM. Cervical osteomyelitis complicating transpharyngeal gunshot wounds to the neck. *J Trauma*. 1979;19:630–634.
34. Yashon D. Missile injuries of the spinal cord and cauda equina. In: Yashon D, ed. *Spinal Injury*. New York: Appleton–Century-Crofts; 1986:285–305.
35. Wannamaker GT. Spinal cord injuries: a review of the early treatment in 300 consecutive cases during the Korean conflict. *J Neurosurg*. 1954;11:517–524.
36. Waters RL, Adkins RH. The effects of removal of bullet fragments retained in the spinal canal. A collaborative study by the National Spinal Cord Injury Model System. *Spine*. 1991;16:934–939.
37. Lindsey RW, Gugala Z. Spinal cord injuries as a result of ballistic trauma. State of the art reviews. *Spine*. 1999;24:529–546.