




ELSEVIER

Available online at www.sciencedirect.com

SciVerse ScienceDirect

journal homepage: www.elsevier.com/locate/ijnt

Review Article

Spontaneous depressed skull fracture during vaginal delivery: A report of two cases and literature review

Muhammad Zafrullah Arifin^a, Arwinder Singh Gill^{a,*}, Anita Deborah Anwar^b, Tono Djuwantono^b, Ahmad Faried^a

^aDepartment of Neurosurgery, Faculty of Medicine, Universitas Padjadjaran – Dr. Hasan Sadikin Hospital, Jl. Pasteur 38, Bandung 40161, Indonesia

^bDepartment of Obstetric and Gynecology, Faculty of Medicine, Universitas Padjadjaran – Dr. Hasan Sadikin Hospital, Bandung, Indonesia

ARTICLE INFO

Article history:

Received 15 October 2012

Accepted 1 December 2012

Available online 7 December 2012

Keywords:

Spontaneous depressed skull fracture

Birth head trauma

Seizure

ABSTRACT

Objective: Spontaneous (without instrumentation) depressed skull fracture cases are rare in newborns and, in most cases, are caused by trauma during delivery. The diagnosis of a skull fracture can sometimes be difficult and the correct management of these fractures in newborns is still uncertain.

Case presentation: Two cases of spontaneous (without instrumentation) depressed skull fracture in newborns are reported and were related to birth trauma. Each case was managed differently according to its clinical presentation.

Conclusion: Spontaneous depressed skull fracture of the newborn presents as a challenge in neurosurgical management. Although widely accepted that conservative management is a treatment of choice, but few cases with intractable seizures are also indication for surgical intervention. Our case series is a good educational lesson that can also be used by pediatrician and obstetrician for better management and handling of birth head trauma.

Copyright © 2012, Neurotrauma Society of India. All rights reserved.

1. Introduction

Delivery process will eventually apply pressure to the neonate's head *in utero* or during birth event that may lead in a depression of parietal or frontal bone of the skull. Pressure of the fetal skull by the 5th lumbar vertebrae, sacral promontory, pubic symphysis, ischia spines or by an asymmetrical and contracted pelvis have been implicated in these depressions that occurred in the absence of forceps or traumatic delivery.^{1,2}

The etiology of these depressions is not fully revealed, while most cases in Western countries are caused by forceps application or as a result of pressure by the obstetricians hands; in African population most cases are results from extreme molding of the fetal skull in its passage through birth canal.³ Even though, depressed skull fractures are rare in newborns, in most cases, they are caused by trauma during delivery.⁴

Therefore, we wish to report two cases of newborn depressed skull fracture during normal spontaneous vaginal

* Corresponding author.

E-mail address: arwinsingh@hotmail.com (A.S. Gill).

0973-0508/\$ – see front matter Copyright © 2012, Neurotrauma Society of India. All rights reserved.

<http://dx.doi.org/10.1016/j.ijnt.2012.12.001>

delivery, in which we performed craniotomy in one patient while managing the other one conservatively.

2. Case reports

2.1. Case 1

A 3600 g male baby was born from a 30-year-old woman (Gravida 2, Abortus 0) after a normal full term gestation. The spontaneous delivery was helped by an obstetrician without any instrumentation. The delivery was difficult and lasted for more than 10 h, especially the aftercoming head. APGAR scores were 5 and 7 in first and fifth minute, respectively. Head circumference at birth was 38 cm (33–38 cm) and body length 49 cm. The small anterior fontanel was soft and tender with size 2×1 cm.

The baby was brought to our emergency department approximately 24 h after delivery following the development of whole body seizure, with each seizure lasting for 2–3 min. There was no history of decreased consciousness, vomiting or

fever. Head CT scan revealed a depressed skull fracture at the occipital region (Fig. 1A and B) without any other abnormalities noted. Patient was managed conservatively as no seizures nor other neurological symptoms developed during hospitalization. The baby was discharged after one week in good condition.

2.2. Case 2

A 3500 g male baby was born from a 21-year-old woman (Gravida 1, Abortus 0) after a normal full term gestation. The spontaneous delivery was helped by a traditional midwife without any use of instruments nor any external extraction force. The delivery was difficult and lasted for 8 h but APGAR scores were not noted. Head circumference at birth was 36 cm (33–38 cm) and body length 48 cm. The small anterior fontanel was open and soft with size 3×2 cm.

After presenting with seizure on his left extremity, the baby was brought to our emergency department approximately 20 h after delivery, with each seizure lasting for 5 min. Head CT scan revealed a depressed skull fracture in the right

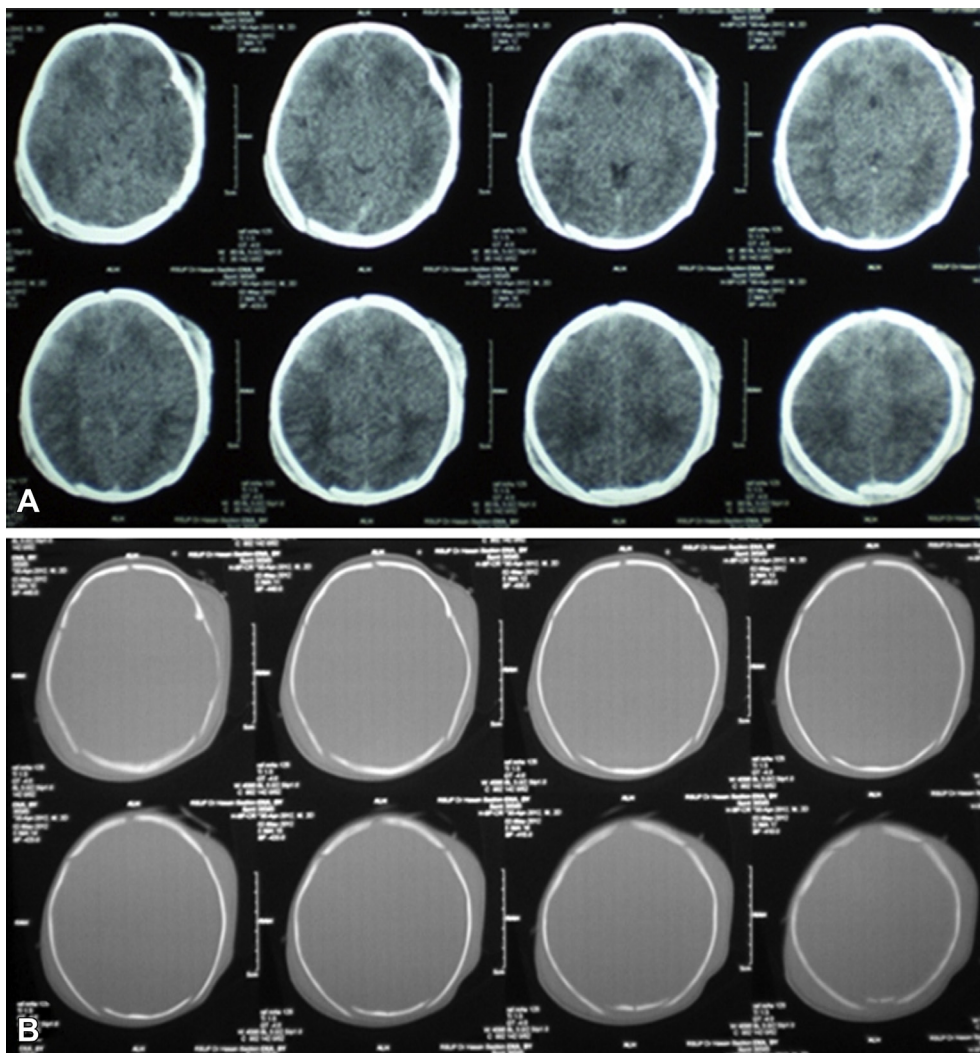


Fig. 1 – A. Brain CT scan revealing a large depressed fracture over the occipital region. B. Brain CT scan with bone window to confirmed a large depressed fracture over the occipital region.

parietal region (Fig. 2A and B). Although not obviously seen, this right parietal depressed fracture was easily palpated. There was no edema or discoloration surrounding the fracture and the baby was otherwise completely normal. When examined by pediatrician the baby had myoclonic seizure and even after administering adequate anticonvulsants the seizures did not diminished. After several failed attempts of non-surgical techniques to elevate the fracture, an emergency craniotomy surgery was scheduled.

During surgery, we found depressed fracture with size of 2×2 cm interlocking at the parietal region (Fig. 3A). A burr hole adjacent to the fracture was performed and using an elevator the fracture was tried to lever back into place but finally a rongeur was used to nibble a little bone-off the edge of the depression, allowing entry into epidural space. We noted 3 cm laceration of duramater and hemostasis was then obtained with bipolar forceps. The cerebral injury was covered with hemostatic absorbable gauze and the duramater was closed with pericranial graft (Fig. 2B). The bone fragments were reassembled to be replaced in the bony defect. The postoperative course was uneventful and the baby was discharged in good condition on the sixth postoperative day. During one month follow up, the patient had neither recurrence of seizures nor any other neurological symptoms.

3. Discussion

The incidence of major birth trauma such as fractures, paralysis and lacerations are accounted between 1 and 11.7 per every 1000 to 2000 live births. Perinatal death secondary to

birth trauma alone is a rare event that occurs 1 in about 1000–2000 births. Many factors related to the fetus, the mother, and the delivery process have been correlated with an increased incidence of traumatic birth. Such factors include macrosomia, growth retardation, preterm labor, breech presentation, and also multiparity.^{7,8}

The stage of the brain, intracranial vasculature and calvarial-development directly relates to the type of injuries seen in different pediatric age groups. The brain development, bone calcification, and body habitus of neonate is different from that of a child. The disproportionately large size of the head and the weaker neck musculature of neonates and infant place them at increased risk for rotational and acceleration/deceleration injuries.⁸

Three types of skull fractures can occur in newborns: linear, depressed or "ping-pong" fractures and occipital osteodiasis.⁷ The developing skull is unicortical and consist of bones that are soft, thus depressed skull fractures usually comprises of indentations in the bone (ping pong fractures) and not actual fractures into the cortex of the bone.⁸ These fractures usually occur in the parietal bones, occasionally in the frontal bones and, rarely, in the occipital region.⁹ As in our case series, one presented with parietal bone fracture whereas the other with occipital bone fracture that were managed differently.

Several studies have examined the incidence of pediatric skull fractures. Rubin et al, found only one skull fracture out of 108 birth injuries in 15,435 deliveries.⁴ Skull fractures during birth that have been diagnosed by plain X-ray imaging are reported to be very infrequent between 0.01 and 5%. In large perinatal centers, these cases are more easily detected as the availability of better diagnostic tools are present such as CT

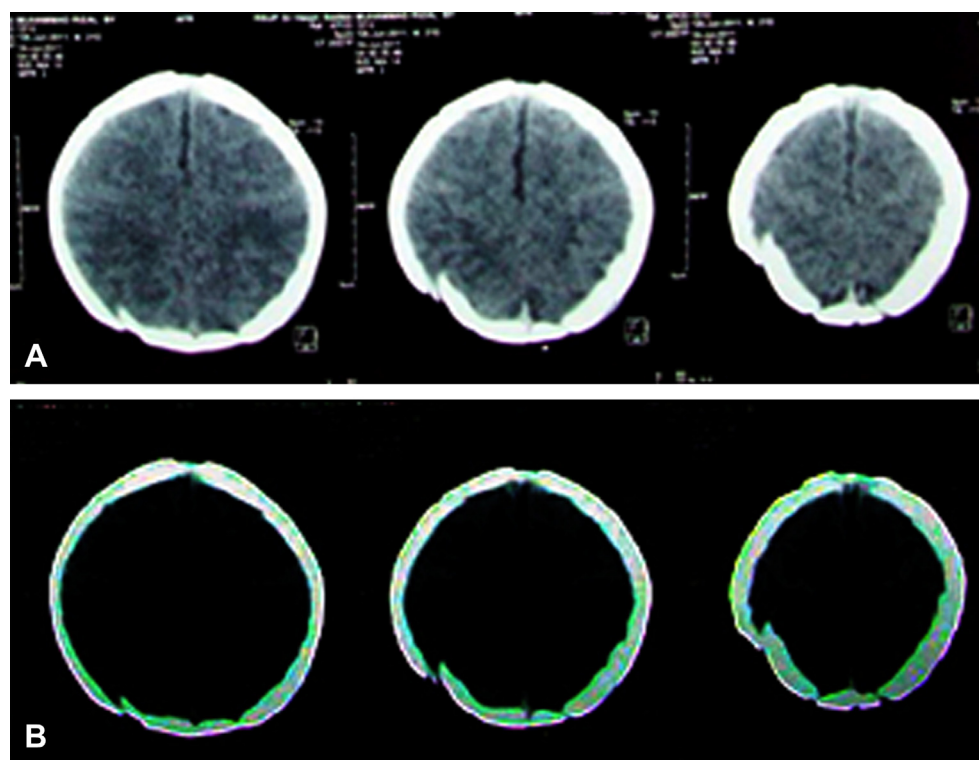


Fig. 2 – A. Brain CT scan revealing a large depressed fracture over the parietal region. B. Brain CT scan with bone window to confirmed a large depressed fracture over the parietal region.

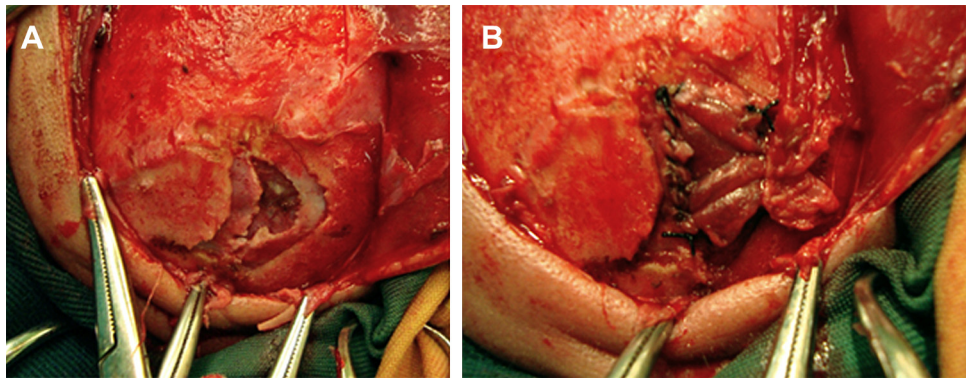


Fig. 3 – A. Intra-operative finding; the depressed fracture size 2 × 2 cm, interlocking at the parietal region. B. A pericranium graft was used to patch the lacerated duramater.

scan. Bhat et al, showed that bone injuries occur in 1/1000 live births, and that only 11.4% of the bone injuries are skull fractures.¹¹ In another series by Hughes et al, it was observed that the incidence of obstetric depressed skull fracture was 2.9% whereas Dupois et al, estimated the incidence to be about 3.7% of every 100,000 deliveries (75/1.994.250).^{12,16} In 1985, Camus et al, reviewed 20,409 births and reported an incidence of obstetric skull fracture of 19 of 100,000 births.¹³ This variety in incidence shows that true number of obstetric skull fractures during birth may be far higher than reported in the past literature.¹⁰

Most common skull fracture in the newborn results from the extrinsic trauma to mother's abdomen¹⁴ or traumatic delivery, including forceps application or due force of extraction at the time of birth.^{5,15} Dupuis O et al, note that spontaneous (without instrumentation) depressed skull fracture can occur during vaginal delivery or elective C-section as a result from pressure on the soft fetal skull from the maternal 5th lumbar vertebrae, sacral promontory, pubic symphysis, ischia spines, asymmetric or contracted pelvis and also uterine myoma. Instrumentation related fractures are more common which may result in intracranial lesions.¹⁶

There are numerous strategies in treating closed depressed fracture in neonates. Steinbok et al, reported that there was no difference in outcome between children with depressed fractures that were treated surgically and non-surgical in the aspects of seizure occurrence, neurological dysfunction, or overall cosmetic picture.⁶ Thus suggested that the non-surgical modality becoming the standard treatment regimen for depressed fractures among pediatric patients including digital pressure, the use of a breast pump and obstetrical vacuum extractor.⁵

One concern does exist, however. As some authors have hypothesized that a fracture depression deeper than 5 mm or greater than the local skull thickness might impinge on the infant's cerebral cortex and elicit some of localized compression therein, resulting in cerebral edema and decreased cerebral blood flow.¹⁷ Since the infant's brain is susceptible to injury, brain injury sustained during birth has critical significance. As early as 1975, Tervilä et al, suggested the correlation between birth head trauma and epilepsy,¹⁸ while Gurney et al, in 1996 observed that the presence of birth head trauma may

be a risk factor for a brain tumor development.¹⁹ Recent study proposed that early detection and intervention of birth head trauma may decrease the incidence of lifelong disabilities such as cerebral palsy and learning disorder.¹⁰

Loeser and coworkers recommend surgical intervention only for cases who have bone fragments in the cerebrum, neurological deficits with or without increased intracranial pressure, or an associated dural tear with leakage of cerebrospinal fluid beneath the galea. They also consider surgical elevation in neonates who failed conservative management, poor cosmetic results, or have unreliable long-term follow up. One should proceed immediately to an open craniotomy to elevate the depressed fracture if non-surgical means fail.²⁰ However, most neurosurgeons accept the arbitrary determination that a large depression in a symptomatic child will likely have dural lacerations. This seems reasonable, especially on the fact that an operative procedure for elevating a depressed fracture presents minimal risks and that it affords the added protection of having the depressed fracture elevated and the dura inspected for tears which, if present, may be repaired before a meningocele spuria develops and prevents the occurrence of growing skull fracture.²¹ As in the second case, the child had seizures that were not ceasing with antiepileptic drugs and non-surgical techniques. We decided to perform surgery as we predicted a high chance of dural tear which was proven intra-operatively.

Nevertheless, little information exists to assist clinicians in accurately predicting which specific depressed fracture would likely recover spontaneously. It would appear reasonable to treat larger and deeper depressions more aggressively as they have higher risks of dural tear especially after failed non-surgical techniques and persistent neurological symptoms. We suggest that the depressed skull fracture observed in our case series may have resulted from excessive pressure of uterine contractions, with possible impaction of the fetal skull against the symphysis pubis. This is supported by a previous case report by Neiger and Sacks in 1988²² and by Heise RH et al, in 1996.²³

We are confident that our case series is noteworthy since it not only shows a rare case that presents in even a normal spontaneous vaginal delivery resulting in sufficient injury to the infant's head but also different management schemes according to specific patient presentation.

4. Conclusion

We report two cases of infants with spontaneous (without instrumentation) depressed skull fracture caused by excessive pressure of uterine contractions, with possible impaction of the fetal skull against the birth canal. Both of these cases were managed distinctively according to its clinical presentation and course. Although conservative management is more preferable but surgery is indicated in patients with persistent neurological symptoms. Our case series is a good educational lesson that can also be used by pediatrician and obstetrician for better management and handling of birth head trauma.

Disclosure

Each author took part in the design of the study, contributed to data collection, participated in writing the manuscript and all agreed to accept equal responsibility for accuracy of contents of this paper.

Conflicts of interest

All authors have none to declare.

REFERENCES

1. Guha-Ray DK. Intrauterine spontaneous depression of fetal skull: a case report and review of literature. *J Reprod Med.* 1976;16:321–324.
2. Reid DE. *A Text Book of Obstetrics.* Philadelphia: WB Saunders Co; 1960:601.
3. Axton JHM, Levy LF. Congenital molding depressions of the skull. *Br Med J.* 1965;1:1644–1647.
4. Rubin A. Birth injuries: incidence, mechanisms, and end-results. *Obstet Gynecol.* 1964;23:218–221.
5. Loeser JD, Kilburn HL, Jolley T. Management of depressed skull fractures in the newborn. *F Reprod Med.* 1996;41:754–760.
6. Steinbok P, Flodmark O, Martens D, Germann ET. Management of simple depressed skull fractures in children. *J Neurosurg.* 1987;66:506–510.
7. Doumouchtosis SK, Arulkamran S. Head injuries after instrumental vaginal deliveries. *Curr Opin Obstet Gynecol.* 2006;18:129–134.
8. Tibbs RE, Lee DC, Parent AD. Depressed skull fracture. In: Batjer HH, Loftus CM, eds. *Textbook of Neurological Surgery: Principles and Practice.* Philadelphia: Lippincott Williams and Wilkins; 2003:1082–1095.
9. Beyers N, Moosa A, Bryce RL, Kent A. Depressed skull fracture in the newborn. *S Afr Med J.* 1978;54:830–832.
10. Matson DD. *Neurosurgery of Infancy and Childhood.* ed. 2. Springfield, IL: Charles C Thomas; 1969:934.
11. Bhat BV, Kumar A, Oumachigui A. Bone injuries during delivery. *Indian J Pediatr.* 1994;61:401–405.
12. Hughes CA, Harley EH, Milmoeg G, Bala R, Martorella A. A birth trauma in the head and neck. *Arch Otolaryngol Head Neck Surg.* 1999;125:193–199.
13. Camus M, Lefebvre G, Veron P, Darbois Y. [Traumatismes obstetricaux du nouveau-ne: enquete retrospective a propos de 20.409 naissances.] (France). *J Gynecol Obstet Biol Reprod.* 1985;14:1033–1044.
14. Alexander Jr E, Davis Jr CH. Intrauterine fracture of the infant's skull. *J Neurosurg.* 1969;30:446–454.
15. Ben-Ari Y, Merlob P, Hirsch M, Reisner SH. Congenital depression of the neonatal skull. *Eur J Obstet Gynecol Reprod Biol.* 1986;22:249–255.
16. Dupuis O, Silveira R, Dupont C, et al. Comparison of "instrument-associated" and "spontaneous" obstetric depressed skull fractures in a cohort of 68 neonates. *Am J Obstet Gynecol.* 2005;192:165–170.
17. Hung KL, Liao HT, Huang JS. Rational management of simple depressed fractures in infants. *J Neurosurg (Pediatrics 1).* 2005;103:69–72.
18. Tervilä L, Huhmar EO, Krokfors E. Cerebral birth injury as a cause of epilepsy. *Ann Chir Gynaecol Fenn.* 1975;64:118–122.
19. Gurney JG, Preston-Martin S, McDaniel AM, Mueller BA, Holly EA. Head injury is a risk factor for brain tumors in children: results from a multi-center case-control study. *Epidemiology.* 1996;7:485–489.
20. Loeser JD, Kilburn L, Jolley T. Management of depressed skull fracture in the newborn. *J Neurosurg.* 1976;44:62–64.
21. Ragheb J. Accidental head injuries. In: Albright AL, Pollack IF, Adelson PD, eds. *Principles and Practice of Pediatric Neurosurgery.* ed. 2. New York: Thieme; 2008:803–807.
22. Neiger R, Sacks LM. An unusual neonatal case presentation: cephalohematoma with underlying skull fracture in a neonate delivered by cesarean section (case report). *J Perinatol.* 1988;8:160–162.
23. Heise RH, Srivatsa PJ, Karsell PR. Spontaneous intrauterine linear skull fracture: a rare complication of spontaneous vaginal delivery (Review). *Obstet Gynecol.* 1996;87:851–854.