


Available online at www.sciencedirect.com

ScienceDirect

journal homepage: www.elsevier.com/locate/ijnt

Original Article

Dorsal horn suction – A DREZ lesioning technique based on intrinsic cord tissue elasticity

Milan Spaić^{a,*}, Dušan Mikić^b, Nada Marković^c, Ivica Milosavljević^d^a Department of Neurosurgery, Clinical Centre Zemun, Vukova 9, Belgrade-Zemun 11080, Serbia^b Institute for Fluid Mechanics, Electronic Faculty, King Alexander Str., 73, Belgrade 11000, Serbia^c Institute for Psychology and Mental Health, Military Medical Academy, Crnotravska 17, Belgrade 11000, Serbia^d Institute for Pathology, Military Medical Academy, Crnotravska 17, Belgrade 11000, Serbia

ARTICLE INFO

Article history:

Received 11 November 2013

Accepted 13 November 2013

Available online 2 December 2013

Keywords:

DREZ surgery

Dorsal horn suction

Neuropathic pain

Spinal injury

ABSTRACT

Aim and objective: The accuracy of the lesioning plays a crucial role in the results of Dorsal Root Entry Zone (DREZ) surgery. The DREZ lesioning utilizes different techniques: radio-frequency, laser, ultrasound, electrocoagulation, with the size and the shape of the lesions determined by the technical parameters of the respective technique. The aim of this study is to assess the effectiveness of the dorsal horn suctioning as a DREZ lesioning technique applied for the treatment of neuropathic pain of spinal cord and/or cauda equina injury origin. The geometry of the lesion was determined by the natural properties of the cord tissue itself.

Methods: The series of 20 patients, 18 men and 2 women, aged 24–66 years, with a mean age of 40 year were operated on using Sindou's Microsurgical DREZotomy technique, modified in such a way that the selective dorsal horn suctioning was performed as a lesioning method instead of bipolar electrocoagulation, because they suffered from chronic neuropathic pain as the sequel of spinal injuries. Success in pain relief has been defined as 50% or greater reduction in pain after surgery.

Results: Satisfactory long-term pain relief was achieved in 16 (80%) of patients.

Complete long-term pain relief was achieved in 12 (60%) of the patients.

Conclusion: Our results confirmed the dorsal horn suction as a feasible DREZ lesioning method.

Copyright © 2013, Neurotrauma Society of India. All rights reserved.

1. Introduction

Paraplegia due to spinal cord trauma is one of the most devastating injuries in human pathology.¹ Posttraumatic neuropathic chronic pain complicates 10–30% of injuries with devastating impact on patient life.² The treatment of the

chronic neuropathic pain of spinal cord and cauda equina injury origin remains a significant management problem. Almost two centuries ago Luigi Rolando published his anatomic observation on jelly-like structure of the cord dorsal horn tissue.³ We report on the novel and simple DREZ surgical lesioning technique based on the difference in tissue elasticity between white and gray cord substance.

* Corresponding author. Tel.: +381 11 3772 652, +381 63 373 844 (mobile).

E-mail address: spaicmil@yahoo.com (M. Spaić).

0973-0508/\$ – see front matter Copyright © 2013, Neurotrauma Society of India. All rights reserved.

<http://dx.doi.org/10.1016/j.ijnt.2013.11.005>

Successful pain relief aims to help an individual to re-establish functional life in the posttraumatic period and to prevent psychological deterioration caused by suffering of chronic pain. The mechanism of this pain phenomenon has been shown to be related to neurochemical changes that lead to the state of hyperactivity of second order dorsal horn neurons producing spontaneous discharges of central nociceptive neurons resulting in chronic pain.⁴ Thus, the dorsal horn, as anatomical structure involved in pain generating, has been recognized as a target for ablative surgery.

The Dorsal Root Entry Zone (DREZ) operation was designed to destroy cord dorsal horn by using different technical modalities such as Radiofrequency (RF), Laser, Ultrasound, Microsurgical DREZotomy technique (MDT).^{5–8}

The Microsurgical DREZotomy procedure introduced by Sindou was based on the functional anatomy of the DREZ taking advantage of the segregation of pain from lemniscal fibers in the lateral bundle of the central portion of the dorsal rootlets that enables a selective destruction of the nociceptive fibers, while most of the large lemniscal fibers that are grouped medially, should be spared⁹ (Fig. 1).

The MDT technique consists of an incision of the dorso-lateral cord sulcus (DLS), 2 mm in depth and at 45° of angle medially and ventrally, that interrupts nociceptive fibers and subsequent bipolar electrocoagulation using sharp bipolar microforceps that aims at a destruction of the dorsalmost layers of the dorsal horn gray substance.⁸

While the angle and depth of the incision could be visually controlled, the elektrocoagulation of the gray substance inside opened DLS and the extent of lesioning could not be visually controlled. The size and shape of the lesioning rely on the penetration depth of the bipolar forceps and electrical current power.

Microsurgical incision of the dorsolateral cord sulcus allows for the direct access to the dorsal horn gray substance for selective ablation. We postulated that the gray substance of the dorsal horn exposed by the incision of the DLS could be selectively and completely destroyed by employing simple suction of the dorsal horn gray substance under visual control. Thus the MDT technique was modified in such a way that the

selective dorsal horn suctioning (MDT-DHS) was performed as a lesioning method instead of the standard bipolar electrocoagulation. The technique takes advantage of the difference in viscosity of the cord white versus gray matter to perform DREZ lesions by using the suction of the dorsal horn gray matter as a lesioning method. With respect to the neuropathic paraplegic pain treatment in humans we believed that the more extensive lesion of the dorsal horn, as a pain generating anatomical structure, was likely a long-lasting pain relief.

2. Methods

2.1. Technique development

Our study on cadaveric cord tissue revealed that the white cord substance had four-time higher dynamical viscosity in comparison with the gray substance (150 Pa/second versus 37.5). The method of testing was published elsewhere.¹⁰ The dorsal horn suction tested on the lumbar enlargement of cadaver cord showed that the difference in tissue elasticity between white and gray cord substances facilitated demarcation of a clean dissection plan that allowed for selective suctioning of the dorsal horn gray substance¹¹ (Fig. 2).

2.2. Patients

In the period April 1997–January 2013, 20 patients, 18 males and 2 females, with a mean age of 40 years (range, 24–66) were operated on using DREZ lesioning because they suffered from chronic neuropathic pain as the sequela of spinal T10–L3 level gunshot war injuries in 13, road traffic accident injuries in 3, stab wound in 1 patient and falls from the height in 3 patients (Table 1). Actual neurological condition and functional classification of spinal injury were measured according to the American Spinal Injury Association Impairment Scale (ASIA)¹² (Table 2). There were 9 patients with ASIA grade A, 3 patients with grade B, and 8 with grade C.

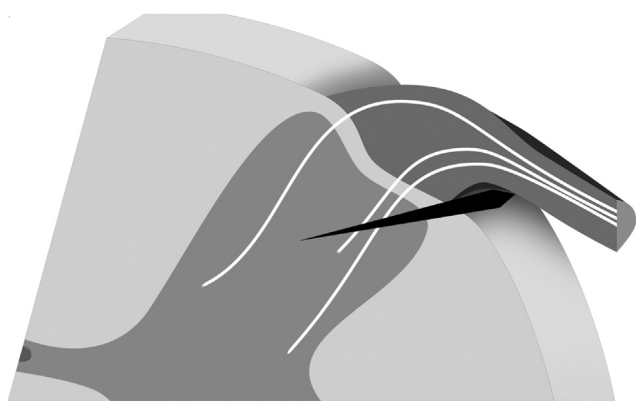


Fig. 1 – Schematic drawing showing arborization of the primary afferents in the DREZ and dorsal horn. Note: laterally segregated pain fibers. Arrowhead: Sindou's cord incision: severance of the pain fibers.

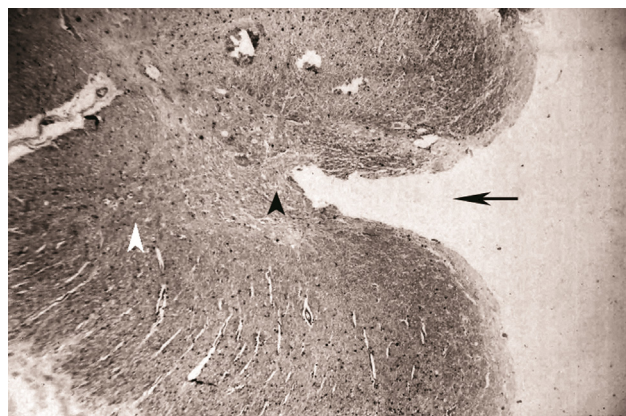


Fig. 2 – Histological specimen of the cadaver cord that underwent dorsal horn suction as a lesioning technique demonstrating the size and the shape of the dorsal horn lesion (black arrow) that extends to the central gray cord matter (black arrowhead), ventral horn (white arrowhead). Staining: hematoxylin eosin.

Table 1 – Summary of the patients.

Sex, age	Level of vertebral injury, etiology	Neurological condition, (ASIA)	VAS	Pain relief			Side-effects/complications
				Initial	Pain recurrence	Long-term	
33/m	L3, GSW	C	8	100%	Partial pain recurrence after 37 m	50%	Transient CSF leak, anesthesia in pain territory
40/m	L2, GSW	A	9	100%	Partial pain recurrence after 47 m	50%	
43/m	L2, GSW	A	8	100%	Full intensity recurrence after 62 m	Failed	
41/m	L1, GSW	B	9	100%		100%	CSF leak Anesthesia in pain territory
38/m	L2, RTA	B	10	100%		100%	
66/f	T11, RTA	A	9	100%		100%	CSF leak Wound dehiscence
56/m	L2, GSW	A	9	100%		100%	
36/m	L1, GSW	C	9	100%		100%	
30/m	T12, GSW	A	9	100%		100%	100%
29/m	L1, stab wound	A	8	100%		100%	
49/m	T12, GSW	C	10	100%	Full intensity recurrence after 8 m	Failed	
38/m	L2, GSW	A	9	100%		100%	100%
24/m	L1, GSW	C	8	100%		100%	
27/m	L2, GSW	C	8	100%		100%	
33/m	L1, GSW	B	8	100%		100%	Failed
27/m	T12, GSW	A	10	100%	Full intensity recurrence after 21 m	Failed	
44/m	L1, fall	C	10	100%	Partial pain recurrence after 20 m	60%	Motor strength improvement
47/m	T10, fall	A	8	90%	Partial recurrence after 10 m	Failed	
40/m	T12, RTA	C	8	100%	Partial pain recurrence after 24 m	60%	CSF leak
60/f	T12, fall	C	8	100%		100%	Anesthesia in pain territory, motor strength loss

ASIA, American Spinal Injury Association Impairment Scale, VAS, Visual Analogue Scale, GSW, gunshot wounds, RTA, road traffic accident, CSF cerebrospinal fluid, m, male, f, female, f/u, follow up, m, months of the follow up.

All the patients were interviewed by using McGill-Melzack pain Questionnaire with a list of 47 pain descriptors in order to assess sensory structure, topography along with the rhythm of the pain expressed.¹³ Intensity of the pain was measured by using Visual Analogue Scale (VAS). Psychological investigation was performed using Minnesota Multiphasic Personality Inventory (MMPI). MMPI interview revealed higher level of

anxiety, hypochondriasis and depression scale for all the patients interviewed. All the patients suffered from the pain of confined segmental distribution that had a rhythm of intermittent pain attacks. NMR imaging was routinely performed preoperatively in order to identify gliotic or syringomyelic cysts. The patients were considered for the DREZ surgery when the pain: lasted for at least six months without relapse, severe enough to disrupt normal daily activities and sleeping pattern requiring routine analgesic and/or narcotic medication. Pain relief as a result of DREZ surgery was assessed by the patients themselves by using Visual Analogue Scale as the percent of residual pain compared to preoperative pain level. Success in pain treatment has been defined as the patient who experienced 50% or greater reduction in pain after the surgery such that pain no longer interferes with his/her activities of daily living and sleeping pattern and no longer requires routine analgesic pain medication. Pain relief was assessed on the first postoperative day and was considered as immediate pain relief. Thereafter, pain assessment was done every day until discharge from hospital while, in the later period, all the patients were followed up clinically by outpatient review. In this prospective study the pain relief that lasted for more than six months after the surgery was regarded as long-term pain relief.

Table 2 – The ASIA Impairment Scale.

ASIA	Spinal Neurological Impairment
A	No sensory or motor function is preserved below the neurological level
B	Sensory but not motor function is preserved below the neurological level
C	Motor function is preserved below the neurological level and majority of key Muscles have a muscle grade less than 3
D	Motor function is preserved below the neurological level and majority of key Muscles have a muscle grade equal or greater to 3
E	Sensory and motor function is normal

ASIA, American Spinal Injury Association.

2.3. Surgical procedure

The dorsal horn suction was performed as the DREZ lesioning at the lumbar enlargement level by using a microsucker (Fig. 3) at the cord levels corresponding to the territory of the pain and was described in our previous report.¹¹

In approaching to DLS for incision, we insisted on sparing blood vessels adhered to the DLS that sometimes requires its mobilization and displacement from the DLS. However, when it was not possible, the attempt to drive incision just aside the fixed artery was sufficient to have access to the dorsal horn. Following incision, the DLS was gently opened by the micro-forceps tips and the suctioning of the dorsal horn gray matter was performed under the visual control of 20 times microscopic magnification.¹¹ The suction tip followed the dorsal horn appearing as the band of the gray substance, leaving empty space between white columns (Figs. 4 and 5).

The application of the dorsal horn suction technique in humans were approved by the Institutional Ethics Committee. The patients were informed in detail regarding this new lesioning method. The risk and possible complications of the technique were discussed. The writing consent was obtained from each of the operated.

3. Results

Initial pain relief as a result of the DREZ surgery was complete in 19 patients while mild residual pain, was noted in one of the patients.

Long-term success in the treatment of pain, defined as a pain relief for more than 50% of the preoperative pain level, was achieved in 16 (80%) of the patients.

Complete long-term pain relief was achieved in 12 (60%) of the patients.

Treatment-related morbidity was as follows: there were no surgical complications regarding infection. Transient cerebrospinal fluid leakage occurred in 4, and wound dehiscence in 1 of the patients. Light touch sensation was partially preserved for the dermatomes which corresponded to the operated cord segments and which presented preoperatively with significant sensory function.

Sensibility was completely lost in the dermatomes which corresponded to the operated cord segments in 3 of the patients. One of the patients experienced diminished motor strength in myotomes corresponded to operated segments. One of the patients improved motor strength after the operation, that might be addressed to the radiculolysis and dividing arachnoidal scarring routinely performed in accessing

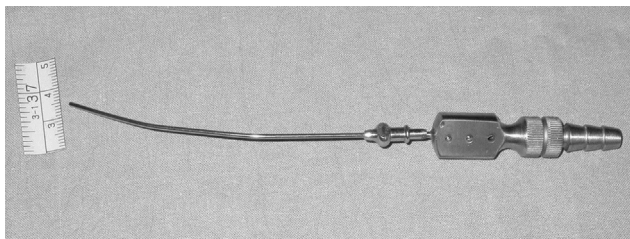


Fig. 3 – The microsucker used for dorsal horn suctioning.

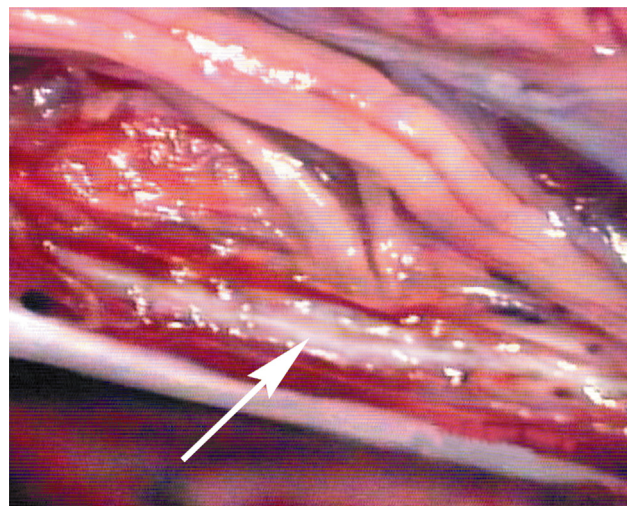


Fig. 4 – Dorsal horn suction (microphotograph, 16 times magnification): longitudinal incision of DLS (arrow), note: the appearance of the dorsal horn gray substance in the opened dorsolateral cord sulcus.

DLS in the operated cord segments. The postoperative NMR investigation was not routinely performed. However, in five of our patients that underwent NMR investigation the proper geometry of the DREZ lesion was revealed (Fig. 6).

4. Discussion

DREZ lesion can be performed by using Nashold's Radio-frequency (RF) lesioning procedure or a Laser beam, while the size and the shape of the lesions were determined by technical parameters of the respective lesioning technique.^{5,6} The size of RF lesioning is related to the penetration depth of the electrode and the time and temperature of the exposure at the

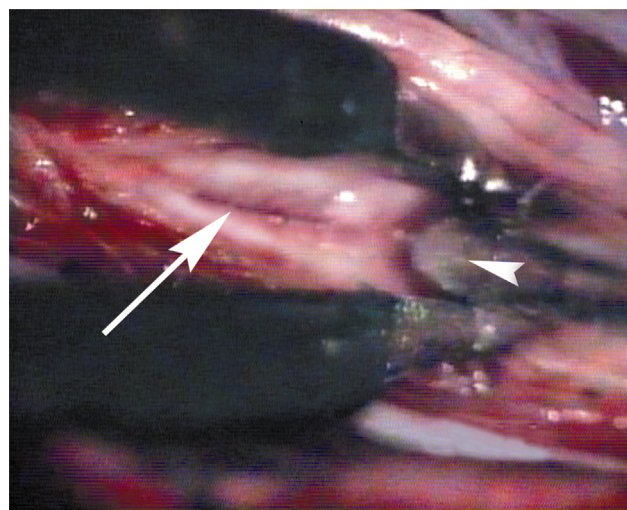


Fig. 5 – Dorsal horn suction (microphotograph, 16 times magnification): suction of the dorsal horn gray matter performed using microsucker (arrowhead) in the dorsolateral cord sulcus (arrow) opened with microforceps.

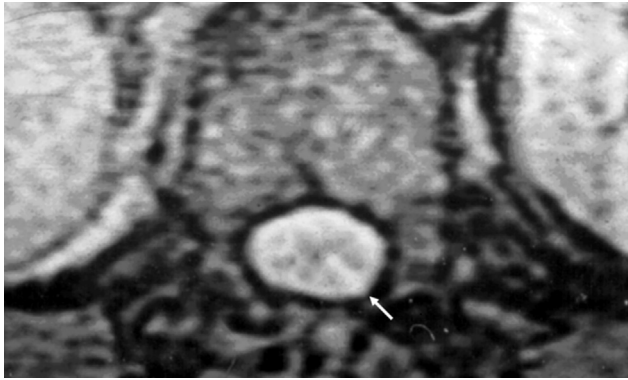


Fig. 6 – NMR scan (0.5 Tesla) demonstrating cerebrospinal fluid filling the DREZ lesion (arrow).

moment of lesion making.⁵ The extent of the DREZ lesion performed using the RF technique, as it was established by the post mortem analysis of the human cord after the DREZ operation, included the dorsal horn completely, down to its base.¹⁴ However, laser DREZ lesion showed to be inconsistent with variations in the lesion size related to misdirected lesions due to the spinal cord movement or errors in alignment between the target and the actual laser beam and the loss of energy due to absorption in CSF.¹⁵

Ultrasonic disintegration of the dorsal horn was made after longitudinal opening of the DLS as in the MDT procedure. Ultrasound destroyed tissues strictly along the cutting edge of the ultrasonic probe regardless of their density characteristics. The depth of lesioning of 1.5–2 mm and the volume of the lesion was possible to control visually.⁷

The Microsurgical DREZotomy was established based on the functional anatomy of the DREZ zone and included the incision of the DLS and subsequent bipolar coagulation of the dorsalmost layers of the dorsal horn. The incision of the dorsolateral cord sulcus proposed by Sindou provides selectivity of the MDT procedure so that at least part of the lemniscal sensory function may be spared¹⁶ (Fig. 1). The incision of the DLS, furthermore, allows the direct access to the dorsal horn gray substance for the selective ablation. We believed that the better result in treating pain could be achieved with the lesioning that included the dorsal horn completely, down to its base.

For the achievement of the more extensive dorsal horn lesion using electrocoagulation the higher level of the electrical current power and deeper penetration of the bipolar forceps inside the opened DLS and dorsal horn are needed, what, however, impose the risk of spreading of the lesion to the dorsal column medially or to the pyramidal tract laterally. Hence, in order to create visually controlled dorsal horn ablation down to its basis - the suctioning technique was developed. Our results proved that the goal of the selective lesioning of the dorsal horn could be achieved by utilizing suction of the dorsal horn gray substance under the visual control. Differences in mechanical properties of the spinal cord gray and white matter allowed for selective DREZ lesion. In other words, the method utilizes the physical principle in the DREZ lesioning. The proper longitudinal incision of the

DLS, as a first step of the procedure that exposed the dorsal horn gray substance, was found to be the crucial one for the successful application of the dorsal horn suctioning.

The difference in dynamical viscosity that was 4 times lower for gray than that in the white matter, explains why suction of the dorsal horn gray substance could be performed safely and gradually to the base of the dorsal horn under visual control. The geometry of the lesion was determined by the natural properties of the cord tissue itself.¹¹

In our series 16 out of 20 (80%) of the operated patients, using MDT-dorsal horn suction technique, experienced good pain relief while 12 out of 20 (60%) experienced complete pain relief during a long-term period. Sindou et al, using MDT with standard bipolar coagulation lesioning, in the group of 20 patients suffering from the same pain pattern as our patients, observed a good pain relief in 15 (75%) of them.¹⁶ However, the postoperative analgesic effect was considered to be good when patient's estimation of pain relief exceeded 75% as compared to the criterion of 50% in our series. Friedman and Nashold in their series of 56 patients using radiofrequency DREZ lesioning noted that 74% of the patients with localized pain had a good pain relief, while Rath et al in the group of 16 patients had a good pain reduction 11 (69%).^{17,18}

In our earlier report of 22 patients treated for the same pain syndrome by using MDT with standard bipolar coagulation lesioning, a complete pain relief was experienced by 12 (54%) patients.¹¹ The differences in these two groups (54% versus 60%) of our patients regarding the complete pain relief did not reach the level of statistical significance (Fischer exact test).

Pain of confined segmental distribution, what was the pain pattern in our patients, was already reported to be the most responsive to the DREZ surgical treatment.¹⁹ The better result achieved by using dorsal horn suction as a DREZ lesioning, with respect to the complete pain relief seemed to be in a logical relation with the mechanism of pain shown to be generated by deafferented dorsal horn neurons. In other words, the smaller residual volume of the dorsal horn gray substance was, the less likelihood of the pain mechanism re-establishment was. Falci et al, who developed the technique for the intramedullary electrical neurophysiological guidance in order to perform the complete dorsal horn lesioning, pointed to the completeness of the DREZ lesion as an important factor in achieving pain relief.²⁰

The dorsal horn suction procedures were performed on the cord lumbar enlargement with a very voluminous dorsal horn gray substance located just under the cord surface. It is doubtful whether the dorsal horn suction technique could be performed on the thoracic cord segments in the same manner taking into account the deep position of the narrow dorsal horn from the cord surface. Further experience with the dorsal horn suction as a DREZ lesioning technique is needed to clarify such a dilemma.

5. Conclusions

Our results confirmed that the dorsal horn suction technique was a feasible DREZ lesioning method. The utility and selectivity of this technique are ensured by the natural mechanical properties of the cord tissue itself.

Conflicts of interest

All authors have none to declare.

REFERENCES

1. Nashold BS. Paraplegia and pain. In: Nashold BS, Ovelmen-Levitt J, eds. *Deafferentation Pain Syndromes: Patophysiology and Treatment. Advances in Pain Research and Therapy*. vol. 19. New York: Raven Press. Ltd.; 1991:301–330.
2. Boterell EH, Callaghan JC, Jousse AT. Pain in paraplegia. Clinical management and surgical treatment. *Proc R Soc Med*. 1954;47:281–288.
3. Rolando L. *Ricerche Anatomiche sulla Struttura del Midollo Spinale* [in Italian]. *Dizionario Periodico di Medicina*. Torino: Stamparia Reale; 1824.
4. Ovelmen-Levitt J. The neurobiology of the spinal cord dorsal horn and pathophysiology of neuropathic pain. In: Nashold BS, Pearlstein RD, eds. *The DREZ Operation*. Park Ridge: American Association of Neurological Surgeons; 1996:13–27. Illinois.
5. Cosman ER, Nashold BS, Ovelman-Levitt J. Theoretical aspects of radiofrequency lesions in the dorsal root entry zone. *Neurosurgery*. 1984;15:945–950.
6. Levy WJ, Nutkiewicz A, Ditmore M, Watts C. Laser induced dorsal root entry zone lesions for pain control. Report of three cases. *J Neurosurg*. 1983;59:884–886.
7. Dreval ON. Ultrasonic DREZ-operations for treatment of pain due to brachial plexus avulsion. *Acta Neurochir (Wien)*. 1993;122:76–81.
8. Sindou M. Microsurgical DREZotomy (MDT) for pain, spasticity, and hyperactive bladder: a 20-year experience. *Acta Neurochir (Wien)*. 1995;137:1–5.
9. Sindou M, Quoex C, Balaydier C. Fiber organization at the posterior spinal cord-rootlet junction in man. *J Comp Neurol*. 1974;153:15–26.
10. Mikić D, Spaić M. Biomechanical characteristic of the spinal cord. *Bull Appl Comp Math*. 2002;168–174. Bam XCIX.
11. Spaić M, Marković N, Mikić D, Ilić S, Milosavljević I. The DREZ surgical treatment of chronic pain in traumatic paraplegia. *Ind J Neurotr (IJNT)*. 2005;2:111–116.
12. Ditunno JF, Young W, Donovan WH, Creasy G. The international standards booklet for neurological and functional classification of spinal cord injury. *Paraplegia*. 1994;32:70–80.
13. Melzack R. The Mc Gill pain questionnaire: major properties and scoring methods. *Pain*. 1975;1:277–299.
14. Iacono RP, Aguirre ML, Nashold BS. Anatomic examination of human dorsal root entry zone lesions. *Appl Neurophysiol*. 1998;51:225–229.
15. Young RE. Clinical experience with radiofrequency and laser DREZ-lesions. *J Neurosurg*. 1990;71:715–720.
16. Sindou M, Mertens P, Wael M. Microsurgical DREZotomy for pain due to spinal cord and/or cauda equina injuries: long-term results in a series of 44 patients. *Pain*. 2001;92(1–2):152–171.
17. Friedman AH, Nashold BS. DREZ lesions for relief of pain related to spinal cord injury. *J Neurosurg*. 1986;65:465–469.
18. Rath SA, Braun V, Soliman N, Antoniadis G, Richter HP. Results of DREZ coagulations for pain related to plexus lesions, spinal cord injuries and postherpetic neuralgia. *Acta Neurochir (Wien)*. 1996;138:364–369.
19. Spaić M, Marković N, Tadić R. Microsurgical DREZotomy for pain of spinal cord and cauda equina injury origin: clinical characteristics of pain and implications for surgery in a series of 26 patients. *Acta Neurochir (Wien)*. 2002;144:453–462.
20. Falci S, Best L, Bayles R, Lammertse D, Starnes C. Dorsal root entry zone microcoagulation for spinal cord injury-related central pain: operative intramedullary electrophysiological guidance and clinical outcome. *J Neurosurg (Spine 2)*. 2002;97:193–200.