


Available online at www.sciencedirect.com

ScienceDirect

journal homepage: www.elsevier.com/locate/ijnt

Case Report

An unusual case of orbito-cranial penetrating injury



Pragyan Sarma^a, Dwarakanath Srinivas^{b,*}, Sampath Somanna^c

^a Senior Resident, Department of Neurosurgery, National Institute of Mental Health and Neurosciences (NIMHANS), Hosur Road, Bangalore, Karnataka 560029, India

^b Additional Professor, Department of Neurosurgery, National Institute of Mental Health and Neurosciences (NIMHANS), Hosur Road, Bangalore, Karnataka 560029, India

^c Professor, Department of Neurosurgery, National Institute of Mental Health and Neurosciences (NIMHANS), Hosur Road, Bangalore, Karnataka 560029, India

ARTICLE INFO

Article history:

Received 7 February 2014

Accepted 12 March 2014

Available online 1 April 2014

Keywords:

Knife

Penetrating head injury

Orbital trauma

Cavernous sinus

ABSTRACT

Penetrating orbito-cranial injuries have a potential to cause major mortality and morbidity. They can result due to a variety of numerous intentional or unintentional events. We present a case of a 35-year-old man who came to our emergency services with a penetrating orbito-cranial injury with a knife after an altercation with his friend. He underwent a right fronto temporal craniotomy and the knife was disengaged and removed under direct vision. The patient recovered without any deficits. This case highlights an unusual case, the importance of preoperative radiological imaging and meticulous surgical technique. We also review the available literature.

Copyright © 2014, Neurotrauma Society of India. All rights reserved.

1. Introduction

Penetrating orbito-cranial injuries have a potential to cause major mortality and morbidity. They can result due to a variety of numerous intentional or unintentional events, including gun shot injury, stab wounds, and motor vehicle or occupational accidents (nails, screwdrivers, etc). Stab wounds to the cranium are typically caused by a weapon with a small impact area and low velocity. The most common wound is a knife injury, although bizarre craniocerebral-penetrating injuries have been reported that were caused by nails, metal

poles, ice picks, keys, pencils, chopsticks, and power drills. In available literature, most of the intracranial foreign bodies occur around the orbit, frontal sinus, and the nasal areas. Unless an associated haematoma or infarct is present, cerebral damage caused by stabbing is largely restricted to the wound tract. Sometimes, a narrow elongated defect, or so-called slot fracture, is produced and diagnosed when identified. The following case highlights an unusual and potentially morbid, penetrating orbito-cranial stab injury and highlights the importance of meticulous preparation, comprehensive radiological imaging and multidisciplinary approach in successful management.

* Corresponding author. Tel./fax: +91 80 (0) 26995724.

E-mail address: dwarakaneuro@yahoo.com (D. Srinivas).

<http://dx.doi.org/10.1016/j.ijnt.2014.03.002>

0973-0508/Copyright © 2014, Neurotrauma Society of India. All rights reserved.

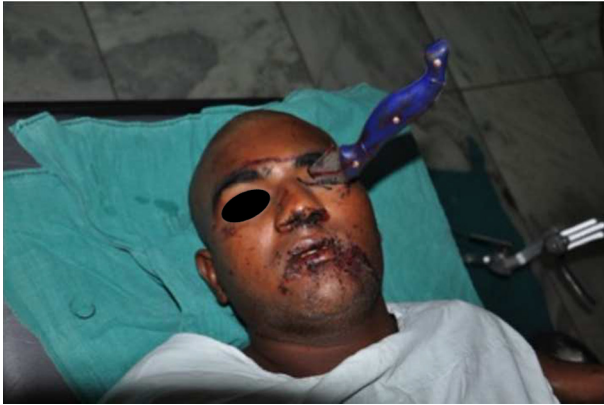

Fig. 1 – Clinical photograph showing the knife was entering through the left orbit.

2. Case report

A 35-year-old man was brought to our emergency services with a stab injury with a knife after an altercation with his friend after a drinking binge. On examination, the knife was entering through the left orbit (Fig. 1). Apart from an inability to open the left eye, the patient was completely preserved. The Glasgow coma scale (GCS) score on admission was E4V5M6. A Skull radiograph (anteroposterior and lateral views) and a Computerised Tomogram of the Head (CT) showed the knife entering through the left orbit traversing the ethmoid sinus, the right superior orbital fissure, lateral wall of the right cavernous sinus and embedding in the right petrous temporal bone (Fig. 2A and B, 3A and B). The left ocular globe was intact because the “burst” fracture of the orbital compartment (a comminuted fracture of the floor, roof, lateral and medial orbital walls) allowed the ocular globe to undergo a downward displacement without being smashed against an osseous wall. A CT angiogram showed no signs of an associated vascular injury.

The patient underwent emergency surgery to remove the knife. A fronto temporal craniotomy was performed with a zygotomy. Dura was stripped away from the V2 V3 segment of

the Vth nerve to expose the lateral wall of the cavernous sinus. The knife was seen entering the middle cranial fossa through the superior orbital fissure, then traversing the lateral wall of the right cavernous sinus going under the trigeminal nerve and entering the petrous bone (Fig. 4). The knife was exposed completely, disengaged and gradually pulled out under direct vision. A meticulous irrigation of the operative field was performed and the wound closed. The patient was on broad spectrum antimicrobial therapy postoperatively. The patient made an uneventful recovery without any focal neurological signs (Fig. 5). The left ocular globe was completely undamaged and visual acuity remained intact.

3. Discussion

A wound in which the projectile breaches the cranium but does not exit is described technically as penetrating, and an injury in which the projectile passes entirely through the head, leaving both entrance and exit wounds, is described as perforating. Penetrating orbito-cranial wounds by medium energy stab injuries like the one outlined are unusual. Unlike a high velocity injury Eg: Gun shot wounds, the damage is restricted to the tract of the object. Penetrating stab intracranial injuries caused by metallic foreign bodies are unusual among the civilian population. Only a few cases have been reported in the literature in the last two decades, but medical reports of stab wounds of the brain date from as early as 1806.^{1,2} The literature provides a long list of objects known to have penetrated the brain, which include knives, chopsticks, pitchforks, crochet hooks, knitting needles, brooch pins, umbrella tips, crowbars and iron rods, car antennas and scissors.³⁻⁶

Penetrating orbito-cranial injuries, though unusual, are potentially very morbid due to the structures they traverse through and which can cause disastrous consequences. These include rupture of the globe, cranial nerve transections, cortical injury and vascular compromise. Vascular compromise may be due to direct vascular trauma of the internal carotid artery both in its intracavernous and paraclinoid segment, to distortion of the vessel due to local effects such as haematoma formation or oedema, or vasospasm.⁷ Non-

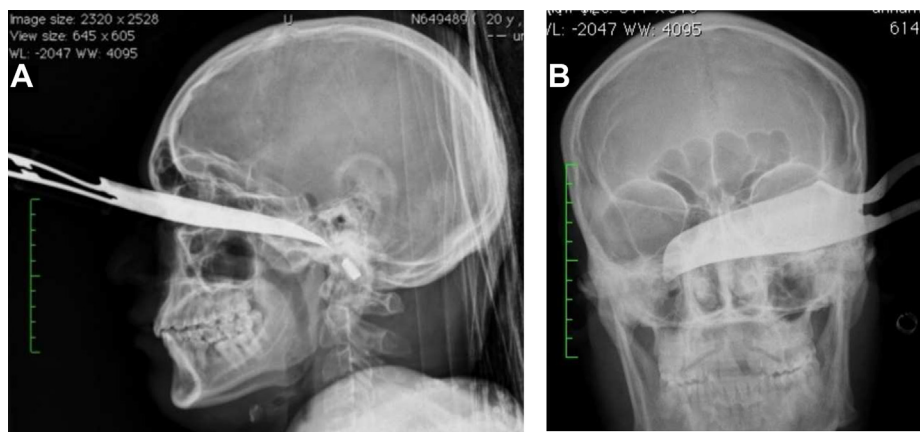


Fig. 2 – A,B: Skull radiograph (anteroposterior and lateral views): Showing the trajectory of the knife.

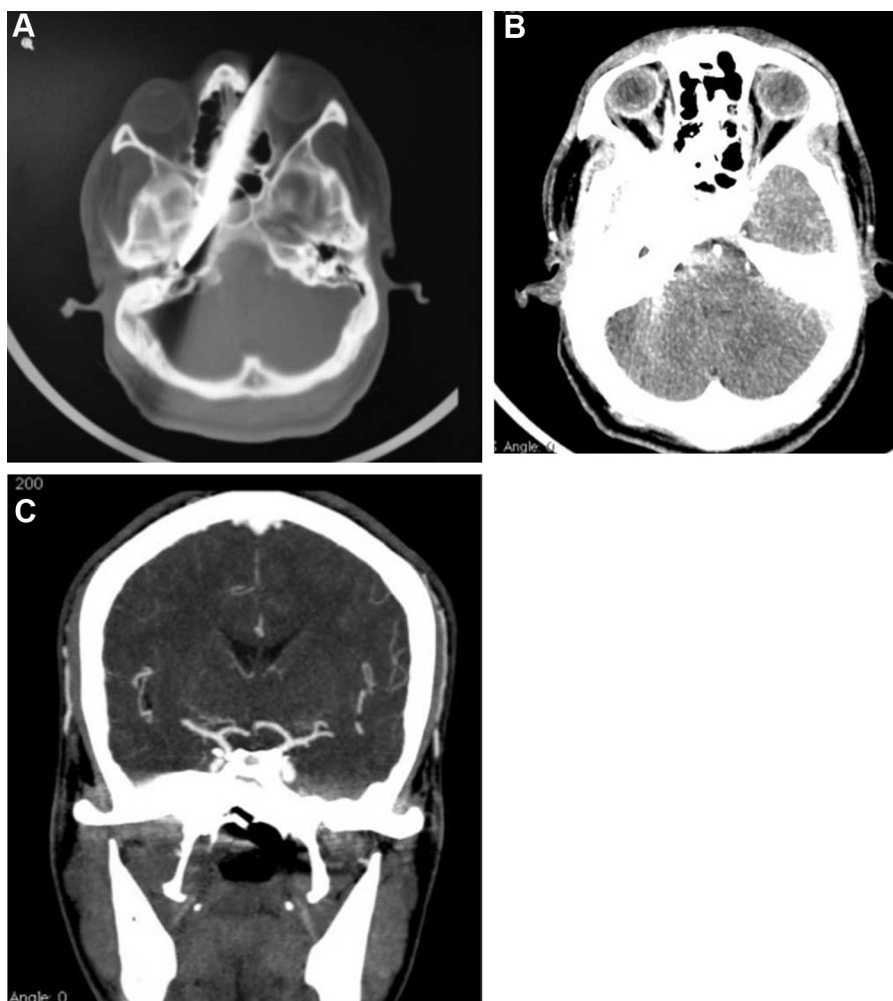


Fig. 3 – A: Computerised Tomogram of the Head (CT): Showing the knife entering through the left orbit traversing the ethmoid sinus, the right superior orbital fissure lateral wall of the right cavernous sinus and embedding in the right petrous temporal bone. The maxillary division of the Trigeminal nerve can be seen. **B,C:** CT Angiogram axial and coronal showing no obvious vascular injury and good distal filling.

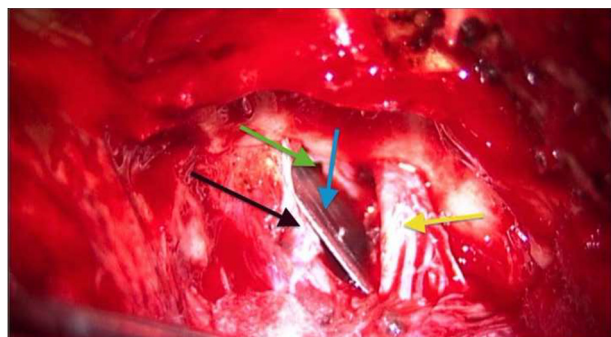


Fig. 4 – Intraoperative photograph showing the knife (Blue arrow) was seen entering the middle cranial fossa through the superior orbital fissure (Green Arrow), then traversing the lateral wall of the right cavernous sinus (Black Arrow) going beside and then under the trigeminal nerve and entering the petrous bone. The maxillary division of the Trigeminal nerve can be seen (Yellow arrow).

contrast cranial and maxillofacial CT scan, which is the best imaging modality for this type of trauma, can help analyse the trajectory of the foreign body and observe whether the object went through any areas of major vascular significance, including the ICA (especially within the cavernous sinus) and the anterior and middle cerebral arteries. In case of suspicion for vascular injury, an angiography should also be performed to evaluate for traumatic aneurysm, which can develop soon after a penetrating injury.⁴ de Villiers et al in his series on stab injuries, reported a mortality of 17%, mostly related to vascular injury and massive intracerebral haematomas.^{1,7} Also, infections can easily complicate penetrating craniocerebral injuries and patients can develop meningitis, epidural abscess, subdural empyemas, or brain abscess. Therefore, prevention and proper management of infectious complications can lead to improved outcomes in these patients. Patients in whom the penetrating object is left in place until surgical removal have a significantly lower mortality than those in whom the objects are inserted and then removed (26% versus 11%, respectively).⁷

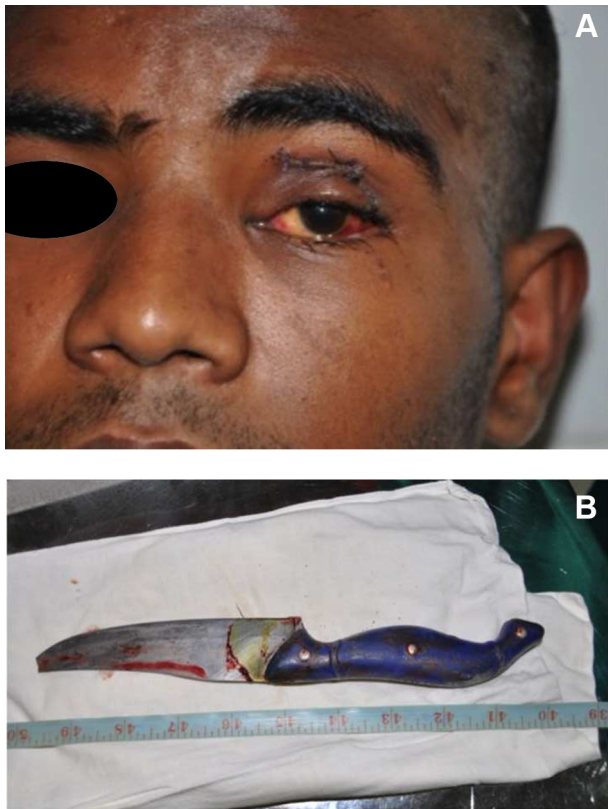

Fig. 5 – A: Clinical photograph (post operative) showing the patient to be completely preserved. B: The removed Knife. The tip was broken and was embedded in the petrous bone.

Penetrating craniocerebral stab injuries are more amenable to treatment than missile injuries. A stab wound creates a narrow hemorrhagic infarction which is mainly restricted to the wound tract. Concentric zones of coagulative necrosis do not result from stab wounds as they do from explosives and from the cavitating forces of missiles. Similarly, contre-coup injuries rarely occur, if at all, from stab wounds. Unless the stabbing instrument is swept across the brain before withdrawal, the resultant lesion is usually focal. Therefore, when there are no direct injuries to the brain stem or direct lacerations of a major vessel, the prognosis for recovery in such type of cranial injury may be good. Frontal

stabs are accompanied by the least morbidity and mortality, while penetrating orbito-cranial stab injuries characteristically cause considerable morbidity and mortality by direct damage to brain structures, vascular compromise, or infection.

4. Conclusion

Our case, a highly unusual one, highlights the importance of meticulous planning, comprehensive radiological imaging and immediate surgery involving a multidisciplinary team. Blind removal of the intracranial object may cause neurological and vascular injuries if the trajectory is close to major vessels or to important neural structures. Therefore, an adequate surgical access allowing intracranial direct visualisation of the object should be performed before its withdrawal.

Conflicts of interest

None declared.

REFERENCES

1. de Villiers JC. Sixteen cases of transorbital stab wounds of the head. *J Neurol Neurosurg Psychiatry*. 1975;38(8):822.
2. Domenicucci M, Qasho R, Ciappetta P, Vangelista T, Delfini R. Surgical treatment of penetrating orbito-cranial injuries. Case report. *J Neurosurg Sci*. 1999;43(3):229–234.
3. Mitilian D, Charon B, Brunelle F, Di Rocco F. Removal of a chopstick out of the cavernous sinus, pons, and cerebellar vermis through the superior orbital fissure. *Acta Neurochir*. 2009;151(10):1295–1297.
4. Schreckinger M, Orringer D, Thompson BG, La Marca F, Sagher O. Transorbital penetrating injury: case series, review of the literature, and proposed management algorithm. *J Neurosurg*. 2011;114(1):53–61.
5. MacEwen CJ, Fullarton G. A penetrating orbitocranial stab wound. *Br J Ophthalmol*. 1986;70:147–149.
6. Subaşı M, Cakar-Ozdal MP, Nalcioğlu-Yüksekkaya P, Alakuş A. Management of an orbitocranial knife injury: a case report. *Turk J Pediatr*. 2012;54(2):184–186.
7. De Villiers JC, Sevel D. Intracranial complications of transorbital stab wounds. *Br J Ophthalmol*. 1975;59(1):52–56.