


Available online at [www.sciencedirect.com](http://www.sciencedirect.com)

ScienceDirect

journal homepage: [www.elsevier.com/locate/ijnt](http://www.elsevier.com/locate/ijnt)

## Case Report

# Emergency management strategy for pregnant head trauma victims – Case reports and review of literatures



Mani Charan Satapathy<sup>a,\*</sup>, Sudhansu Sekhar Mishra<sup>b</sup>, Srikanta Das<sup>c</sup>,  
Manmath K. Dhir<sup>c</sup>

<sup>a</sup> Department of Neurosurgery, S.C.B. Medical College, Cuttack, Odisha 753001, India

<sup>b</sup> Professor and Head, Department of Neurosurgery, S.C.B. Medical College, Cuttack, Odisha 753001, India

<sup>c</sup> Associate Professor, Department of Neurosurgery, S.C.B. Medical College, Cuttack, Odisha 753001, India

## ARTICLE INFO

## Article history:

Received 27 January 2014

Accepted 5 April 2014

Available online 9 May 2014

## Keywords:

GCS

TBI

Fetus

Pregnancy

Head injury

## ABSTRACT

**Background:** Several literatures support, trauma complicates 6–7% of all pregnancies. Despite the rapid progressiveness of traumatic brain injury (TBI) worldwide, there is paucity of literature regarding the exact incidence of TBI in pregnancy. Management poses a great challenge, because of the anatomical, physiologic changes and the consideration of existence of two lives till the end.

**Case descriptions:** We report three cases of TBI with pregnancy admitted during August 2013–December 2013 and treated in our institution with the aim to evaluate the outcome in mother in relation to post-resuscitation GCS and GOS with a secondary objective to assess the fetus. All of them recovered well with intrauterine live fetus at the time of discharge.

**Conclusion:** Management of TBI with pregnancy always needs multidisciplinary approach in order to optimize the outcomes for mother and fetus. If, managed conservatively there should be rational and judicious medications with very minimal fetal risks. Surgical management is warranted when benefits outweigh risks. Proper seat belt use is the most significant modifiable factor in decreasing maternal and fetal injury and mortality after motor vehicle crashes.

Copyright © 2014, Neurotrauma Society of India. All rights reserved.

## 1. Introduction

Head and neck injuries, respiratory failure and hypovolemic shock constitute the three most common causes of trauma related maternal death in pregnancy.<sup>1</sup> Trauma is the commonest non-obstetrical cause of death in pregnant women

complicating 6–7% of all pregnancies.<sup>2</sup> TBI though less common than abdominal trauma during pregnancy, is more potential in terms of morbidity and mortality. Common aetiologies for trauma are motor vehicle accidents (54.6%), falls (21.8%), violent assaults, and burn injuries.<sup>3</sup> Pregnancy must always be suspected in any female of childbearing age with TBI until proved otherwise.<sup>4</sup> Successful management always

\* Corresponding author. Tel.: +91 9439803988.

E-mail address: [drmcsatappathy@gmail.com](mailto:drmcsatappathy@gmail.com) (M.C. Satapathy).  
<http://dx.doi.org/10.1016/j.ijnt.2014.04.001>

0973-0508/Copyright © 2014, Neurotrauma Society of India. All rights reserved.

needs multidisciplinary approach involving neurosurgeon, anesthesiologist and the obstetrician.<sup>5</sup> Management consists of in the sequence of hemodynamic stabilization of the mother, detailed neurological assessment, then the secondary survey considering the fetal evaluation and the extent of uterine injury.

## 2. Case descriptions

### 2.1. Case – 1

A 25-year female, GA ~24 weeks, pillion rider, presented 10 h after the moderate head injury with h/o loss of consciousness (LOC) and vomiting on examination, GCS-11/15 with CT scan brain showing Rt. hemispheric acute subdural hematoma (ASDH) with mass effect (Fig. 1a). Immediately, we did craniotomy with evacuation of hematoma of about 40 ml. Repeat CT scan on post-op day 4 showed complete evacuation of ASDH without any mass effect (Fig. 1b). She was discharged with GCS-14/15, GOS-4/5 with live fetus in utero after 7 days of hospitalization.

### 2.2. Case – 2

A 32-year female, GA ~16 weeks, fall in bathroom, presented 2 h after moderate head injury with h/o transient LOC and vomiting on examination GCS-14/15 with CT scan showing Lt. frontal contusion (Fig. 2a). On repeat CT scan after 4 days, contusion was resolving (Fig. 2b). She was discharged with GCS-15/15, GOS-5/5 with live foetus in utero after 5 days of hospitalization.

### 2.3. Case – 3

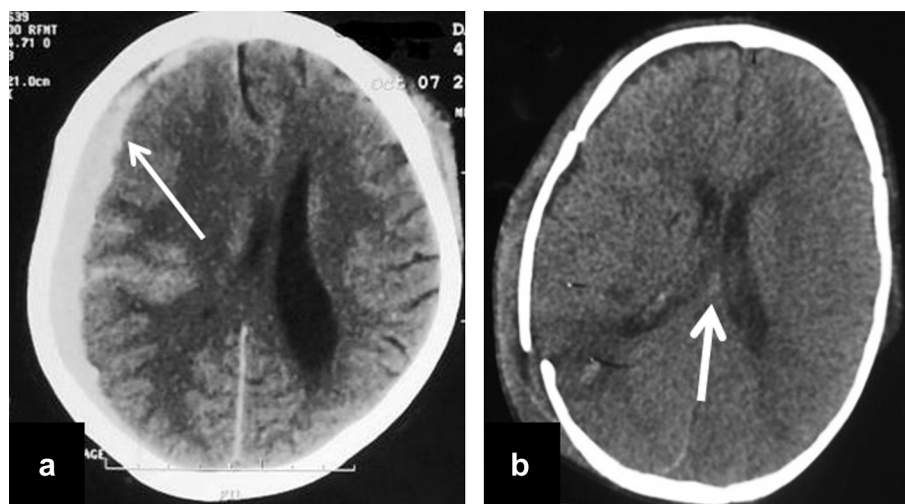
A 35-year female, GA ~28 weeks, ejected from car through the improperly locked side door without seat belt presented 4 h after the severe head injury with h/o LOC since then and

vomiting, on examination GCS-7/15 with CT scan brain showing Lt. temporal contusion with cerebral edema (Fig. 3a). She was immediately shifted to ICU, intubated, ventilated and weaned three days after. She was discharged with GCS-12/15, GOS-4/5 with live fetus in utero after 9 days of hospitalization (Fig. 3b).

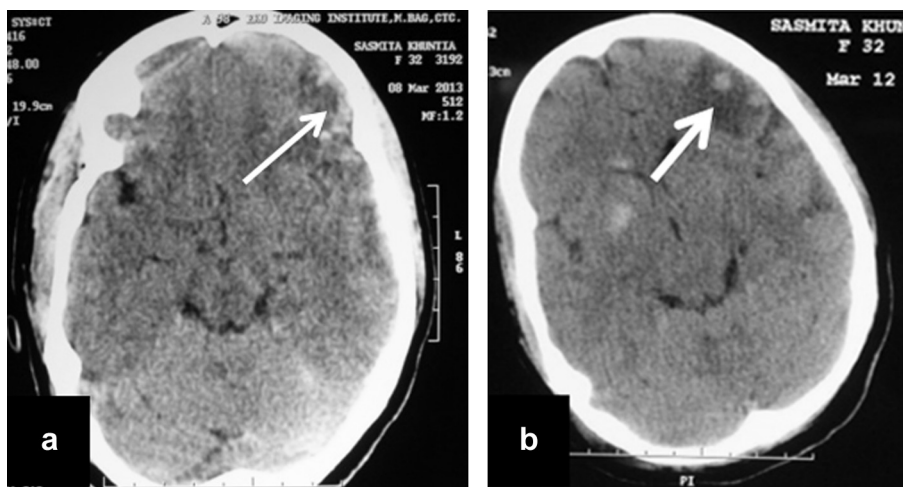
We managed all the patients with initial evaluation and resuscitation at casualty, subsequently in neurotrauma ICU at par with CT scan of brain finding, neurological status. One patient with GCS-7/15 was considered for intubation and ventilator support. While mother is being resuscitated, fetal evaluation was done timely by the obstetrician. At the time of discharge, outcome for mother assessed by Glasgow Outcome Score (GOS) and fetal evaluation was done by the obstetrician. All were followed up till the term pregnancy. Of three patients, two had normal vaginal and one caesarean delivery.

## 3. Discussion

The best way to treat the fetus is to treat the mother; hence the initial highest priority is stabilization of the mother. Pregnancy must always be suspected in any female TBI patient of child-bearing age until proved otherwise and confirmed by examination of the uterus, ultrasound, and/or serum HCG testing.<sup>4</sup> Some physiological changes during pregnancy e.g. relative hemodilution and hypervolemic state (compensating 40% of blood volume), hypercoagulable state, physiological hyperventilation (raised tidal volume, normal respiratory rate, and respiratory alkalosis), and increased incidence of nausea, vomiting, and aspiration (secondary to mechanical and hormonal effects), must be considered before initial assessment.<sup>5</sup> The initial assessment of consists of thorough evaluation, stabilization, and resuscitated in left lateral position to prevent supine hypotension syndrome.<sup>5</sup> It is recommended that a Glasgow Coma Scale (GCS)  $\leq 8$  needs intubation and mechanical ventilation or both for both airway control and control of ICP.<sup>5,6</sup> Maternal health proceeds over that of the fetus and is of primary concern unless vital signs cannot be



**Fig. 1 – (a) CT scan of brain showing hyperdense biconvex lesion in the Rt. frontotemporoparietal region suggestive of acute subdural hematoma (ASDH) with mass effect. (b) Repeat CT scan of brain on postoperative day – 4 showing complete evacuation of ASDH without mass effect.**



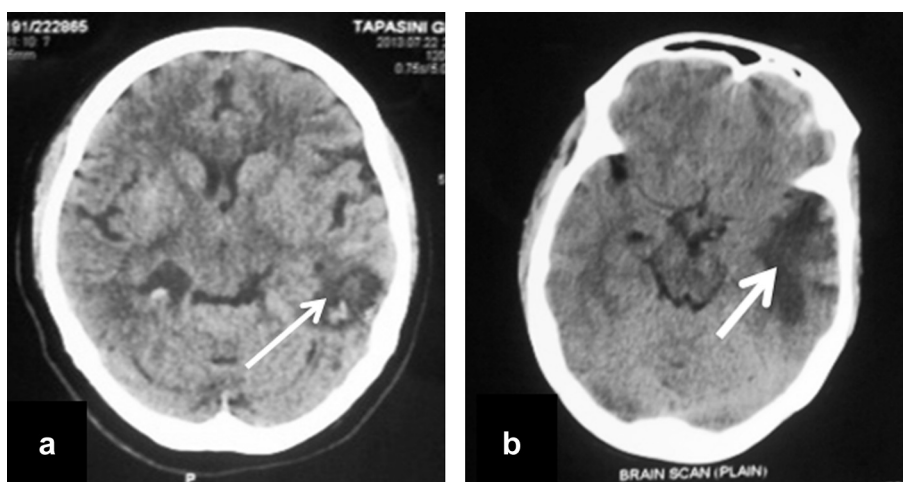
**Fig. 2 – (a) CT scan of brain showing hypodense lesion in the Lt. Frontal region suggestive of hemorrhagic contusion. (b) Resolving contusion on repeat CT scan of brain 4 days after conservative management.**

maintained in the mother. Maintenance of euvoletic status by early transfusion of blood components rather than crystalloids is the current recommendation. TBI with suspicious integrity of the cervical spine, direct laryngoscopy should be avoided, instead awake fiberoptic intubation to be considered.<sup>5</sup> The goals consist of maintenance of SBP at 80–100 mmHg, hematocrit at 25%–36%, TPC >50,000/cu mm, normal serum calcium, core body temperature >35 °C, avoiding rise in serum lactate level and metabolic acidosis and adequate analgesia.<sup>5</sup> Monitoring the mother for overt signs of shock is notoriously unreliable as an indicator of fetal well being. Several studies have shown that maternal pulse, blood pressure, and PO<sub>2</sub> are not reliable predictors of fetal demise. However, Scorpio et al, recommended use of serum bicarbonate measurement on admission has statistically significant correlation with fetal loss.<sup>7</sup> Detailed neurological functional assessment follows after the hemodynamic stabilization only.<sup>8</sup>

On hospitalization, pregnant women with TBI should undergo some common laboratory studies, but with initial

stabilization (Table 1). After initial stabilization, status of fetus and extent of uterine injury determine further management.<sup>8</sup> A secondary survey includes an early vaginal and rectal examination. Gestational age (GA) is initially estimated by fundal height, and confirmed by bedside ultrasound. Viable fetus without distress is best monitored by fetal Doppler USG and external tocotransducer. If premature labor ensues, tocolytic therapy may be initiated. Viable fetus with distress, caesarean delivery is a must. Nonviable fetus can be managed conservatively in the uterus optimizing maternal oxygenation and circulation.<sup>9</sup> If obvious maternal shock is noticeable, then saving the fetus is only 20%.<sup>9</sup>

Conservative management needs judicious, rational use of medications. Antibiotics are prescribed for appropriate indications and for shortest effective duration. Mannitol is used when clearly needed and benefit outweighs the risk. Furosemide crosses placenta, hence to be used judiciously. Among antiepileptics, monotherapy is preferred. Carbamazepine is considered to be safe. Valproate, phenytoin, phenobarbitone



**Fig. 3 – (a) CT scan of brain showing hypodense lesion in the Lt. Parietal region suggestive of hemorrhagic contusion. (b) Resolving contusion on repeat CT scan of brain 3 days after conservative management.**

**Table 1 – Common laboratory studies for pregnant trauma patients.**

- Complete blood count
- Comprehensive metabolic panel
- Urinalysis
- Blood group – type and cross
- Kleihauer–Betke testing
- Fibrinogen and PT/PTT
- Basic ultrasound: no. of fetuses, FHR, fetal position, amniotic fluid volume, placental location and appearance, gestational age assignment, basic anatomy (if possible)
- Additional imaging studies e.g. CT scan, MRI, Pelvic X-ray as clinically indicated

are avoided. Newer drugs e.g. levetiracetam, lamotrigine are being preferred now a days.<sup>8</sup>

Timing of surgery is a great challenge for neurosurgeon, anesthetist. Conflicting data exist concerning the effect of first trimester anesthesia on the rate of spontaneous abortion. Duncan and colleagues, reported an increased risk of spontaneous abortion among patients undergoing general anesthesia (risk ratio = 1.58).<sup>10</sup> Incidence of spontaneous abortion (15–20%) and congenital abnormalities (3–5%) is high enough in the first 13 weeks.<sup>5</sup> Between 13 and 23 weeks' gestation, the uterus is less sensitive to the stimulating effects of surgery, hence the safe period for trauma surgery. After 24 weeks' gestation, trauma surgery can produce three complications: supine hypotension, neurodevelopmental delay in the offspring, and preterm birth.<sup>5</sup> Emergency surgery is done regardless of GA, usually in second trimester.<sup>11</sup>

The use of general anesthesia is steadily declining, when considered, a crash induction with cricoid pressure, to decrease the risk of regurgitation and aspiration of gastric contents, is indicated. Lung denitrogenation with 100% oxygen is mandatory before rapid sequence induction during general anesthesia.<sup>12</sup> Intravenous induction agents like, propofol and thiopental sodium, may potentiate profound hypotension or even cardiac arrest, hence the alternative Etomidate. Ketamine is safe due its central nervous system stimulating effect. Succinylcholine remains the muscle relaxant of choice, else the rocuronium. Thus, all anesthetic drugs must be used cautiously in head injury patients with life-threatening hypovolemia.<sup>6</sup> Nevertheless, aggressive maternal resuscitation always be the initial highest priority, rather than concerns about intracranial pressure or neuroanesthesia, which often proves lifesaving for both the parturient and her fetus.<sup>13</sup>

The finding that head injury alone is associated with loss of pregnancy is relatively novel. One explanation may be the findings by Kelley and colleagues, demonstrating some degree of hypopituitarism in 40% of patients with moderate to severe head injury, with growth hormone and gonadotrophic deficiencies being the most common.<sup>14</sup>

Proper seat belt use is the most significant modifiable factor in decreasing maternal and fetal injury and mortality after motor vehicle crashes. It should be placed below the gravid abdomen, snugly over the thighs, with the shoulder harness off the side of the uterus, between the breasts and over the midline of the clavicle. Seat belts placed directly over the uterus can cause fetal injury.<sup>15</sup>

#### 4. Conclusion

Pregnancy is the major challenge in trauma care because of the risks to both mother and child, and because of difficulties in following standard protocols. Successful treatment and outcome of a pregnant woman requires a careful, rapid individualized multidisciplinary team approach to optimize outcomes for mother and fetus. The initial resuscitation of the mother should follow advanced trauma life support (ATLS). If, managed conservatively there should be rational and judicious medications with very minimal fetal risks. Surgical management is warranted when benefits outweigh risks. It is the coordinated, timely, team efforts that worked well in making all of them survived out of the head injury sequels.

#### Conflicts of interest

All authors have none to declare.

#### REFERENCES

1. Baker BW. Trauma. In: Chestnut DH, ed. *Obstetric Anesthesia: Principles and Practice*. St Louis: Mosby; 1999:1041–1050.
2. Shah AJ, Kilcline BA. Trauma in pregnancy. *Emerg Med Clin North Am*. 2003;21:615–629.
3. Connolly AM, Katz VL, Bash KL, et al. Trauma and pregnancy. *Am J Perinatol*. 1997;14:331–335.
4. Flik K, Kloen P, Toro JB, et al. Orthopedic trauma in the pregnant patient. *J Am Acad Orthop Surg*. 2006;14:175–182.
5. Reddy SV, Shaik NA, Gualala K. Trauma during pregnancy. *J Obstet Anaesth Crit Care*. 2012;2:3.
6. Barker SJ. Anesthesia for trauma. *Anesth Analg Suppl*. 2003;96:1–6.
7. Scorpio RJ, Esposito TJ, Smith LG, Gens DR. Blunt trauma during pregnancy: factors affecting fetal outcome. *J Trauma*. 1992;32:213–216.
8. Rudra A, Ray A, Chatterjee S, et al. Trauma in pregnancy. *Indian J Anaesth*. 2007;51:100–105.
9. Drost TF, Rosemurgy AS, Sherman HF, Scott LM, Williams JK. Major trauma in pregnant women: maternal/fetal outcome. *J Trauma*. 1990;30:574–578.
10. Duncan PG, Pope WD, Cohen MM, Greer N. Fetal risk of anesthesia and surgery during pregnancy. *Anesthesiology*. Jun 1986;64(6):790–794.
11. Liu PL, Warren TM, Osteimer GW, et al. Foetal monitoring in parturients undergoing surgery unrelated to pregnancy. *Can Anaesth Soc J*. Sep 1985;32(5):525–532.
12. Butler J, Sen A. Best evidence topic report. Cricoid pressure in emergency rapid sequence induction. *Emerg Med J*. 2005;22:815–816.
13. Kuczkowski KM. Trauma in the pregnant patient. *Curr Opin Anaesthesiol*. 2004;17:145–150.
14. Kelly DF, Gonzalo IT, Cohan P, et al. Hypopituitarism following traumatic brain injury and aneurysmal subarachnoid haemorrhage: a preliminary report. *J Neurosurg*. 2000;93:743–752.
15. Pearfman MD, Klinich KD, Schneider LW, Rupp J, Moss S, Ashton-Miller J. A comprehensive program to improve safety for pregnant woman and fetuses in motor vehicle crashes: a preliminary report. *Am J Obstet Gynecol*. 2000;182:1554–1564.