


Available online at www.sciencedirect.com

ScienceDirect

journal homepage: www.elsevier.com/locate/ijnt

Original Article

“Bone-mesh”: Combined fractured bone and titanium mesh for primary reconstruction of compound skull fractures



Somnath Prasad Jena ^{a,*}, Pratap Chandra Nath ^a, Rama Chandra Deo ^b,
Sudhansu Sekhar Mishra ^c

^a 2nd Year MCh Trainee, Department of Neurosurgery, SCB Medical College and Hospital, Cuttack, Odisha, India

^b Assistant Professor, Department of Neurosurgery, SCB Medical College and Hospital, Cuttack, Odisha, India

^c Professor and Head, Department of Neurosurgery, SCB Medical College and Hospital, Cuttack, Odisha, India

ARTICLE INFO

Article history:

Received 30 July 2014

Accepted 21 November 2014

Available online 6 December 2014

Keywords:

Primary reconstruction

Compound fracture

Bone-mesh

ABSTRACT

Problem considered: Skull fractures account for a large number of traumatic brain injuries and these injuries warrant urgent medical attention. Their variety in location, the magnitude of intra-cranial injuries, and a fairly cautious approach to reconstruct primarily have led to a lack in consensus in the management of these injuries. The long standing practice of removal of bone is giving way to single stage repair. The aim of the study was to analyze the benefits and adverse effects of primary reconstruction of skull using combination of the fractured fragments of bone and titanium mesh as the cranioplasty material. **Methods:** Patients with compound fractures of skull, between the ages of 18–65 years, were planned for primary reconstruction with fractured bone fragments and titanium mesh after dealing with the intra-cranial lesion. Patients were observed daily for clinical signs of infections and alternate day lab checks (WBC counts) were performed. Post-operative CT scans with 3-dimensional skull reconstruction was obtained before discharge and assessment of cosmetic results were done.

Results: Eleven male (mean age 32.63 ± 10.87 years) patients underwent primary reconstruction of compound skull fractures. The mean interval between injury and operation was 62.2 ± 21 h. The mean duration of surgery was 162.7 ± 32.3 min 9 had a Glasgow outcome Score (GOS) of 5, 1 had GOS 4, 1 had death, resulting from sepsis. Mean follow-up is 2.81 months and no complications could be observed within this period.

Conclusion: Primary reconstruction of compound fractures should be attempted in any possible case, even in ones with delayed presentation. When done with native bone fragments and titanium mesh provides cosmesis, protection, prevention of skin flap syndrome and better strength of construct. Although the rate of infection has been nil in our series, a larger series with longer follow-up is warranted before introducing into clinical practice.

Copyright © 2014, Neurotrauma Society of India. All rights reserved.

* Corresponding author. +91 9861117573 (mobile).

E-mail address: somnath.jena@gmail.com (S.P. Jena).

<http://dx.doi.org/10.1016/j.ijnt.2014.11.007>

0973-0508/Copyright © 2014, Neurotrauma Society of India. All rights reserved.

1. Introduction

Reconstruction of human skulls has been a need for both patients and surgeons alike since the advent of trephination, probably the oldest known surgical technique dating back to the Inca civilization around 3000 BC.¹ Skull fractures account for a large number of traumatic brain injuries, among these, compound skull fractures account for around 25%,² and these injuries warrant urgent medical attention. What has plagued the treatment of skull fractures is that their variety in location, the magnitude of intra-cranial injuries, and a fairly cautious approach to reconstruct primarily have led to a lack in consensus in the definitive management of these injuries. Compound fractures have been known to be associated with a myriad of underlying injuries ranging from hematomas, contusions to sagittal sinus injuries. Removal of fractured segments in a staged procedure is responsible for temporary cosmetic disfigurement, a potential for injury in the area of defect and a likelihood of a sunken scalp syndrome.

This dilemma in definitive management of compound skull fractures has evolved in the last few decades. For a long time prior to that it was standard and unquestioned practice to remove the bone fragments, debride the wound and leave a cranial defect to be repaired later.³ The past few decades have seen the evolution of several materials for cranioplasty, ranging from autologous bone, methyl methacrylate, titanium mesh to computer aided ceramic synthetics. The dynamics and outcome of use of these materials alone or in combination to each other, primarily to reconstruct the compound skull fractures remains to be assessed.

2. Aim of the study

The aim of the study was to analyze prospectively the benefits and adverse effects of primary reconstruction of skull using combination of the fractured fragments of bone and titanium mesh as the cranioplasty material, and to detail the technique of fracture reconstruction with mesh and bone in our preliminary experience.

3. Materials and methods

Patients with compound, displaced (elevated, depressed or distracted) fractures of skull, with or without underlying injuries, between the ages of 18–65 years, and having given informed consent for the procedure were included in the study. Those patients with clinical or radiological need for decompressive craniotomy or with gross visible wound contamination with foreign body were excluded. They were planned for primary reconstruction with fractured bone fragments and titanium mesh (Cranial Fixation System, Cranial Mesh), after dealing with the intra-cranial lesion. This study was conducted from January 2014 through May 2014. After initial resuscitation, and screening of concomitant injuries, a pre-operative computed tomography (CT) scan was obtained and evaluated, and planned for surgery.

3.1. Technique

Under general anesthesia, the patients underwent extension of the existing skin wound if necessary, followed by preliminary debridement of the wound both mechanically (trimming of wound margins and devitalized tissue) and using diluted hydrogen peroxide. Then the depressed and fractured bone fragments were removed with due care to prevent further injury to the brain. The extracted bone fragments were further treated with hydrogen peroxide and kept separately in a sterile container. Following this the intracranial pathology was dealt with and the dura was closed primarily or with pericranial patch or Synthetic Fabric Patch. In case of open air sinuses with violation of the mucosa, exenteration of mucosal lining was done and the sinus was packed with antibiotic soaked gel-foam and or pericranium. Only the larger fragments of bone were then used for reconstruction. Prior to fixation, these bone pieces were matched to the site from which they came, and the point for fixation of titanium mesh or mini-plates (Cranial Fixation System, Two hole straight plates) were marked, if required the mesh was fashioned and shaped according to the contour needed using the mesh cutter and mesh bender. After marking the exact points of fixation the bone fragments were again brought out and on a sterile trolley the exact construct comprising the bone and the titanium mesh were assembled using Miniscrews (Cranial Fixation System, Self Tapping Screw). This assembled unit of bone-mesh (Fig 1) was taken into the cranial defect for fixation. This reconstruction was followed by meticulous wound closure.

3.2. Post-op and follow-up

Post operatively the patients were managed in the intensive care unit or the Neurotrauma ward as was found necessary. Prophylactic anti-biotic was continued for 7–10 days post-operatively. Patients were observed daily for clinical signs of infections and alternate day lab checks (WBC counts) were performed. Post-operative CT scans with 3-dimensional skull




Fig. 1 – Intra-Operative picture showing Assembled Bone-Mesh Unit prior to cranial fixation, here the mesh forms a scaffold to solve the “puzzle” made by broken bone fragments.

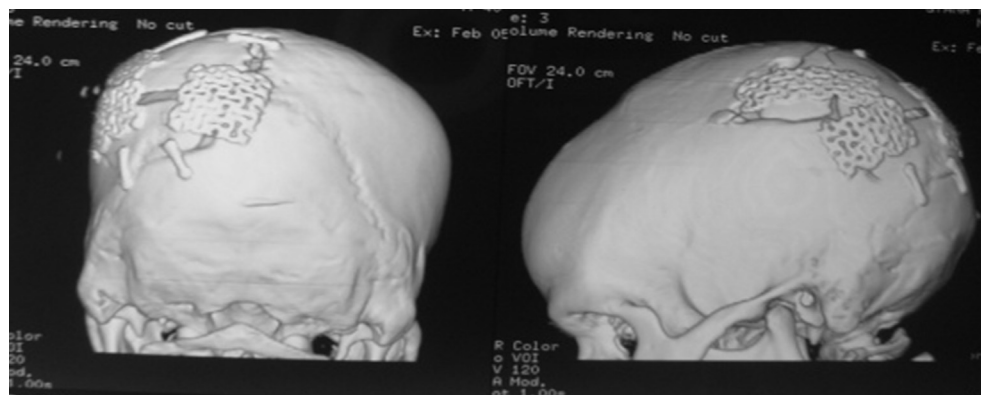


Fig. 2 – Post-operative 3-D CT reconstruction of the skull showing the repaired compound fracture in the Left Parieto-Occipital region with native bone fragments, titanium mesh and mini-plates, resulting in a stable construct, even for bearing the load of the head when recumbent.

reconstruction was obtained before discharge and a subjective assessment of cosmetic results were done in a 3-tiered scale (excellent, good, poor) based on surgeon's evaluation and patient's subjective opinion at 1 month during clinical follow-up examination.³ This cosmetic result was based on the patient and Surgeon's perception of the skull contour and in case of difference in the two opinions the worse grade was taken into account.

3.3. Concept

The concept of primary reconstruction was to close the defect and preserve the anatomical barrier, to avoid a later cranioplasty and to prevent further complication like CSF leak, Pneumocephalus, brain fungus. Further rigid fixation was done to achieve good cosmetic results.⁴ Bone-Mesh was used preferentially to only bone and miniplate-screw, to improve cosmetic result (Fig 3), for better strength of the construct when the patient may need early use of the part of the calvarium when recumbent (Fig 2). It also confers better alignment of bone fragments during fixation, gives better results from the puzzle created by multiple bone fragments (Fig

1). The titanium mesh used works as a scaffold for bone fixation, helps fill bony defects which remain vacant due to crushed, unusable bones, and as a rigid structure to bring together the distracted cranial convexity and anterior skull base as in case no 10 (Table 1, Fig 4). This Bone-mesh was used preferentially to only mesh in order to avoid potential dead-space between mesh and dura; this dead-space could potentially allow collection. Bone-mesh also allows a potential osteo-integrative and osteo-inductive character innate to titanium mesh, which when used to bridge small defects allows ingrowth of bone from patients own fractured calvarial bone.

4. Results

Eleven male patients (mean age 32.63 ± 10.87 years) underwent primary reconstruction of compound skull fractures (Table 1.). Nine of the cases resulted from road traffic accident and two were caused by assault with sharp object. Of the eleven patients, six patients presented with mild head injury, three presented with moderate and two presented with severe head injury (Fig 5).

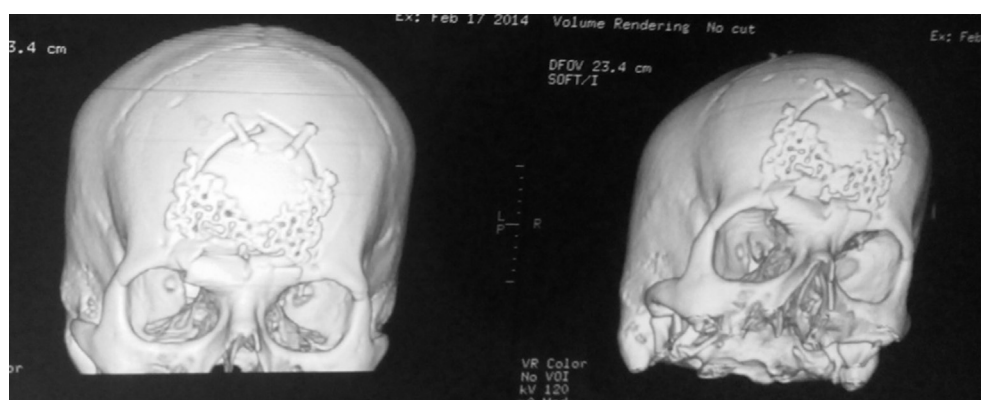

Fig. 3 – Post-operative 3-D CT reconstruction of the skull showing the repaired compound fracture in the mid-Frontal region with native bone fragments, mini-plates, titanium mesh resulting in a stable and cosmetically acceptable construct, the patient had an underlying EDH and superior Saggital sinus injury.

Table 1 – Patients characteristics and overview of assessed parameters in Neurosurgical treatment for compound skull fractures in 11 patients.

Case no.	Age	Sex M/F	MOI	GCS	Injury-ot interval (hours)	Fracture localization F/T/P	Underlying injury	Opening of air sinus	Operating time (mins)	Outcome (GOS)	Cosmetic result E/G/P	follow-up (months)
1	26	M	RTA	E4V5M6 (15/15)	76	Left F	Dural tear	No	150	5	E	6
2	42	M	RTA	E1V2M5 (8/15)	90	RT P	Contusion	No	200	4	E	5
3	28	M	ASSAULT	E3V3M5 (11/15)	60	F	EDH, SSS injury	Yes	160	5	E	5
4	61	M	ASSAULT	E3V3M5 (11/15)	78	Left P	Contusion	No	130	5	E	3
5	36	M	RTA	E4V5M6 (15/15)	74	Left T-P	Dural tear and contusion	NO	140	5	E	2
6	28	M	RTA	E4V5M6 (15/15)	60	F	Dural INJ., contusion	No	150	5	E	2
7	30	M	RTA	E4V4M6 (14/15)	44	F	EDH, SSS injury	No	160	5	E	2
8	22	M	RTA	E4V4M6 (14/15)	80	Right F	Contusion	Yes	170	5	E	2
9	29	M	RTA	E4V3M5 (12/15)	16	Right F	Contusion	Yes	130	5	G	2
10	25	M	RTA	E1VTM2 (4/15)	60	Convexo-basal distraction	Dural tear, basi-frontal contusion, DCE	No	240	1	–	–
11	32	M	RTA	E4V5M6 (15/15)	46	LEFT P	Dural tear	No	160	5	E	2

MOI- Mechanism of injury, GCS- Glasgow Coma Scale at admission, F-Frontal, T-Temporal, P-Parietal, E– Excellent, G- Good, P-poor, EDH- Epi-Dural Hematoma, SSS- Superior Saggital Sinus.

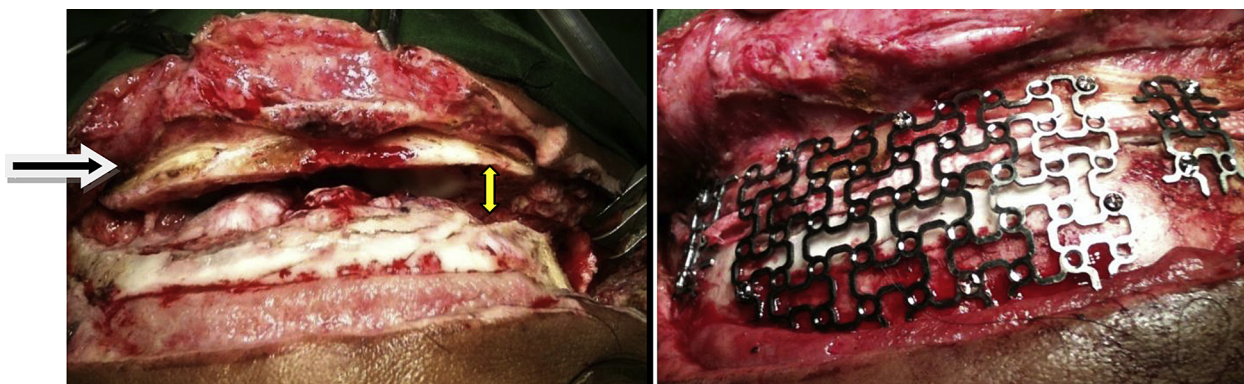


Fig. 4 – Case 10. Intra-Operative photo. First figure showing distraction of the cranial convexity from the anterior cranial fossa (→). With the yellow line showing the separation. Second figure showing re-approximation using mesh and miniscrews.

Associated underlying injury was found in all the case, ranging from dura tear in 5 cases, contusions in 7 cases, Superior sagittal sinus injury with Epi-Dural Hematoma in 2 cases, and bone fragment deep in the brain parenchyma in 1 case. This patient had multiple episodes of Generalized Tonic-Clonic convulsions prior to surgery. The distribution of location of fractures was that Frontal was the most common site (5 cases), followed by parietal (3 cases), and temporal and temporo-parietal had one case each, there was one rare and devastating injury of distraction of cranial convexity from anterior cranial fossa, which we have named ‘Convexo-basal Distraction’ as no name exists for such a fracture (Fig 4). Opening of air sinuses was found in 3 patients.

The mean interval between injury and surgery was 62.2 ± 21 h, this delayed presentation was due to delay in primary consultation, delayed referral, delayed transportation mostly because of financial constraints of patients being referred from rural centers. The mean duration of surgery was 162.7 ± 32.3 min. Of the eleven patients 9 had a Glasgow outcome Score (GOS)⁵ of 5 (Good recovery at discharge), 1 had moderate disability (GOS 4, Case no 2, had residual left hemiparesis after a right parietal contusion), one patient expired (case no 10) in post-operative day 7, resulting from sepsis and multi-organ failure, but in this patient there was no wound infection (Fig 6).

In the immediate post-operative period amongst the surviving patients none of the patients had post-operative fever. No patient had peri-wound edema or heat in peri-wound area.

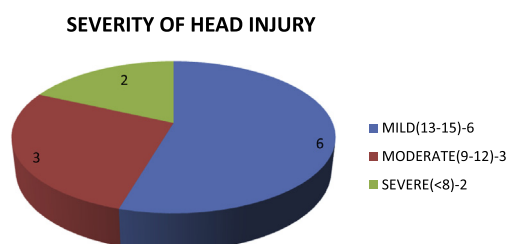


Fig. 5 – Pie-chart showing the severity of head injury. Classified as mild if GCS 13-15, moderate if GCS 9-12 and severe if GCS <8.

Alternate day total leukocyte count were normal in all cases except case no 10 (Table 1) who had increased TLC and later landed in sepsis and multi-organ failure. All the surviving patients are under monthly follow-up for first 6 months and then planned annual follow-up. Mean follow-up is 2.81 months and no complications could be observed within this period. The patients remained between 5 and 16 days at our institution. Radiologic follow up revealed no signs of infections, and appropriate post-operative changes at surgical site (Fig. 2).

5. Discussion

The standard approach towards compound skull fractures of removal of bone followed by re-construction in a second stage has given way to a single staged procedure of debridement and repair in one go. This practice of single staged procedure is only restricted to patients with early presentation,^{3,4} in this study the mean interval between injury and operation was 62 h, yet there were no detrimental outcomes in relation to wound infections in this group of patients.

The major clinical concern for early single stage cranioplasty is infection: wound infection, brain abscess, meningitis and osteomyelitis. Most of the studies used to argue against early repair are based on combat-related injuries, which differ significantly from those in a civilian population.⁶ Jennet and Miller have discussed that this military experience cannot be transposed to the civilian scene in their study based on 359 non-missile compound depressed fractures⁷ and they have further detailed that retaining fragments of bone helps prevent a second operation of cranioplasty and the rate of infection is not significantly higher by such retention.

The treatment of cranial defects has always been a fascinating and controversial topic for craniofacial surgeons.⁸ The consensus on implant material is yet to be achieved, as the search for the ideal implant material is a never ending process. Early reconstruction with a cranioplasty material such as titanium have found their roots in excellent reports emerging from the knowhow of titanium application in craniofacial surgery with long standing experience in early single stage

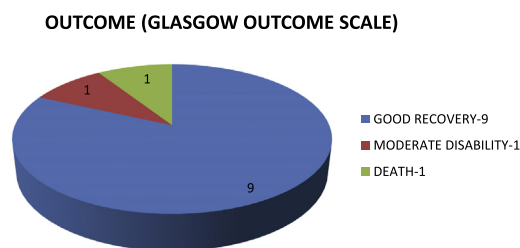


Fig. 6 – Pie-chart showing the patient outcome in terms of Glasgow Outcome Scale.

reconstruction for open craniofacial wounds by using various titanium devices.⁹ Similarly, the titanium micro-mesh system was used by Kuttenger et al., for immediate reconstruction with bone loss in non load bearing areas and for treatment of contour irregularities.¹⁰ In our study we have used standard profile mesh, which can provide strength even in load bearing areas.

The immediate cranioplasty gives immediate protection to the underlying brain, in addition to providing cosmesis. It is important that the psychosocial aspects and the feeling of protection against trauma should not be overlooked.¹¹ The skin flap syndrome or post trephination syndrome has been greatly discussed by various authors. Although the exact cause is uncertain, it may be a result of barometric pressure changes transmitted intra-cranially.¹²

The conventional methods of stabilizing bone fragments include threads, wires and plates. Titanium has also served this role both as a stabilizing system when used as miniplates⁴ and as a substitute to bone when titanium mesh is used to fill the defect.^{4,10} But the use of both bone fragments and mesh as has been done in our study is a new technique and this solves a multitude of functions.

6. Conclusion

Primary reconstruction of compound fractures should be attempted in all possible case, even in ones with delayed presentation, in our series the mean interval between the injury and the surgery is 62.2 ± 21 h. When this primary reconstruction is done with native bone fragments and titanium mesh system is an innovative step to achieve several results. It serves all the functions provided by a single-stage cranioplasty including cosmesis, protection, and prevention of skin flap syndrome. What edge it provides over conventional methods is that it helps maintain the contour of the

defect better than any other method. Using bone, which belongs to that site and the remainder of the defect being covered by the mesh serves this purpose. This Bone-Mesh Unit provides excellent cosmetic results. The strength provided by this construct is better than use of mini-plates or wires and also low-profile mesh systems alone. Although the rate of infection has been nil in our series, a larger series with longer follow-up is warranted before introducing into clinical practice.

Conflicts of interest

All authors have none to declare.

REFERENCES

1. Rifkinson-Mann S. Cranial surgery in ancient Peru. *Neurosurgery*. 1988;23:411–416.
2. Kalyanaraman S, Ramamurthi B. An analysis of 3000 cases of head injury. In: *Paper Presented at the Fifth Asian Federation Congress of the International College of Surgeons*. 1973.
3. Marbacher Serge, Andres Robert H, Fathi Ali-Reza, Fandino Javier. Primary reconstruction of open depressed skull fractures with titanium mesh. Online publication date *J Craniofacial Surg*. 1st March 2008;19:490–495.
4. Nayak PK, Mahapatra AK. Primary reconstruction of depressed skull fracture- the changing scenario. *Indian J Neurotrauma (IJNT)*. 2007;5:35–38.
5. Jennett B, Bond MR. Assessment of outcome after severe brain damage – a practical scale. *Lancet*. 1975;1:480–484.
6. Allen IV, Scott R, Tanner JA. Experimental high-velocity missile head injury. *Injury*. 1982;14:183–193.
7. Jennett B, Miller JD. Infection after depressed fracture of skull. Implications for management of nonmissile injuries. *J Neurosurg*. 1972;36:333–339.
8. Mottaran R, Guarda-Nardini L, Fusetti S, et al. Reconstruction of a large post-traumatic cranial defect with a customized titanium plaque. *Neurosurg Sci*. 2004;48:143–147.
9. Stoll P, Schilli W. Primary reconstruction with AO-miniplates after severe cranio-maxillofacial trauma. *J Craniomaxillofac Surg*. 1988;16:18–21.
10. Kuttenger JJ, Hardt N. Long term results following reconstruction of craniofacial defects with micro-mesh systems. *J Cranio-Maxillofacial Surg*; 29: 75–81.
11. Dujovny M, Aviles A, Agner C, et al. Cranioplasty: cosmetic or therapeutic? *Sur Neurol*. 1997;47:238–241.
12. Dujovny M, Fernandez P, Alperin N, et al. Post-cranioplasty cerebro-spinal fluid hemodynamic changes: magnetic resonance imaging quantitative analysis. *Neurol Res*. 1997;19:311–316.