Available online at www.sciencedirect.com

ScienceDirect

journal homepage: www.elsevier.com/locate/ijnt

Case Report

Autologous bone marrow derived stem cell therapy in traumatic spinal cord injury: A case report and review of literature

Pradipta Tripathy [a,*], *Chidananda Dash* [b], *Aurobind Rath* [c], *S. Chakraborty* [d], *Jagannath Sahoo* [e], *Sureswar Mohanty* [f]

[a] *Professor, Department of Neurosurgery, Institute of Medical Science (IMS) & SUM Hospital, Bhubaneswar, Odisha 751003, India*
[b] *Senior Scientist, Research Lab, Institute of Medical Science (IMS) & SUM Hospital, Bhubaneswar, Odisha 751003, India*
[c] *Assistant Professor, Department of Physiotherapy, Institute of Medical Science (IMS) & SUM Hospital, Bhubaneswar, Odisha 751003, India*
[d] *Professor & Head, Department of Hematology, Institute of Medical Science (IMS) & SUM Hospital, Bhubaneswar, Odisha 751003, India*
[e] *Professor & Head, Department of Orthopedic, Institute of Medical Science (IMS) & SUM Hospital, Bhubaneswar, Odisha 751003, India*
[f] *Professor & Head, Department of Neurosurgery, Institute of Medical Science (IMS) & SUM Hospital, Bhubaneswar, Odisha 751003, India*

ARTICLE INFO

Article history:
Received 12 May 2014
Accepted 21 November 2014
Available online 9 December 2014

Keywords:
Traumatic
Spinal cord injury
Autologous bone marrow
Stem cell therapy

ABSTRACT

Spinal cord injury (SCI) is a devastating condition. It not only creates enormous physical and emotional cost to the victims but also causes a financial burden to the society at large. The treatment of SCI focuses on preventing further injury and enabling people to return to an active and productive life within limits of their disability. Recently there is great excitement about the possibility of generating neural progenitor cells from sources such as mesenchymal cells derived from skin, bone-marrow, or adipose tissue. Stem cell therapy in traumatic spinal cord injury is an on going area of research in many centres in India and abroad. We describe a case of traumatic spinal cord injury with complete paraplegia in an adult where we had infused autologous bone marrow derived stem cell to damaged cord during fixation procedure and review the literature.

Copyright © 2014, Neurotrauma Society of India. All rights reserved.

* *Corresponding author*. Consultant Neurosurgeon, Ayush Hospital, Acharya Vihar Square, Bhubaneswar, Odisha 751022, India. Tel.: +91 (0) 674 7111100x808 (office), +91 (0) 9439831761 (mobile); fax: +91 674 2545003.
E-mail address: pradipta_tripathy@yahoo.com (P. Tripathy).
http://dx.doi.org/10.1016/j.ijnt.2014.11.009
0973-0508/Copyright © 2014, Neurotrauma Society of India. All rights reserved.

This document was downloaded for personal use only. Unauthorized distribution is strictly prohibited.

1. Introduction

Stem cell therapy is used currently as a novel strategy to overcome physical discontinuity and support axonal growth in experimental models of spinal cord injury.[1,2] The multifarious potential of cellular therapy support restoration of axonal connections, limits tissue damage and scarring, facilitates remyelination repair, and replaces and re-establishes lost neural tissue and its circuitry.[3] Autologous stem cells, that are safe and efficient, possess such potentials as to be considered an attractive alternative therapeutic regimen for regeneration of damaged axons and neurons following spinal cord injury. They also obviate the therapeutic bane of immune-suppression and adverse reactions, serve as a better option of therapy for injured spinal cord.[4] We report our case of traumatic spinal cord injury leading to complete paraplegia in an adult where we have infused autologous bone marrow derived stem cells into the damaged cord during spinal stabilization procedure and review the literature.

2. Case report

A 30 year old male was admitted to our institution with history of fall from a 20 feet height. He was a manual labourer by profession, working at a height of 20 feet, due to imbalance he fell to ground hitting his back. On examination he had grade-o power in both lower limb, sensory level at L1 and retention of urine. His neurological status was, ASIA (American Spinal Injury Association) Grade-A. Injection methylprednisolone was given according to National Acute Spinal Cord Injury Study (NASCIS) – 2 regimen as he came within 3 h of injury and he was catheterized. His X-ray lumbar spine revealed L1 burst fracture (Fig. 1A). Magnetic resonance imaging (MRI) of spine revealed burst fracture of L1 body and mild compression fracture of L2 with retropulsion of fracture fragment of L1 causing significant cord compression with cord oedema (Fig. 1B,C,D). Patient was planned for stabilization procedure. We also planned for stem cell therapy for this patient in the same sitting. First we took the permission from the ethical committee of the institute for this novel procedure. Then we informed the patient party about this new procedure and its pros and cons in detail. Once got the consent from the patient party, we informed the haematologist and the research officer in our institute to prepare the bone marrow derived stem cells for the patient. The haematologist aspirated the bone marrow from the iliac crest of the patient and the research officer collected the aspirated bone marrow in a heparinised bottle diluted in Dulbecco's phosphate buffered saline and transferred it to the lab for further processing.

3. Stem cell preparation

3.1. *Isolation and processing of human-bone-marrow–derived mononuclear cells*

One hundred to 120 mL of bone marrow was aspirated from the iliac crest of the patient in a heparinized (1 L/5000 U) bottle and diluted in Dulbecco's phosphate buffered saline (without calcium and magnesium) at a ratio of 1:2. The aspiration was layered on Ficoll (Ficoll–Paque PLUS, 1.077 g/L, Stem Cell technologies, Vancouver, BC, Canada V5Z 1B3), and centrifuged at 450*g* for 30 min. The mononuclear cell interface was carefully removed, and washed twice in Dulbecco's phosphate buffered saline at 400*g* for 10 min. The resultant pellet was added with RBC lysing solution (0.7% ammonium chloride) and incubated for 2 min. The lysing was arrested by adding 0.9%ice cold sodium chloride, and the cells were washed. The bone marrow derived cells were washed in Dulbecco's phosphate buffered saline until the lysing factors were removed, and finally, resuspended in required volume.

3.2. *FACS characterization of bone marrow derived cells*

One hundred microliter processed samples (1 × 106 cells/mL), 20 μL of CD34, and 20 μL of CD45 antibodies conjugated with phycoerythrin (PE) and fluorescein isothiocyanate (FITC) respectively (BD Biosciences, San Jose, CA, USA) were added and incubated for 15 min at room temperature in the dark. After incubation, 900 μL of phosphate buffered saline was added to the stained cells and mixed well. To this mixture, 5 μL of the 7-Amino Actinomycin D(7-AAD) dye was added, and

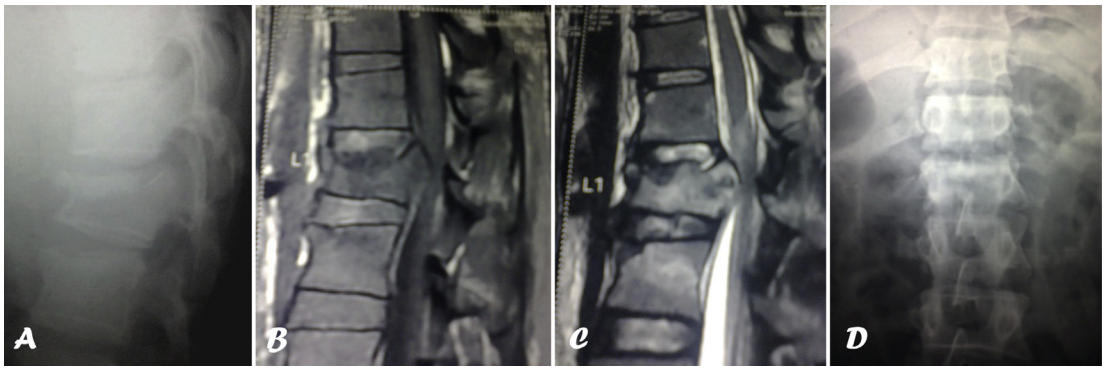

Fig. 1 – (A) plain X-ray lumbar spine lateral view showing burst fracture of L1 vertebra, MRI of LS spine, sagittal cuts T1 weighted image (B),T2 weighted image (C) and coronal cuts (D) showing burst fracture of L1 with retropulsion of fracture fragment causing compression of spinal cord and cord oedema.

This document was downloaded for personal use only. Unauthorized distribution is strictly prohibited.

again incubated in dark for 10 min at room temperature. The cells were vortexed and aliquoted for characterization in FACS area (BD). One lakh event was acquired for analysis of the cellular composition of the sample. The total viability was assessed by 7-AAD method.

3.3. *Pyrogen testing by limulus amebocyte lysate method*

To a 100-μL processed sample, 100 μL limulus amebocyte lysate reagent (Endotoxin Test Kit, Cambrex Walkersville, MD, USA) was added, and incubated for 1 h at 37 °C. Clotting of the sample was considered as positive indication for pyrogens at 0.06 EU/mL. All samples negative for this test and thus ready for infusion to the patients.

4. Treatment

Once the mononuclear stem cells were ready, the patient was posted for surgery. The surgery was done on 8th day of trauma. Transpedicular fixation of the spine from T12 to L3, and L1 laminectomy was conducted. (Fig. 2A and 2B). 2 ml sample containing 10^{6-7} cultured stem cells in each μL were taken in a 2.5 ml syringe with a 26 gaze needle, infused into the subarachnoid space at the lower border of L1 vertebral body level just below the damaged cord which represents the conus level under C-Arm guidance (Fig. 2C). Wound closed in layers. There were no adverse reactions noted in the post operative period. Patient was given physiotherapy and neurologically assessed daily for any improvement. At discharge on Day 14, neurologic assessment revealed Grade 2 power in the lower limbs (active joint movement with gravity eliminated). On subsequent follow up after 3 months his power was grade-3 and he was walking with knee ankle foot orthotic (KAFO) and walker support (Fig. 2D).

Fig. 2 – Post operative X-ray in Lateral (A) and A.P(B) view showing the screws in T12 and L3 body and the rods, intra-operative picture (C) showing the stem cell infusion to cord substance and picture of the patient on 3 months follow up (D) showing the patient walking with KAFO device and walker support.

5. Discussion

Spinal cord injury resulting from various aetiology leading to devastating neurological deficits still remains a challenge to treat for the neuro physicians and surgeons. Though various options of treatment like use of high dose of methyl prednisolone and early surgical decompression is being practiced routinely, which has reported good neurological outcome in traumatic spinal cord injury, it is not same in all cases. The results vary depending on age of patient, type and severity of injury, the time gap between institution of methyl prednisolone infusion/surgical decompression and associated co-morbidity. Stem cell therapy derived from autologous bone marrow is an ongoing area of research in may centres in India and abroad.

Reparative strategies for spinal cord traumatic injuries involve cellular replacement, tropic, and a substrate support. Loss of cellular components and de-myelination that occurs as a post injury inflammatory process hampers the functional recovery, and adds to regenerative complexity of spinal cord.[1] Reducing progressive tissue damage and scarring, facilitation of remyelination, and re-establishment of lost neural tissue and its circuitry, is the aim of stem cell therapy.[2–4]

Bone marrow derived mononuclear cellular (BMDC) therapy for acute spinal cord injury has proven as effective in experimental animal cases. Deng YB et al reported that transplantation of mesenchymal stem cells (MSC) in rodent models has proved to be an effective therapeutic approach for spinal cord injury (SCI).[5] Several preliminary attempts were made to use autologous BMDC in human clinical trials with much emphasis on safety.[6] It was observed that the neurons regenerated from adult BMDC was shown to exhibit the same morphologic and functional characteristics as neurons derived from adult brain stem/progenitor cells, and both had similar electrophysiologic response.[7] In our study, we also documented progressive neurological recovery in motor power of the patient from 14 to 90 days post surgery and stem cell therapy.

Clinical trials using autologous BMDC on spinal-cord–related ailments, or injuries such as amyotrophic lateral sclerosis, multiple sclerosis, or traumatic spinal cord injury were being conducted elsewhere, with limited sampling size.[8–10] Except for minor tingling sensations, no allergic or inflammatory reactions, or any major adverse reactions so far have been reported with the use of autologous BMDC for spinal cord injuries. Fever and headache usually manifest in the first week after the therapy, and then become normal with medications. Neuropathic sensory symptoms developed a 2 weeks after the therapy, and also could be resolved with medications.[11,12] In our case no fever or neuropathic pain was

This document was downloaded for personal use only. Unauthorized distribution is strictly prohibited.

observed. Further, it could be observed that the recovery of sensation was not universal; that it might or might not precede the motor control (including the bladder control) in a complete spinal cord injury (ASIA A), and the partial impairment (ASIA B/C) often leading to both sensory and motor improvement. This dichotomy in the in vivo development could not be explained.[13] In our case patient had both motor and sensory improvement on follow up at 3 months.

Most of the study mentioned that the results of stem cell therapy in chronic spinal cord injury has been very encouraging, where the initial results following use of methyl prednisolone and surgical decompression has been dismal. It has also been documented that the neurological outcome of stem cell therapy in traumatic cervical spine injury is poorer than in lower thoracic and lumbar spinal injury.[14] In various series it has been documented the positive neurological outcome following bone marrow derived stem cell therapy within 3 months. It has also been documented that the results are better if given early during surgical decompression and fixation procedure in comparison to those given following 3 months of trauma and surgical intervention.[12,14]

To conclude autologous bone marrow derived mononuclear cellular therapy is simple, safe and cost effective for acute spinal cord injury. BMDC Infusion into the subarachnoid space below the level of damaged cord following laminectomy and spinal fixation is a minimally invasive method of cellular delivery in acute spinal cord injury without adverse reaction. Functional outcome in traumatic spinal cord injury following stem cell therapy in our case had a positive neurological outcome, it will be too early to authenticate that it is due to stem cell therapy only for which further large series study is required.

Conflicts of interest

All authors have none to declare.

REFERENCES

1. Barnabe-Heider F, Frisen J. Stem cells for spinal cord repair. *Cell Stem Cell*. 2008;3:16–24.
2. Parr AM, Tator CH, Keating A. Bone marrow-derived mesenchymal stromal cells for the repair of central nervous system injury. *Bone Marrow Transplant*. 2007;40:609–619.
3. Alexanian AR, Maiman DJ, Kurpad SN, Gennarelli TA. In vitro and in vivo characterization of neurally modified mesenchymal stem cells induced by epigenetic modifiers and neural stem cell environment. *Stem Cells Dev*. 2008;17:1123–1130.
4. Callera F, do Nascimento RX. Delivery of autologous bone marrow precursor cells into the spinal cord via lumbar puncture technique in patients with spinal cord injury: a preliminary safety study. *Exp Hematol*. 2006;34:130–131.
5. Deng YB, Liu XG, Liu ZG, Liu XL, Liu Y, Zhou GQ. Implantation of BM mesenchymal stem cells into injured spinal cord elicits de novo neurogenesis and functional recovery: evidence from a study in rhesus monkeys. *Cytotherapy*. 2006;8:210–214.
6. Rolls A, Shechter R, Schwartz M. The bright side of the glial scar in CNS repair. *Nat Rev Neurosci*. 2009;10:235–241.
7. Moviglia GA, Varela G, Gaeta CA, Brizuela JA, Bastos F, Saslavsky J. Autoreactive T cells induce in vitro BM mesenchymal stem cell transdifferentiation to neural stem cells. *Cytotherapy*. 2006;8:196–201.
8. Samijn JP, te Boekhorst PA, Mondria T, et al. Intense T cell depletion followed by autologous bone marrow transplantation for severe multiple sclerosis. *J Neurol Neurosurg Psychiatr*. 2006;77:46–50.
9. Cristante AF, Barros-Filho TE, Tatsui N, et al. Stem cells in the treatment of chronic spinal cord injury: evaluation of somatosensitive evoked potentials in 39 patients. *Spinal Cord*. 2009;31.
10. Deda H, Inci MC, Kurekci AE, et al. Treatment of amyotrophic lateral sclerosis patients by autologous bone marrow-derived hematopoietic stem cell transplantation: a 1-year follow-up. *Cytotherapy*. 2009;11:18–25.
11. Chernykh ER, Stupak VV, Muradov GM, et al. Application of autologous bone marrow stem cells in the therapy of spinal cord injury patients. *Bull Exp Biol Med*. 2007;143:543–547.
12. Moviglia GA, Varela G, Brizuela JA, et al. Case report on the clinical results of a combined cellular therapy for chronic spinal cord injured patients. *Spinal Cord*. 2009;47:499–503.
13. Song S, Song S, Zhang H, Cuevas J, Sanchez-Ramos J. Comparison of neuron like cells derived from bone marrow stem cells to those differentiated from adult brain neural stem cells. *Stem Cells Dev*. 2007;16:747–756.
14. Kumar Arachimani Anand, Kumar Sankaran Raj, Narayanan Raghavachary, Arul Kanagarajan, Baskaran Mayakesavan. Autologous bone marrow derived mononuclear cell therapy for spinal cord injury: a phase I/II clinical safety and primary efficacy data. *Exp Clin Transplant*. 2009;4:241–248.

This document was downloaded for personal use only. Unauthorized distribution is strictly prohibited.