



# Journal of Coloproctology

www.jcol.org.br



## Original Article

# Surgical complications and metachronous rectal cancer risk in patients with classic familial adenomatous polyposis



Paulo Roberto Stevanato Filho\*, Samuel Aguiar Jr., Fábio O. Ferreira, Wilson T. Nakagawa, Ranyell M. Spencer, Renata M. Takahashi, Tiago S. Bezerra, Ademar Lopes

Colorectal Tumor Nucleus, Pelvic Surgery Department, A. C. Camargo Cancer Center, São Paulo, SP, Brazil

## ARTICLE INFO

### Article history:

Received 28 October 2014

Accepted 15 November 2014

Available online 28 January 2015

### Keywords:

Familial adenomatous polyposis

Colorectal cancer

Total colectomy

Adenomatous polyps

Restorative proctocolectomy

## ABSTRACT

**Introduction:** Familial adenomatous polyposis (FAP), an autosomal dominant disease characterized by development of numerous adenomatous polyps in the colon and rectum, is caused by germline mutations in the *Adenomatous Polyposis Coli* (APC) gene.

**Methods:** To determine the surgical morbidity in patients with classical familial adenomatous polyposis and determine the incidence of metachronous colorectal cancer (CRC) in those undergoing total colectomy (TC) with ileorectal anastomosis or restorative total proctocolectomy (TPC) and ileal pouch anal anastomosis. We analyzed patients with familial adenomatous polyposis who received treatment and regular follow-up at the A.C. Camargo Cancer Center from 1994 to 2013.

**Results:** Operative complications occurred in 22 patients (34.3%), 16 (25%) being early complications and 8 (12.5%) late complications. No mortality occurred as a result of postoperative complications. The incidence of metachronous rectal cancer after total proctocolectomy was 2.3% and after total colectomy 18.18% ( $p=0.044$ ).

**Conclusions:** In order to provide better quality of life for individuals with familial adenomatous polyposis, total colectomy is commonly offered, as this simple technique is traditionally associated with lower rates of postoperative complications and better functional outcomes. However, it has become a less attractive technique in patients with familial adenomatous polyposis in its classical or diffuse form, since it has a significantly higher probability of metachronous rectal cancer.

© 2015 Sociedade Brasileira de Coloproctologia. Published by Elsevier Editora Ltda. All rights reserved.

\* Corresponding author.

E-mail: paulorstevanato@gmail.com (P.R. Stevanato Filho).  
<http://dx.doi.org/10.1016/j.jcol.2015.01.006>

2237-9363/© 2015 Sociedade Brasileira de Coloproctologia. Published by Elsevier Editora Ltda. All rights reserved.

## Complicações cirúrgicas e risco de câncer retal metacrônico em pacientes com polipose adenomatosa familiar clássica

### R E S U M O

#### Palavras chave:

Polipose adenomatosa familiar  
Câncer colorretal  
Colectomia total  
Pólipos adenomatosos  
Proctocolectomia restaurativa

**Introdução:** Polipose adenomatosa familiar (PAF), uma doença autossômica dominante caracterizada pela formação de numerosos pólipos adenomatosos no cólon e reto, é causada por mutações da linha germinativa no gene da polipose adenomatosa do cólon (PAC).

**Métodos:** Para determinar a morbidade cirúrgica em pacientes com PAF clássica e determinar a incidência de câncer colorretal (CCR) metacrônico naqueles pacientes submetidos a colectomia total (CT) com anastomose íleo-retal ou submetidos à proctocolectomia restaurativa (PCT) e anastomose bolsa ileal-anal, foram analisados pacientes com PAF que foram tratados e tiveram acompanhamento periódico no A. C. Camargo Cancer Center de 1994 até 2013.

**Resultados:** Ocorreram complicações cirúrgicas em 22 pacientes (34,3%); 16 (25%) tiveram complicações precoces e 8 (12,5%) complicações tardias. Não houve mortes como resultado de complicações pós-operatórias. A incidência de câncer de reto metacrônico após PCT foi de 2,3% e após CT foi de 18,18% ( $p = 0,044$ ).

**Conclusões:** A fim de proporcionar melhor qualidade de vida para os pacientes com PAF, CT é comumente oferecida, pois esta técnica simples está tradicionalmente associada com menores percentuais de complicações pós-operatórias e melhores resultados funcionais. No entanto, CT se tornou uma técnica menos atraente em pacientes com PAF em sua forma clássica ou difusa, uma vez que traz consigo uma probabilidade significativamente maior de câncer retal metacrônico.

© 2015 Sociedade Brasileira de Coloproctologia. Publicado por Elsevier Editora Ltda. Todos os direitos reservados.

## Introduction

Familial adenomatous polyposis (FAP), an autosomal dominant disease characterized by the development of hundreds to thousands of adenomatous polyps in the colon and rectum, is caused by germline mutations in the *Adenomatous Polyposis Coli* (APC) gene, which is in chromosomal region 5q21-22.<sup>1,2</sup> This mutation is present in 1 in 10,000 live births, and accounts for 1% of the cases of colorectal cancer (CRC).<sup>3</sup>

In classical polyposis polyps, mainly in the distal colon (rectosigmoid), often develop during childhood and increase in size and number in adolescence, when they characteristically develop throughout the colon. Half of these patients develop adenomas by the age of 15 years and 95% by the age of 35.<sup>1</sup> Genomic penetrance is approximately 100%. The median age of diagnosis of CRC is 39 years; however, 7% of patients develop CRC before the age of 21.

Essential steps in the management of patients with FAP include early diagnosis of affected individuals, performance of prophylactic colectomy when appropriate, genetic counseling, recognition of various extracolonic manifestations and adequate postoperative follow-up.<sup>1</sup>

Surgery is the most effective means of preventing CRC, mainly in the form of total colectomy with ileorectal anastomosis (IRA) or total proctocolectomy (TPC) followed by ileal pouch and ileoanal anastomosis.<sup>4</sup> Preservation of the rectum is associated with better functional outcomes and less morbidity, but carries a risk of metachronous tumor in the stump remnant.<sup>5,6</sup> Decisions concerning the best procedure for each patient should be based on factors such as age, location and

number of polyps, location of genetic mutation and patient acceptance of undergoing regular postoperative follow-up.

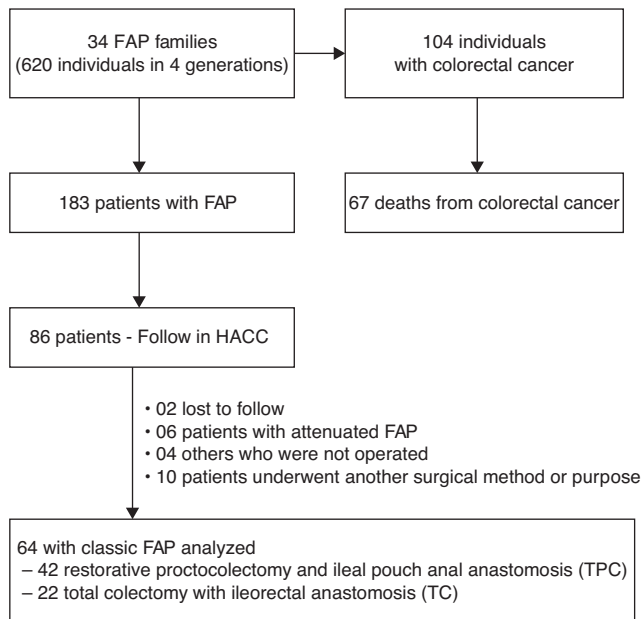
Until 1980, prophylactic restorative proctocolectomy and ileal pouch anal anastomosis was the procedure of choice for the treatment of FAP. Thereafter, TPC followed by ileal pouch and ileoanal anastomosis became the gold standard for treatment of the classic or diffuse form of this disease.<sup>3</sup>

Our objectives were to assess surgical morbidity in patients with classical FAP and ascertain the risk of metachronous CRC in the anorectal region in patients who had undergone TC with IRA or TPC with ileal pouch, these being the most commonly performed procedures in most institutions.

## Patients and methods

Relevant data of patients with FAP who were added to the hereditary CRC registry of the A.C. Camargo Cancer Center (HACC) from 1994 to 2013 were retrospectively analyzed. The diagnoses of FAP had been established by clinical history and colonoscopy with histological analysis of some resected polyps.

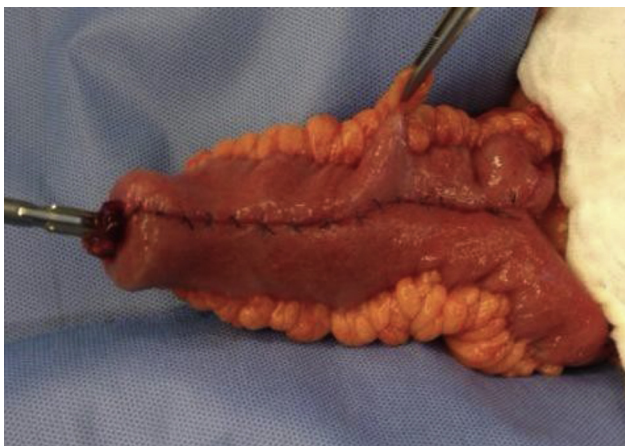The study analyzed 86 patients (from 34 families) with FAP who had received genetic counseling and regular follow-up treatment. Eighty-two of these patients underwent surgical treatment. Studied variables were epidemiological and surgical procedure was performed. The aim being to ascertain the incidence of metachronous rectal cancer after TC or TPC, ten patients who had undergone noncurative surgical treatments or procedures other than TC and TPC were excluded,



**Fig. 1 – Selection of patients for the study.**

as were six with attenuated FAP and four others who refused to undergo preventive surgical treatment. Of the remaining 64 patients, 42 underwent TPC and 22 TC (Fig. 1).

For TC, approximately 15 cm of rectum was preserved, followed by performing primary IRA end-to-end with a 29 mm circular stapler. TPC consisted of resection of the colon and rectum, followed by reconstruction of a means of intestinal transit with a mechanical bowel anastomosis by a double stapling technique involving fashioning an 15 cm ileal J-pouch using two staplings of 75 mm and anastomosing this pouch to the anal canal with a 29 mm circular stapler. In these, protective ileostomy was performed and also routine drainage (Fig. 2).



**Fig. 2 – Ileal J-pouch with 15 cm extension, fashioned with mechanical sutures and placement of the pointed arch of the stapler for ileoanal anastomosis (pouch-anus) by a double stapling technique. Restorative proctocolectomy and ileal pouch anal anastomosis in patients with Familial adenomatous polyposis are shown.**

The follow-up routine of patients with colorectal tumors treated at the institution included a clinical visit every three months during the first two years that included laboratory tests, tumor marker evaluation, chest X-ray and abdominal ultrasound or cross-sectional imaging (tomography), alternately. From the third to the fifth year, this routine examination was performed every six months, after which it was conducted annually. Proctosigmoidoscopy was repeated annually in FAP patients who underwent surgery. When recurrence was detected, tests were requested for re-staging and therapeutic planning purposes. Positron emission tomography-computed tomography (PET-CT) was requested in cases where the risk of metastases was deemed higher.

Correlation coefficients between all findings were estimated using Pearson correlation. Either the  $\chi^2$  test or Fisher's exact test (two sided) was performed to determine the correlation between all groups. Results were considered statistically significant at  $p < 0.05$ . All statistical analyses were conducted using the SPSS 20.0 statistical software program (SPSS, Chicago, IL).

## Results

During the study period, 34 families consisting of 620 individuals over four generations were identified as having FAP. Of these, 183 subjects (29.5%) were identified as having intestinal polyps, 104 (56.8%) had CRC and of these, 67 (64.42%) progressed to death (Fig. 1). The median age of diagnosis of CRC was 36 years and the prevalence of CRC did not differ significantly according to sex (30.6% and 26.2% in male and female subjects, respectively;  $p = 0.64$ ).

The targets of this study, 64 family members of patients with classic FAP (>100 polyps), were followed up regularly at our institution. The mean duration of follow-up was 13-231 months (median 90 months). The median age of diagnosis of FAP was 30 (13-45) years. Of these individuals, 42 underwent TPC and 22 TC. Table 1 shows the incidence of early and late postoperative complications for each procedure. Operative complications occurred in 22 patients (34.3%), 16 (25%) being early complications (up till the 30th postoperative day) and 8 (12.5%) late complications. No mortality occurred as a result of postoperative complications.

Overall, significantly more complications occurred in the TPC (42.8%) than in the TC group (18.18%) ( $p = 0.048$ ).

Anastomotic leakage was the commonest early complication and subocclusion or bowel obstruction the commonest late complication. Most patients who developed anastomotic leakage (six TPC and two TC) were treated conservatively: in only one case was a new surgical intervention, fashioning of a permanent ileostomy, necessary. Among patients who developed obstruction, five underwent laparotomy with lysis of adhesions and/or enterectomy. One patient developed necrosis of the ileal reservoir and subsequently underwent a further surgical intervention to fashion a permanent stoma.

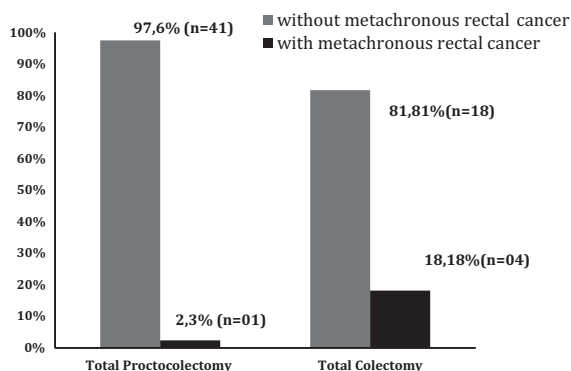
The incidence of metachronous rectal cancer after TPC was 2.3% and after TC 18.18% (in the rectal remnant;  $p = 0.025$ ; Fig. 3).

**Table 1 – Early and late postoperative surgical complications.**

	Restorative proctocolectomy and ileal pouch anal anastomosis (TPC 42)	Total colectomy (TC 22)	Total (%)
<i>Early complications</i>			
Postoperative infections/leakage	3	1	4
Anastomotic leakage	6	2	8
Bowel obstruction	1	1	2
Bleeding	1	–	1
Pouch necrosis	1	–	1
Subtotal (n complications)	12 (28.57%)	4 (18.18%)	16 (25%)
<i>Late complications</i>			
Subocclusion/bowel obstruction	4	1	5
Urinary incontinence	1	–	1
Stenosis anastomosis	1	–	1
Electrolyte imbalance	1	–	1
Subtotal (n complications)	7 (16.6%)	1 (4.5%)	8 (12.5%)
Total cases/complications (% individuals)	18/19 (42.8%)	4/5 (18.18%)	22/24 (34.3%)

**Table 2 – Characteristics of patients with metachronous rectal lesions according to type of surgery and requirement for surgical salvage.**

Surgery type	Age	Disease free survival	Staging	Treatment recurrence
Proctocolectomy and ileal pouch anal anastomosis	51 years	10 years	T1N0M0	Local resection
Total colectomy with ileorectal anastomosis	46 years	3 years	T1N0M0	Complete proctectomy and ileal pouch anal anastomosis
Total colectomy with ileorectal anastomosis	55 years	5 months	T1N0M0	Complete proctectomy and ileal pouch anal anastomosis
Total colectomy with ileorectal anastomosis	50 years	7 years	T2N0M0	Abdominoperineal amputation
Total colectomy with ileorectal anastomosis	33 years	2 years	T1N0M0	Complete proctectomy and ileal pouch anal anastomosis



**Fig. 3 – Metachronous rectal cancer in patients with FAP according to type of surgery. X<sup>2</sup> test (n = 64); p = 0.044.**

Most of the metachronous rectal cancers that developed after TC (n=22) did so within the first 10 years of follow-up (n=4). All the patients who had undergone TC and not developed neoplastic lesions (n = 18) had been followed up for more than 5 years. The only metachronous CRC that developed after TPC was diagnosed after 10 years of follow-up; local resection was performed. Some patients who had undergone TC with preservation of the rectum subsequently were required to have residual rectal resection or abdominoperineal amputation because of invasive adenocarcinoma near the dentate line and/or uncontrollable numbers of polyps (Table 2).

## Discussion

Compared with TPC, the procedure of TC with ileorectal anastomosis has less morbidity, preserves the rectum, provides continence, does not require extensive pelvic dissection and allows for immediate reconstruction of the bowel, without the need for a temporary stoma. However, depending on the duration of monitoring and age of the patient, the incidence of metachronous cancer in the rectal remnant is reportedly 7–37%,<sup>7-11</sup> which is a major drawback compared with TPC. Thus, our preferred treatment for patients with classical FAP and more than 20 polyps in the rectum is TPC followed by ileal pouch ileoanal anastomosis. We reserve TC with ileorectal anastomosis for individuals with attenuated FAP and few rectal polyps and for those in whom it is difficult to fashion an ileal pouch because of excessive anastomosis tension and the attendant higher risk of fistula.

The age at which preventive surgical treatment is indicated is based on the following objective data: age of onset of polyps, age of transformation of polyps in other family members, the patient's signs and symptoms, risk of cancer based on colonoscopy and periodic biopsies, and the specific type of mutation identified in that patient/family. Surgery with preservation of the rectum should be accepted by the patient, thus requiring longer periodic rectal monitoring.<sup>12</sup> About 15 cm should be retained to preserve the reservoir function of the rectal remnant: this permits fecal continence, but patients may have some degree of urgency and increased

frequency of bowel movements (on average five times a day).<sup>12,13</sup>

Both surgical techniques studied were associated with recurrent or underlying polyps; however, with TC, which preserves a segment of the rectum, polyps appeared earlier and were more numerous and dense. In those who have undergone TPC, the risk of metachronous cancer in the ileal pouch is small; however, adenomas reportedly occur more frequently as time passes.<sup>14,15</sup> The risk of CRC is higher around the anus, where polyps may occur in the remnant mucosal ring between the dentate line and the straight line section of the double stapling technique. However, compared with TC, recurrent polyps occur less frequently and are in a more favorable location for resection, which may reduce the incidence of cancer.

In addition to the high frequency of polyps in classic polyposis, various other factors are responsible for the higher incidence of metachronous lesions in this condition, including varying extent of colonic resection, varying indications for surgery according to age, the locus of the mutation, the diverse histology of polyps and follow-up time; the incidence of polyps reaches over 40% by 20 years after surgery.<sup>8-11,16,17</sup> One of our cases was diagnosed with metachronous rectal cancer (T1N0M0) after 5 months of total colectomy with ileorectal anastomosis, undergoing salvage treatment by complete proctectomy and ileal pouch anal anastomosis. The failure of preoperative colonoscopy to detect synchronous dysplastic lesions is one of the causes of early diagnosis after short-term follow-up. We therefore recommend detailed preoperative endoscopic evaluation of rectal polyps by experienced specialists.

When the anal canal is filled with polyps, care must be taken during mucosal resection so as not to injure the internal anal sphincter. Intestinal transit can be reconstructed by performing a manual ileoanal anastomosis transanally, as proposed by Parks and Percy.<sup>18</sup> However, many studies have found that this technique produces worse functional results than the double stapling technique, the latter preserves good sensory function in the anal transition zone, which is important in maintaining an acceptable frequency of evacuation and anal continence.<sup>9,12,16,17,19</sup>

Introduction of new types of stapler that facilitate resection and reconstruction and decrease the duration of surgery have recently been associated with a steep learning curve and improvement in surgical techniques, such that restorative proctocolectomy and ileal pouch anal anastomosis have been increasingly accepted for treatment of classical polyposis. Several series have shown that most individuals are satisfied with the resultant quality of life and preservation of fecal continence; however, other functional outcomes vary.<sup>13,20,21</sup> Some women avoid sexual activity for fear of dyspareunia and fecal incontinence, the latter being reported in 3-22% of cases. In addition, fashioning of an ileal pouch may reduce fertility; this can also occur in individuals who have undergone same type of surgery for other reasons.<sup>13,22-24</sup> Depending on the surgical technique, men may experience erectile dysfunction (0-1.5%) and premature ejaculation (3-4%) because of denervation of the pelvic plexus.<sup>20,21,23,24</sup>

Aziz et al.<sup>12</sup> performed a meta-analysis of 12 published studies comprising 1002 patients in all; six of these studies reported significantly fewer reoperations within 30 days in the

TC group than in the TPC group (OR 2.11, range of 95% CI: 1.21, 3.70). There were no significant differences between these two procedures in incidence of intestinal obstruction (reported in 10 studies), postoperative hemorrhage (three studies), intra-abdominal sepsis (eight studies), anastomotic leakage (five studies) or wound infection (six studies). However, accurate comparison of morbidities in these studies was hindered by a lack of uniformity in reporting types of complications and a diversity of ages and comorbidities. Despite these factors, both published reports and our objective data generally indicate that TPC is associated with more frequent complications and poorer functional outcomes than TC, which is of particular concern in patients at low risk of metachronous rectal cancer. Thus, the choice between these two techniques should be made on an individual basis.

## Conclusions

Every individual with FAP has a high risk of developing CRC and the best form of preventive treatment available is surgery. Surgical morbidity is not negligible in either of the two surgical techniques studied; therefore, treatment should be provided by specialized reference centers that offer genetic counseling to family members.

In order to provide a better quality of life to individuals with FAP, TC with ileorectal anastomosis is commonly offered; this technique is simple and traditionally associated with lower rates of postoperative complications and better functional outcomes. However, because it is associated with a significantly higher probability of metachronous rectal cancer, it has become a less attractive technique in patients with the classical or diffuse form of FAP. The option of TPC confers a lower risk of CRC.

## Conflicts of interest

The authors declare no conflicts of interest.

## REFERENCES

1. Elizabeth H, Dani B, Paul R. Familial adenomatous polyposis. *Orphanet J Rare Dis.* 2009;4:22.
2. Clark SK, Neale KF, Landgrebe JC, Phillips RKS. Desmoid tumors complicating familial adenomatous polyposis. *Br J Surg.* 1999;86:1185-9.
3. Lindor NM, Greene MH. The concise handbook of family cancer syndromes. Mayo Familial Cancer Program. *J Natl Cancer Inst.* 1998;14:1039-71.
4. Vasen HF, Moslein G, Alonso A, Aretz S, Bernstein I, Bertario L, et al. Guidelines for the clinical management of familial adenomatous polyposis (FAP). *Gut.* 2008;57:704-13.
5. De Cosse JJ, Bulow S, Neale K, Järvinen H, Alm T, Hultcrantz R, et al. Rectal cancer risk in patients treated for familial adenomatous polyposis. The Leeds Castle Polyposis Group. *Br J Surg.* 1992;79:1372-5.
6. Heiskanen I, Harvinen HJ. Fate of the rectal stump after colectomy and ileorectal anastomosis for familial adenomatous polyposis. *Int J Colorectal Dis.* 1997;12:9-13.
7. Bulow C, Vasen H, Jarvinen H, Bjork J, Bisgaard ML, Bulow S. Ileorectal anastomosis is appropriate for a subset of patients

- with familial adenomatous polyposis. *Gastroenterology*. 2000;119:1454–60.
8. Bjork JA, Akerbrant HI, Iselius LE, Hultcrantz RW. Risk factors for rectal cancer morbidity and mortality in patients with familial adenomatous polyposis after colectomy and ileorectal anastomosis. *Dis Colon Rectum*. 2000;43:1719–25.
  9. Heiskanen I, Jarvinen HJ. Fate of the rectal stump after colectomy and ileorectal anastomosis for familial adenomatous polyposis. *Int J Colorectal Dis*. 1997;12:9–13.
  10. Nugent KP, Phillips RK. Rectal cancer risk in older patients with familial adenomatous polyposis and an ileorectal anastomosis: a cause for concern. *Br J Surg*. 1992;79:1204–6.
  11. Bess MA, Adson MA, Elveback LR, Moertel CG. Rectal cancer following colectomy for polyposis. *Arch Surg*. 1980;115:460–7.
  12. Aziz O, Athanasiou T, Fazio VW, Nicholls RJ, Darzi AW, Church J, et al. Meta-analysis of observational studies of ileorectal versus ileal pouch-anal anastomosis for familial adenomatous polyposis. *Br J Surg*. 2006;93:407–17.
  13. Kartheuser A, Stangherlin P, Brandt D, Remue C, Sempoux C. Restorative proctocolectomy and ileal pouch-anal anastomosis for familial adenomatous polyposis revisited. *Fam Cancer*. 2006;5:241–60.
  14. Wu JS, McGannon ES, Church JM. Incidence of neoplastic polyps in the ileal pouch of patients with familial adenomatous polyposis after restorative proctocolectomy. *Dis Colon Rectum*. 1998;41:552–7.
  15. Parc YR, Olschwang S, Desaint B, Schitt G, Parc RG, Tiret E. Familial Adenomatous polyposis: prevalence of adenomas in the ileal pouch after restorative proctocolectomy. *Ann Surg*. 2001;233:360–4.
  16. Heimann TM, Bolnick K, Aufses AH Jr. Results of surgical treatment for familial polyposis coli. *Am J Surg*. 1986;152:276–8.
  17. James Church MB. Familial adenomatous polyposis. *Surg Oncol Clin N Am*. 2009;18:585–98.
  18. Parks IC, Percy JP. Resection and sutured coloanal anastomosis for rectal carcinoma. *Br J Surg*. 1982;69:301–4.
  19. Iwama T, Mishima Y, Utsunomiya J. The impact of familial adenomatous polyposis on the tumorigenesis and mortality at the several organs. Its rational treatment. *Ann Surg*. 1993;217:101–8.
  20. Parc Y, Moslein G, Dozois RR, Pemberton JH, Wolff BG, King JE. Familial adenomatous polyposis. Results after ileal pouchanal anastomosis in teenagers. *Dis Colon Rectum*. 2000;43: 893–902.
  21. Fazio VW, Ziv Y, Church JM, Oakley JR, Lavery IC, Milsom JW, et al. Ileal pouch-anal anastomoses complications and function in 1005 patients. *Ann Surg*. 1995;222:120–7.
  22. Olsen KØ, Juul S, Bülow S, Järvinen HJ, Bakka A, Björk J, et al. Female fecundity before and after operation for familial adenomatous polyposis. *Br J Surg*. 2003;90:227–31.
  23. Colwell JC, Gray M. What functional outcomes and complications should be taught to the patient with ulcerative colitis or familial adenomatous polyposis who undergoes ileal pouch anal anastomosis. *J Wound Ostomy Cont Nurs*. 2001;28:184–9.
  24. Nyam DC, Brilliant PT, Dozois RR, Kelly KA, Pemberton JH, Wolff BG. Ileal pouch-anal canal anastomosis for familial adenomatous polyposis: early and late results. *Ann Surg*. 1997;226:514–9.