J COLOPROCTOL (RIO J). 2015;35(1):72–75

Journal of Coloproctology

www.jcol.org.br

Technical Note

Endoscopic pilonidal sinus treatment (E.P.Si.T.): a minimally invasive approach☆

Carlos Ramon Silveira Mendes[a,b,c,*], *Luciano Santana de Miranda Ferreira*[a,c], *Ricardo Aguiar Sapucaia*[a,c], *Meyline Andrade Lima*[a,c]

[a] *Coloproctology Service, Hospital Santa Izabel, Santa Casa de Misericórdia da Bahia, Salvador, BA, Brazil*
[b] *Hospital Geral Roberto Santos, Salvador, BA, Brazil*
[c] *Sociedade Brasileira de Coloproctologia (SBCP), Rio de Janeiro, RJ, Brazil*

ARTICLE INFO

Article history:
Received 3 November 2014
Accepted 30 November 2014
Available online 28 January 2015

Keywords:
Pilonidal disease
Pilonidal sinus
Fistuloscope

ABSTRACT

Introduction: The pilonidal cyst is a chronic inflammatory process that occurs frequently in the sacrococcygeal region. It is more common in males with a ratio of 3:1 and usually presents itself in the third decade of life. The treatment is mainly surgical with various forms. The search for new technologies as well as for a minimally invasive treatment has become of utmost importance in surgical routines. The technique E.P.Si.T. (endoscopic treatment of pilonidal cyst) developed by Meneiro has been quite interesting in the treatment of pilonidal cysts.

Surgical technique: Anesthetized the patient in the supine position. Identified the drainage hole of the cyst, and began with the passage of fistuloscope studying the path of the cyst. Performs following the removal of all the tissue inside as the hair followed by cauterization of the path. Removed all devitalized tissue and enlargement of the opening of the cyst.

© 2015 Sociedade Brasileira de Coloproctologia. Published by Elsevier Editora Ltda. All rights reserved.

Tratamento endoscópico do cisto pilonidal (E.P.Si.T.): Uma abordagem minimamente invasiva

Palavras chave:
Doença pilonidal
Cisto pilonidal
Fistuloscopio

RESUMO

Introdução: O cisto pilonidal é um processo inflamatório crônico que ocorre com frequência na região sacrococcígea. É mais comum no sexo masculino com proporção de 3:1 e mais presente na terceira década. O tratamento é eminentemente cirúrgico com diversas formas de realização. A busca de novas tecnologias bem como o tratamento minimamente invasivo se tornou prioridade máxima nas rotinas cirúrgicas. A técnica do E.P.Si.T (Tratamento endoscópico do cisto pilonidal) desenvolvida por Meneiro tem se mostrado bastante interessante no tratamento dos cistos pilonidais.

☆ Study conducted at Hospital Santa Izabel, Santa Casa de Misericórdia da Bahia, Salvador, BA, Brazil.

* *Corresponding author.*
E-mail: proctoramon@hotmail.com (C.R.S. Mendes).

http://dx.doi.org/10.1016/j.jcol.2015.01.007

2237-9363/© 2015 Sociedade Brasileira de Coloproctologia. Published by Elsevier Editora Ltda. All rights reserved.

Técnica cirúrgica: Paciente em decúbito dorsal sob anestesia. Identifica o orifício de drenagem do cisto, e inicia com a passagem do fistuloscópio estudando o trajeto do cisto. Realiza a seguir a remoção de todo o tecido no interior como os fios de cabelo seguido da cauterização do trajeto. Removido todo o tecido desvitalizado e ampliação da abertura do cisto.

© 2015 Sociedade Brasileira de Coloproctologia. Publicado por Elsevier Editora Ltda. Todos os direitos reservados.

Introduction

Pilonidal cyst is a chronic inflammatory process that occurs with frequency in the sacrococcygeal region, usually associated with the presence of hair in this region.[1–6] Its presentation is more common in males, with a ratio of 3:1, usually in the third decade of life.[7,8]

The methods used for pilonidal cyst treatment are eminently surgical. Several forms are described, such as incision and curettage and excision and flap rotation, as well as excision with second intention healing.[9–11] These approaches are quite aggressive, resulting in a large wound that must be cared for. With the advent of new technologies and the pursuit for minimally invasive procedures, Meneiro described in 2013 an approach for endoscopic treatment of pilonidal cysts (E.P.Si.T.).[12] This procedure was developed after the use of a fistuloscope for anal fistulas,[13,14] being applied to this pathology.

The aim of this study is to describe the first report of this technique in Brazil, held by our team, in June 2014.

Surgical technique

To perform the procedure, a spinal anesthesia is required; the patient is placed in a ventral recumbent position, with identification of the orifice of cyst drainage. The surgeon stands between the patient's legs and the video set is positioned to the left of the surgeon (Fig. 1). To perform the technique, a kit, which includes the fistuloscope (Karl Storz GmbH, Tuttlingen, Germany; Fig. 2), an obturator, an endobrush, a unipolar electrode and a grasping forceps, is used. The 18-cm length fistuloscope has an 8° angled eyepiece; the device has a diameter of 3.2 mm × 4.8 mm, being connected to an optical fiber and to a continuous irrigation system. After the passage of the fistuloscope through the cyst hole with infusion of 1% glycine or mannitol, the surgeon searches the cyst, looking for accessory tracts as well as for abscesses. Once the obturator of the equipment is removed, the surgeon starts removing hair and devitalized tissues. After studying the cyst and finishing the tissue removal, the whole-tract cauterization stage begins. To that end, the surgeon uses the electrocautery connected to a power source to remove all granulation tissue present in the cyst cavity. Necrotic tissue is removed with brushing the cavity; with that, the whole tract is cleaned. At the end of the procedure, the surgeon creates an external opening to facilitate drainage of the cavity, and also to enlarge the initial hole (Fig. 3).

Fig. 1 – Introduction of the fistuloscope.

Discussion

Pilonidal cyst is a very common disorder, with an estimated incidence of 26 cases per 100,000 people, affecting men three times more than women.[15] Men are more affected thanks to

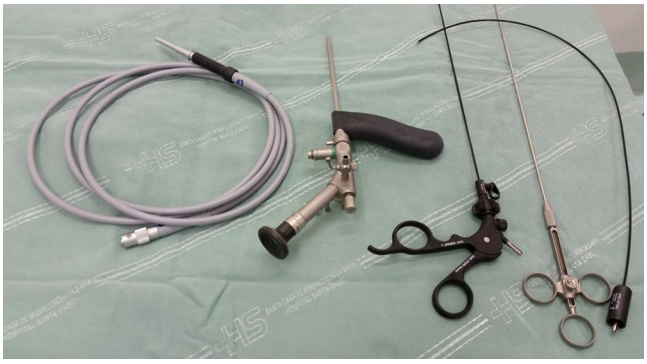

Fig. 2 – Fistuloscope, Karl Storz GmbH (Tuttlingen, Germany).

Fig. 3 – Final aspect.

their natural hirsutism. The occurrence of a pilonidal cyst is also associated with obesity, sedentary lifestyle and local irritation or trauma.[16,17] The treatment of pilonidal cyst is mainly surgical; there are various techniques described in the literature, e.g., incision and curettage, excision, techniques combined with plastic surgery with rotation flaps, marsupialization or fistulotomy.[18] The ideal method should combine a smaller loss of tissue, minimal postoperative morbidity, cosmetic results, rapid return to work activities, low cost and low recurrence rate.[19] However, although numerous surgical methods have been described, none of them encompasses all of these characteristics.[20]

The main techniques used – incision and curettage and excision – result in large wounds, requiring local care and a delayed healing, as well as the possibility of local recurrence.

In an effort to minimize this drawback, various techniques have been described, e.g., flap rotation and the use of flaps; however, these techniques are not without complications, and wound infection (0.8–7.6%), seroma (1.5–5.2%), dehiscence (4.1%), flap necrosis (3%) and recurrence (1.2–4.9%) have been reported.[21–24]

In 2013, Meinero et al. described a new technique for pilonidal cyst approach with the use of a fistuloscope. With this instrument and under direct vision, it is possible to destroy all granulation tissue and to remove the entire infected area of the cyst, leaving a small open wound for drainage. In their initial series of 11 patients, all subjects had their wounds healed within one month after surgery, with an average return to work in 3.5 days.

There was no recurrence in a 6-month follow-up period (ranging from 1 to 9 months).[12]

In 2014, Milone et al. published their series with this procedure in 27 patients, with a 12-month follow-up. All wounds healed within 15 days, with recurrence in only one patient, two months after surgery. These studies show that this is a very effective technique for the treatment of this disease.[25]

In this paper, we describe our experience with an initial case, using this technique in a 32-year-old male patient. The patient was placed in the prone position under spinal anesthesia and intravenous sedation. The fistula orifice was catheterized; then the fistuloscope was introduced, using a solution of glycine 1.5%. The tract of the cyst was identified and studied, with removal of hair inside the lesion. In sequence, the tract was cauterized, with removal of devitalized tissue; finally the drain orifice was enlarged. The patient has been followed up (to date, during 10 months), with good healing and no signs of recurrence.

Conclusion

This is a minimally invasive procedure with little aggression to the tissues involved. Its great advantages are an early return to activity and a small surgical scar, with less pain/inconvenience to the patient. On the other hand, the technique has the disadvantage of the availability of a fistuloscope kit for performing the procedure.

Conflicts of interest

The authors declare no conflicts of interest.

REFERENCES

1. Bendewald FP, Cima RR. Pilonidal disease. Clin Colon Rectal Surg. 2007;20:86–95.
2. Buczacki S, Drage M, Wells A, Guy R. Sacrococcygeal pilonidal sinus disease. Colorectal Dis. 2009;11:657.
3. Balsamo F, Borges AMP, Formiga GJS. Cisto pilonidal sacrococcígeo: resultados do tratamento cirúrgico com incisão e curetagem. Rev Bras Coloproct. 2009;29:325–8.
4. Ekçi B, Gökçe O. A new flap technique to treat pilonidal sinus. Tech Coloproctol. 2009;13:205–9.
5. Sit M, Aktas G, Yilmaz EE. Comparison of the three surgical flap techniques in pilonidal sinus surgery. Am Surg. 2013;79:1263–8.
6. Parades V, Bouchard D, Janier M, Berger A. Pilonidal sinus disease. J Visc Surg. 2013;150:237–47.
7. Majeski J, Stroud J. Sacrococcygeal pilonidal disease. Int Surg. 2011;96:144–7.
8. Muzi MG, Maglio R, Milito G, Nigro C, Ciangola I, Bernagozzi B, et al. Long-term results of pilonidal sinus disease with modified primary closure: new technique on 450 patients. Am Surg. 2014;80:484–8.
9. Corsi P, Corsi R, Moura L, Guerreiro T. Vasconcellos Tratamento cirúrgico do cisto pilonidal através de ressecção e fechamento primário com retalho cutâneo. Rev Bras Coloproct. 2004;24:203–7.
10. Horwood J, Hanratty D, Chandran P, Billings P. Primary clousure or rhomboid excision and Limberg flap for the management of primary sacrococcygeal pilonidal disease? A meta-analysis of randomized controlled trials. Colorectal Dis. 2012;14:143–51.
11. Mahdy T. Surgical treatment of the pilonidal disease: primary closure or flap reconstruction after excision. Dis Colon Rectum. 2008;51:1816–22.
12. Meneiro P, Mori L, Gasloli G. Endosopic pilonidal sinus treatment (E.P.Si.T.). Tech Coloproctol. 2014;8:389–92.
13. Mendes CRS, Ferreira LSM, Sapucaia RA, Lima MA, Araujo SEA. VAAFT – Videoassisted anal fistula treatment: a new approach for anal fistula. J Coloproctol. 2014;34:62–4.
14. Mendes CR, Ferreira LS, Sapucaia RA, Lima MA, Araujo SE. Video-assisted anal fistula treatment: technical considerations and preliminary results of the first Brazilian experience. Arq Bras Cir Dig. 2014;27:77–81.
15. Blendewald FP, Cima RR. Pilonidal disease. Clin Colon Rectal Surg. 2007;20:86–95.
16. Bascom J. Surgical treatment of pilonidal disease. BMJ. 2008;336:842–3.
17. Menzel T, Dorner A, Cramer J. Excision and open wound treatment of pilonidal sinus. Rate of recurrence and duration of work incapacity. Dtsch Med Wochenschr. 1997;122:1447–51.
18. Varnalidis I, Loannidis O, Paraskevas G, et al. Pilonidal sinus: a comparative study of treatment methods. J Med Life. 2014;7:27–30.
19. Akinci OF, Coskun A, Uzunkoy A. Simple and effective surgical treatment of pilonidal sinus: asymmetric excision and primary closure using suction drain and subcuticular skin closure. Dis Colon Rectum. 2000;43:701–6.
20. Altintoprak F, Dikicier E, Arslan Y, et al. Comparison of the Limberg flap with the V–Y flap technique in the treatment of pilonidal disease. J Korean Surg Soc. 2013;85:63–7.

21. Daphan C, Tekelioglu MH, Sayilgan C. Limberg flap repair for pilonidal sinus disease. Dis Colon Rectum. 2004;47:233–7.
22. Al-Hassan HK, Francis IM, Neglen P. Primary closure or secondary granulation after excision of pilonidal sinus. Acta Chir Scand. 1990;156:695–9.
23. Ertan T, Koc M, Gocmen E, Aslar AK, Keskek M, Kilic M. Does technique alter quality of life after pilonidal sinus surgery. Am J Surg. 2005;190:388–92.
24. Urhan MK, Kucukel F, Topgul K, Ozer I, Sari S. Rhomboid excision and Limberg flap for managing pilonidal sinus: results of 102 cases. Dis Colon Rectum. 2002;45:656–9.
25. Milone M, Musella M, Sardo ADS, Bifulco G, Salvatore G, Fernandez LMS, et al. Video-assisted ablation of pilonidal sinus: a new minimally invasive treatment – a pilot study. Surgery. 2014;155:562–6.