



Case Report

Late diagnosis of Hirschsprung's disease



Marielle Rodrigues Martins^{a,b,*}, Carlos Henrique Marques dos Santos^{a,b,c},
Gustavo Ribeiro Falcão^{a,b}

^a Universidade Federal de Mato Grosso do Sul (UFMS), Campo Grande, MS, Brazil

^b Hospital Universitário Maria Aparecida Pedrossian, Campo Grande, MS, Brazil

^c Hospital Regional de Mato Grosso do Sul (HRMS), Campo Grande, MS, Brazil

ARTICLE INFO

Article history:

Received 11 December 2014

Accepted 20 February 2015

Available online 27 May 2015

Keywords:

Hirschsprung's disease
Congenital megacolon
Fecal incontinence

Palavras-chave:

Doença de Hirschsprung
Megacolo congênito
Incontinência fecal

ABSTRACT

Hirschsprung's disease is a condition characterized by the absence of ganglion cells in a variable segment of the large intestine, mainly producing the symptom of constipation and being usually diagnosed in the first year of life. With diagnostic methods already established in the literature, the sole treatment is surgery. The objective of this study is to report a case of late diagnosis of the disease at age 13, with symptoms of fecal incontinence in its evolution.

© 2015 Sociedade Brasileira de Coloproctologia. Published by Elsevier Editora Ltda. All rights reserved.

Diagnóstico tardio da doença de Hirschsprung

RESUMO

A Doença de Hirschsprung é uma patologia caracterizada pela ausência de células ganglionares em um segmento variável do intestino grosso, produzindo principalmente o sintoma de constipação, sendo normalmente diagnosticada até o primeiro ano de vida. Com métodos diagnósticos já consagrados na literatura, o tratamento é exclusivamente cirúrgico. O objetivo deste trabalho é relatar um caso de diagnóstico tardio da doença, aos 13 anos, com sintomatologia de incontinência fecal na evolução do quadro.

© 2015 Sociedade Brasileira de Coloproctologia. Publicado por Elsevier Editora Ltda. Todos os direitos reservados.

Introduction

Hirschsprung's Disease (HD), also known as congenital aganglionic megacolon, is an anomaly characterized by an absence

of ganglion cells in the myenteric and submucosal plexuses in a variable bowel segment.^{1,2}

The absence of ganglion cells results in permanent contraction of the affected segment, preventing the passage of fecal content through that region.³ The distal functional

* Corresponding author.

E-mail: marielle.rmartins@gmail.com (M.R. Martins).

<http://dx.doi.org/10.1016/j.jcol.2015.02.009>

2237-9363/© 2015 Sociedade Brasileira de Coloproctologia. Published by Elsevier Editora Ltda. All rights reserved.

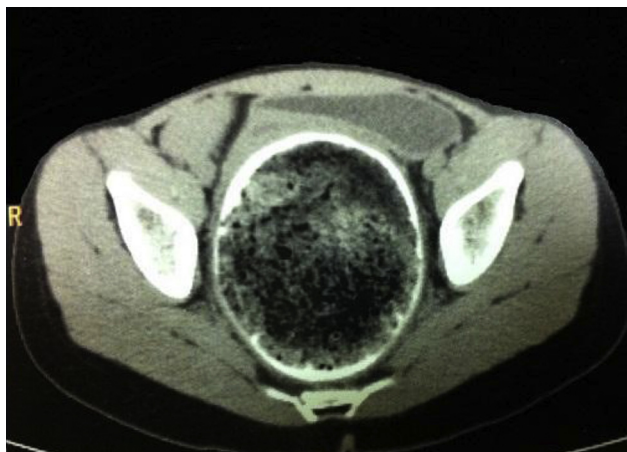


Fig. 1 – Computed tomography (axial plane) showing rectal fecal impaction with megarectum.

obstruction leads to inefficient peristaltic contractions, with consequent dilatation of proximal intestine, producing megacolon.¹

HD presents itself by symptoms of constipation, such as a greater than 48-h delay in elimination of meconium, abdominal distention and vomiting. In 80% of cases, this disease is diagnosed in the first year of life, being uncommon in adolescence and adulthood; such cases usually appear in the form of an ultrashort segment disease.⁴

The objective of this paper is to report a case of HD in a 13-old patient, with treatment and outpatient follow-up at the Hospital Regional de Mato Grosso do Sul Rosa Pedrossian – HRMS. The infrequency of this diagnosis in this age and the clinical course of this patient underscore the uniqueness of this case.

Clinical case

Female patient, 13 years old, coming from Campo Grande – MS, reports that since birth had intestinal constipation, with mean bowel movements at every 3–5 days with hardened feces, being followed-up by a pediatrician and in treatment for functional constipation. The girl refers onset of fecal incontinence at the age of 12.

Tests ordered: given the unavailability of barium enema, a computed tomography (CT) study was obtained, revealing the presence of rectal fecaloma (Figs. 1 and 2).

A hypothesis of HD was proposed; thus an anorectal manometry was asked, but its result was inconclusive due to patient's lack of cooperation.

Then a rectal biopsy was performed; the pathologist report confirmed the absence of ganglion cells with neurotization of myenteric and submucosal plexuses in a short rectal segment (Fig. 3), confirming an ultra-short form of aganglionosis.

Serology for Chagas' disease was carried out in order to exclude a diagnosis of Chagas' Disease megacolon, with negative result. Thus, the diagnosis of HD was confirmed. Surgical treatment was performed laparoscopically, according to Duhamel-Haddad technique modified with protective

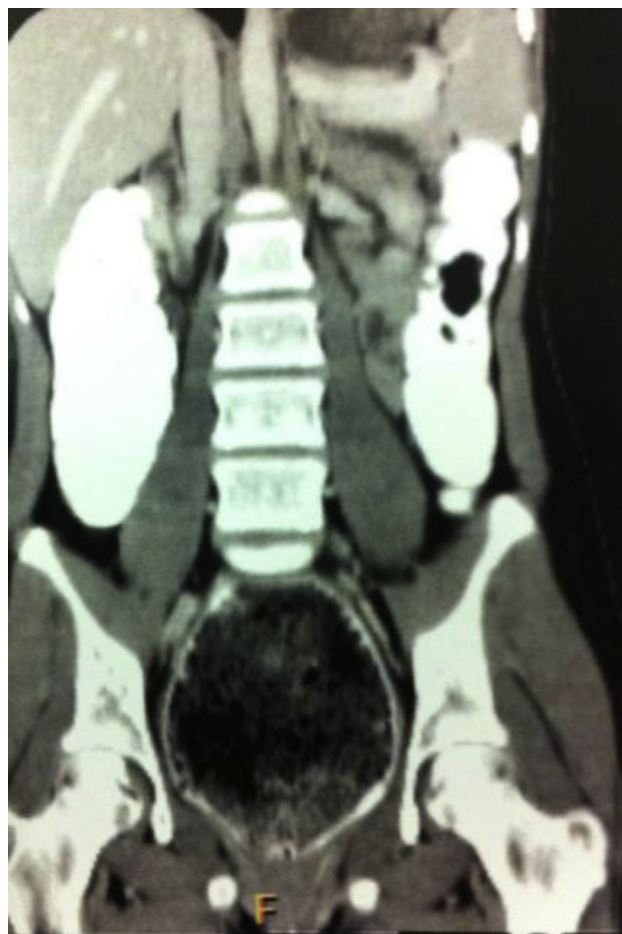

Fig. 2 – Computed tomography (coronal plane) showing rectal fecal impaction with megarectum.

loop ileostomy, with good clinical progression. The girl was discharged on the 5th day after surgery.

Discussion

HD is a congenital anomaly that occurs due to a discontinuation of the cranial-caudal migration of neural crest cells, which are responsible for innervation of the colon, or when the ganglion cells undergo premature death between 5th and 12th weeks of pregnancy.¹⁻³ It was also suggested that changes in the extracellular matrix in the human embryo gut can interrupt the migration of neural crest-derived cells, producing aganglionosis.²

According to the extent of colon involvement, HD is classified into short-segment disease (80% of cases), when the aganglionic segment does not exceed the sigmoid colon; or into long-segment disease, when it outruns the sigmoid colon. In this latter case, HD may affect the entire colon and even the small intestine.⁵ HD is still classified into ultrashort-segment disease when it involves only the distal part of the rectum, occurring in 2–3% (in some reports, with estimates of up to 8%) of the cases.^{2,6}

HD occurs in approximately 1 in 5000 live births. It can occur alone or in combination with other development

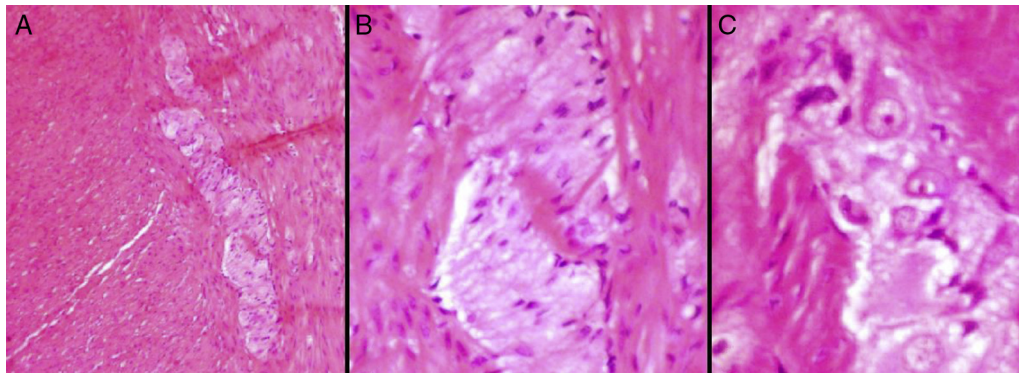


Fig. 3 – Histopathology – (A and B) absence of ganglion cells. (C) Surgical margin with ganglion cells.

abnormalities; 10% of all cases occur in children with Down syndrome.¹

Most cases of HD are sporadic, but 10% have a familial origin. Half of familial cases and 15% of sporadic cases are associated with gene mutations inactivating the RET receptor for tyrosine kinase on chromosome 10q. Some cases involve gene mutations for endothelin-B receptor.³ As this is an autosomal dominant disorder with incomplete penetrance, the modification of genes or environmental factors must also be important.¹

In addition, it is established that factors related to gender play a role, since men are preferentially affected, at a frequency of 4:1.⁵ However, in cases where the diagnosis is made in a more advanced age, the frequency is higher among females (3:1),^{7,8} as is the case for our patient.

The symptoms that lead to an early suspicion of HD are bowel constipation, defined in the newborn as a greater than 48-h delay in the elimination of meconium associated with abdominal distension and vomiting. In 80% of cases HD is diagnosed within the first year of life. This disorder is uncommon in adolescence and in adulthood and when present in this age group, it shows up as an ultrashort-segment disease.⁴

In the literature, in 50–60% of cases the diagnosis is established in the first month of life.⁹ However, mild cases of HD can elude an early diagnosis, either by lack of symptoms, or because its symptoms are misinterpreted. In such cases, it is common a certain degree of constipation of fluctuating intensity, with fecaloma characterizing the clinical progression, often in association to changes in nutrition and to growth.¹⁰

Some patients reach adulthood without a diagnosis for this disease. Typically, patients go to the doctor with a long-standing history of constipation requiring frequent laxative use.¹¹ The current frequency of the disease in adults is unknown, especially since HD is an overlooked and misdiagnosed disease in this age group.

Our patient had a history of long-standing bowel constipation, progressing to fecal incontinence. This finding can be explained by a permanent distention of the anal canal due to the presence of a fecaloma, with constant pressure on the internal sphincter and keeping it open. Therefore, the most liquid stools upstream pass around the fecal impaction and produce the reported symptom, known as fecal incontinence (soiling). This clinical course is atypical; in the literature

review, only three similar cases were related in association with Hirschsprung disease.^{12,13}

Complaints of fecal incontinence are often reported in the literature in cases of functional constipation and of idiopathic megacolon.^{11,14} This problem is also reported in patients with acquired megacolon, being more uncommon in congenital cases due to the permanence of a closed internal anal sphincter.¹¹ Fecal incontinence is a common post-operative complication of congenital megacolon.²

For our patient, fecal incontinence is a more limiting symptom than the constipation itself, because the girl was living in constant fear of occurrence of such fact in environments like her school, which would cause great embarrassment before other people. In addition, the reported symptoms caused the girl's parents to begin to justify such a fact as a result of some psychological, rather than organic, disorder. This factor contributed to the delay in her diagnosis, driving the pediatrician out of a HD hypothesis. Therefore, fecal incontinence can cause emotional disturbances to patients, with subsequent relationship problems at school and with their own families.¹⁵

The diagnosis of HD is supported by barium enema studies, anorectal manometry and rectal biopsy.⁴

The technique considered as the golden standard for the diagnosis of HD is the absence of ganglion cells in a rectal biopsy specimen. In addition, there may be an increase in non-myelinated cholinergic nerve fibers in the submucosa and among muscle layers (neural hyperplasia), which helps in diagnostic confirmation,² as was the case of our patient.

Imaging studies such as computed tomography (CT) and barium enemas are usually accepted for evaluation of chronic constipation, which is a common disorder in adults.¹⁶ Our patient underwent CT due to the unavailability of a barium enema study, but CT is a more expensive method.

The anorectal manometry, even though not contributing in the present case, is an ancillary test of the utmost importance, since the presence of the rectum-anal reflex in this exam usually rule out the diagnosis of HD.¹⁴

Several procedures are used to manage this disease after childhood; currently the option of choice is the surgical procedure of Duhamel.¹¹ Late diagnosis contributes to the need for surgery in more than one surgical time, with ileostomy or colostomy, since the healthy colon is more distended in adolescents and adults compared to neonates and children.⁸

Nevertheless, the literature considers as the procedure of choice the Duhamel technique in only one surgical time,² which reduces the hospitalization time.

This surgery is considered curative. However, post-operative bowel functioning is not always satisfactory. Enterocolitis, constipation and fecal incontinence represent the main postoperative complications in children.⁵ To date, the progression for adolescent or adult patients is not fully clarified yet, due to the small number of reported cases.

Conflicts of interest

The authors declare no conflicts of interest.

REFERENCES

1. Robbins SL, Cotran RS, Kumar V. *Patologia: bases patológicas das doenças*. 8th ed. Rio de Janeiro: Elsevier; 2010.
2. Paz AM, Gonzalo A, Gloria RC. Revisión: Enfermedad de Hirschsprung. *Rev Ped Elec*. 2008;5(1). Available at: <http://www.revistapediatria.cl/vol5num1/6.html> [cited 04.03.14].
3. Rubin E. *Rubin patologia: bases clinicopatológicas da medicina*. 4th ed. Rio de Janeiro: Guanabara Koogan; 2010.
4. Icaza Chávez ME, Takahashi Monroy T, Uribe Uribe N, Hernández Ortiz J, Valdovinos MA. Enfermedad de Hirschsprung en el adulto. Informe de um caso. *Rev Gastroenterol Méx*. 2000;65:171-4.
5. Villar MAM, Jung MDP, Cardoso LCDA, Cardoso MHCDA, Llerena Junior JC. Doença de Hirschsprung: experiência com uma série de 55 casos. *Rev Bras Saúde Matern Infant*. 2009;3:285-91.
6. Bakari AA, Gali BM, Ibrahim AG, Nggada HA, Ali N, Dogo D, et al. Case report: congenital aganglionic megacolon in Nigerian adults: two case reports and review of the literature. *Niger J Clin Pract*. 2011;14:249-52.
7. Burlando E, Bernhardt R, Steger H, Stoletniy E. Enfermedad de Hirschsprung del adulto: corrección quirúrgica. *Rev Argent Resid Cir*. 2009;13:79-81.
8. Lombana LJ, Domínguez LC. Cirugía en la enfermedad de Hirschsprung del adulto. *Rev Colomb Gastroenterol*. 2007;22:231-7.
9. Bigélli RH, Fernandes MI, Galvão LC, Sawamura R. Estudo retrospectivo de 53 crianças com doença de Hirschsprung: achados clínicos e laboratoriais. *Medicina (Ribeirao Preto)*. 2002;35:78-84. Available at: <http://www.revistas.usp.br/rmrp/article/view/798> [cited 04.03.14].
10. Jones FA, Godding EW. *Tratamento da constipacao*. São Paulo: Manole; 1975.
11. Gordon PH, Nivatvongs S. *Principles and practice of surgery for the colon, rectum and anus*. 2th ed. St. Louis: Quality Medical; 1992.
12. Barnes PR, Lennard-Jones JE, Hawley PR, Todd IP. Hirschsprung's disease and idiopathic megacolon in adults and adolescents. *Gut*. 1986;27:534-41.
13. Soto D. Enfermedad de Hirschsprung en adultos. *Ver Cir Chil*. 2001;53:346.
14. Costa-Pinto EAL, Bustorff-Silva JM, Fukushima E. Papel da manometria anorretal no diagnóstico diferencial da constipação em crianças. *J Pediatr (Rio de J)*. 2000;76:227-32.
15. De Moraes MB, Maffei HVL. Constipação intestinal. *J Pediatr*. 2000;76:S147.
16. Kim HJ, Kim AY, Lee CW, Yu CS, Kim JS, Kim PN, et al. Hirschsprung disease and hypoganglionosis in adults: radiologic findings and differentiation 1. *Radiology*. 2008;247:428-34.