



Journal of Coloproctology

www.jcol.org.br



Original Article

Correlation of anorectal electromanometry and anorectal three-dimensional ultrasound findings in patients with fecal incontinence



Tracy Mary Betinardi^{a,*}, Doryane Maria dos Reis Lima^{a,b}, Gustavo Kurachi^c,
Mauro Willemann Bonatto^{a,d}, Tomaz Massayuki Tanaka^{a,e}, Univaldo Etsuo Sagae^{a,f}

^a Faculdade Assis Gurgacz, Cascavel, PR, Brazil

^b Universidade Federal do Ceará (UFC), Fortaleza, CE, Brazil

^c Coloproctologist, Brazil

^d Universidade Federal do Paraná (UFPR), Curitiba, PR, Brazil

^e Escola Paulista de Medicina (EPM), Universidade Federal de São Paulo (Unifesp), São Paulo, SP, Brazil

^f Universidade de São Paulo (USP), São Paulo, SP, Brazil

ARTICLE INFO

Article history:

Received 8 August 2013

Accepted 8 June 2015

Available online 2 October 2015

Keywords:

Incontinence

Anal manometry

3D ultrasound

Anismus

Hypotonic contraction

Hypotonia at rest

Sphincter injury

ABSTRACT

Objective: To show the correlation of anorectal electromanometry and three-dimensional anorectal ultrasonography in patients with fecal incontinence.

Method: Prospective study involving 34 women (mean age: 55 years) with a diagnosis of fecal incontinence. The samples were submitted to three-dimensional anorectal ultrasonography/Echodefecography and anorectal electromanometry.

Results: Based on anorectal electromanometry data, 70.5% of 34 patients had hypotonia at rest, 64.7% had hypotonic contraction, 52.9% had both hypotonia at rest and hypotonic contraction, and 44.1% had anismus. By three-dimensional anorectal ultrasonography, 32.3% had internal anal sphincter injury, 79.4% had external anal sphincter injuries, and 26.4% had both internal and external anal sphincter injuries. In 38.2%, anismus was suggested and 50% showed rectocele. Overall, only 5.8% had normal results for anorectal electromanometry combined with three-dimensional anorectal ultrasonography. Kappa index was 0.297 and the presence of anismus through anorectal electromanometry and three-dimensional anorectal ultrasonography was compared by Student's t test application, with $p < 0.0001$.

Conclusion: We conclude that there was a reasonable agreement in the comparison of sphincter hypotonia by anorectal manometry and sphincter injury by anorectal three-dimensional ultrasonography in a group of patients with fecal incontinence. The incidence of anismus in patients with fecal incontinence is considerable, and the therapeutic approach in these patients should be modified.

© 2013 Sociedade Brasileira de Coloproctologia. Published by Elsevier Editora Ltda. All rights reserved.

* Corresponding author.

E-mail: tracymar@hotmail.com (T.M. Betinardi).

<http://dx.doi.org/10.1016/j.jcol.2015.06.007>

2237-9363/© 2013 Sociedade Brasileira de Coloproctologia. Published by Elsevier Editora Ltda. All rights reserved.

Correlação dos achados da Eletromanometria anorretal e Ultrassonografia anorretal tridimensional nos pacientes portadores de incontinência fecal

R E S U M O

Palavras-chave:

Incontinência
Manometria anal
Ultrassom 3D
Anismus
Contração hipotônica
Hipotonia em repouso
Lesão esfínctérica

Objetivo: Demonstrar a correlação entre eletromanometria anorretal (EMAR) e ultrassonografia tridimensional anorretal (3D-US) em pacientes com incontinência fecal.

Método: Estudo prospectivo envolvendo 34 mulheres (média de idade: 55 anos) com diagnóstico de incontinência fecal. As amostras foram submetidas à 3D-US/Ecodefecografia e EMAR.

Resultados: Com base nos dados de EMAR, 70,5% das 34 pacientes exibiam hipotonia em repouso, 64,7% exibiam contração hipotônica, 52,9% hipotonia em repouso e contração hipotônica, e 44,1% exibiam anismus. Com base nos achados de 3D-US, 32,3% exibiam lesão no esfíncter anal interno, 79,4% exibiam lesão no esfíncter anal externo, e 26,4% em ambos os esfíncteres anais interno e externo. Pela 3D-US, em 38,2% das pacientes houve indício de anismus, e em 50%, retocele. No total, apenas 5,8% obtiveram resultados normais combinados para EMAR e 3D-US. Foi constatado um índice Kappa = 0,297 e, no teste t de Student, a comparação de anismus por EMAR e por 3D-US obteve significância de $p < 0,0001$.

Conclusão: Concluímos ter havido concordância razoável ao ser comparada a manometria anorretal para hipotonia esfínctérica e a ultrassonografia tridimensional anorretal para lesão esfínctérica em um grupo de pacientes com incontinência fecal. A incidência de anismus em pacientes com incontinência fecal é considerável, e a abordagem terapêutica para esses pacientes deve ser modificada.

© 2013 Sociedade Brasileira de Coloproctologia. Publicado por Elsevier Editora Ltda.

Todos os direitos reservados.

Introduction

Fecal incontinence (FI) is a condition that precludes the voluntary control of the elimination of gases and feces, being more prevalent in women than in men.¹ Anal continence depends on multiple factors, such as mental function, volume and consistency of stools, colonic transit, rectal distensibility, sphincter function, sensitivity and anorectal reflexes.² Thus, any change in one of these elements can lead to incontinence.

Anorectal electromanometry (AREM) and ultrasonography (US) are useful tests in the evaluation and investigation of FI. Other tests, not widely available, and recommended in selected patients, include defecography, pudendal nerve latency test, and nuclear magnetic resonance.³⁻⁵

AREM is the test for physiological evaluation more widely used in the study of fecal incontinence; it allows the measurement of pressures at rest and contraction pressures, as well as the size of the functional anal canal, capacity, compliance, and rectoanal inhibitory reflex survey. AREM also allows an understanding of the synchronization of sensory and motor components of the anal canal.^{3,6}

Anorectal US is characterized by its usefulness for the anatomic identification of sphincteric muscles: internal anal sphincter (IAS), external anal sphincter (EAS) and puborectalis muscle, as well as perianorectal tissue.⁷⁻⁹ Currently, a new type of anorectal US provided with a three-dimensional transducer (3D) is available. This technology creates a hub with a string of widely mobile axial images.¹⁰⁻¹² Thus, 3D-US produces a high-quality anatomical image of the anal canal and sphincter complex.¹³ Studies comparing the accuracy of two- and three-dimensional endo-anal US versus MRI with

an endo-rectal coil in the measurement of muscle thickness found the same results.^{14,15}

The aim of this study is to correlate the findings of anorectal electromanometry and of three-dimensional anorectal ultrasonography in patients with fecal incontinence.

Method

This is a prospective study of 34 women diagnosed with fecal incontinence. These patients underwent AREM and 3D-US in the period from March 20, 2011 to December 15, 2011. The study was conducted at Gastroclínica Cascavel/PR, and the patients were submitted to AREM and 3D-US & ECD by two coloproctologists (GK & DMRL).

AREM was carried out with the women in left lateral decubitus with their legs flexed at 90°, with no bowel preparation. The device used had an 8-channel system of water for infusion (Dynapack MPX 816, Dynamed). Each patient had a 5-min period for her adaptation to the probe, and also for obtaining stable baseline recordings, before the measurements subsequently obtained. With the use of AREM, one can evaluate the pressure at rest (normal 40–70 mmHg), the contraction pressure (normal 100–200 mmHg), and the movement of sphincter muscles before straining (relaxation: normal; non-relaxation: suggests occurrence of anismus).

A solution with Phosphoenema® was applied two hours before 3D-US & ECD procedures; the patients were positioned in left lateral decubitus with their legs flexed at 90°. The equipment used was a B & K Medical® machine with a 360° rotational transducer type 2050 with a frequency of 10–16 MHz; the device performs an automatic scanning in the

proximal-distal direction, with a 6.0-cm extension. This scanning captures a sequence of trans-axial parallel images with 0.25 mm thickness, resulting in a final image in the cube. Ultrasound gel was instilled and then an ECD was performed. The parameters analyzed with 3D-US & ECD were: internal and external anal sphincter integrity and the presence of rectocele, intussusception and a suggestion of anismus.

The results of AREM, 3D-US & ECD were analyzed using statistical calculations, and a correlation was carried out.

An analysis of agreement with Kappa^{16,17} between these two tests was conducted, and points were awarded to the changes found in AREM, in 3D-US, and in ECD. Soon after, we proceeded with the data correlation. Student's t test was used in order to compare the presence of anismus in AREM, 3D-US & ECD studies.

The inclusion criteria were: female gender, age between 40 and 70 years, and fecal incontinence complaints. The clinical evaluation was based on the Jorge & Wexner incontinence score.¹⁸ Exclusion criteria were: male gender, presence of neoplasia, previous surgery, and subjects aged below 18/above 70 years.

The study was approved by the Ethics Committee on Research in Human Beings, Faculdade Assis Gurgacz (protocol No. 191/2011 and Opinion No. 011/2012-CEP/FAG) issued on January 25, 2012.

Results

The mean age of our patients was 55 years. Based on anorectal manometry data, 70.5% of 34 patients had hypotonia at rest, 64.7% had contraction hypotonia, and 52.9% had an association of hypotonia at rest and contraction hypotonia (Fig. 1). Of all women, 44.1% had a suggestion of anismus (Fig. 2). With 3D-US & ECD, 32.3% of patients had internal anal sphincter injuries, 79.4% had external anal sphincter injuries, and 26.4% had both internal and external anal sphincter injuries.

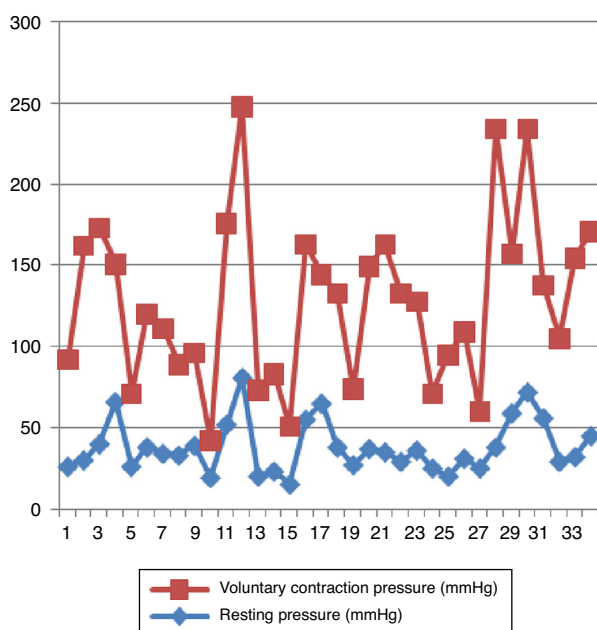


Fig. 1 – Distribution of values of resting and contraction pressures.

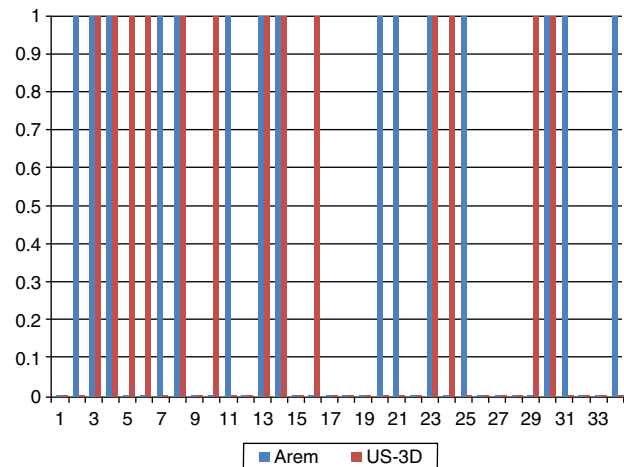


Fig. 2 – Distribution of patients with a hint of anismus by AREM, and 3D-US & ECD.

In 38.2% of patients, a suggestion of anismus was perceived through 3D-US & ECD, and 50% had rectocele.

Of those patients with sphincter hypotonia (at rest and/or with contraction hypotonia), 70.5% had some kind of sphincter (internal and/or external) injury. Overall, only 5.8% of the 34 patients had normal results with AREM combined with 3D-US & ECD.

In the comparison of the two tests used, a Kappa = 0.297 ($p = 0.084$) was obtained, with a reasonable agreement in the evaluation of patients with FI. With Student's t test comparing the presence of anismus by AREM versus 3D-US & ECD, a value for $p < 0.0001$ was obtained; thus, this finding was considered statistically significant.

Discussion

Fecal incontinence is a common condition and exerts a major physical impact on the patient and on his/her psychological well-being. It is estimated that between 0.8 and 15% of the general population suffer from fecal incontinence at least once a month. Generally, FI is defined as the continuous or the periodical passage of non-controlled fecal matter (more than 10 mL) for at least one month in an individual aged over 3 years.¹ In the USA, the estimated incidence of FI lies between 2 and 7%, reaching values of up to 13.6% in people over 65 years and of 16.9% in people over 85 years.^{19,20} In the anal canal, there are various mechanisms and structures which maintain the state of continence. The IAS is tonically contracted, accounting for 80–85% of the pressure of the anal canal at rest. This sphincter temporarily relaxes in response to rectal distension, and this reflex relaxation, mediated by enteric nerves, is not under voluntary control.^{1,9,17,21-25}

EAS consists of a striated muscle with its somatic innervation derived from the pudendal nerve (S2, S3, and S4); it represents the voluntary component of fecal incontinence. The contraction of this muscle nearly doubles the pressure in the anal canal.¹

The main characteristic of anismus is a paradoxical contraction in response to straining. This diagnostic hypothesis

can be envisaged by physical examination and by digital rectal examination, being suggested by AREM, detected by electromyography, and evidenced by defecography and, more recently, by echodefecography (3D-US & ECD)²⁶ as a failure of the anorectal angle to straining.

Many patients with FI complaints do not have anatomical abnormalities, but do exhibit functional changes¹² that, once identified, can improve the incontinence reported by this group of patients. The most important among these functional changes would be anismus, which at the end develops symptoms such as soiling and involuntary emission of flatus/liquid stool, and this worsens (or even simulates) the IF picture.

3D-US is a painless or only slightly painful test, being usually well tolerated by patients; this procedure does not require anesthetic sedation.^{9,21–25} US-3D still presents the characteristic of being a reproducible and minimally invasive examination, and does not expose the patient to radiation.

One application of AREM is the objective measurement of internal and external anal sphincter pressures. This test also may be carried out to measure the length of the anal canal, its complacency, sensitivity, and rectal capacity in response to balloon distention, besides an evaluation of rectosphincteric reflex.^{3,27}

The incidence of changes perceived by AREM in this group of patients was at least of 70.5%; and the incidence of sphincter changes observed in 3D-US & ECD was at least of 79.4%. These results demonstrate how critical is an anatomical evaluation for patients with FI. The authors observed a reasonable agreement when comparing sphincter hypotonia by AREM versus sphincter injury by 3D US in a group of patients with FI.

One characteristic of AREM is to allow the evaluation of the muscles responsible by the straining phenomenon, and this test may suggest the presence or absence of paradoxical contraction of sphincter muscles. The incidence of anismus evaluated in this study was 44.1%, and the findings compared to the results of 3D-US & ECD were regarded as statistically significant. This functional change must be taken into account early in the treatment of patients with FI, and must be treated concomitantly (through a medical or surgical procedure). The accomplishment of 3D-US & ECD also allows the evaluation of other changes that may be associated with these patients, such as rectocele, intussusception, enterocele and/or perineal dehiscence.

Conclusion

Our conclusion is that there was a reasonable agreement when sphincter hypotonia through anorectal manometry and sphincter injury through three-dimensional anorectal ultrasonography were compared in a group of patients with fecal incontinence. The incidence of anismus in patients with fecal incontinence is considerable, and the therapeutic approach in these patients should be modified.

Many women with FI complaints refer soiling, and this leads us to believe that the soiling is only related to the sphincter hypotonia. But what is realized is that soiling may be present in patients with normal pressures and with FI complaints as a manifestation of anismus. Thus, it is important to identify this condition.

Conflicts of interest

The authors declare no conflicts of interest.

REFERENCES

1. Lazarescu A, Turnbull GK, Vanner S. Investigating and treating fecal incontinence: When and How. *Can J Gastroenterol.* 2008;23:301–8.
2. Novi JM, Mulvihill BHK, Morgan MA. Combined anal sphincteroplasty and perineal reconstruction for fecal incontinence in women. *JAOA.* 2009;109:234–6.
3. Bharucha AE, Wald A, Encke P, Rao S. Functional anorectal disorders. *Gastroenterology.* 2006;130:1510–8 [Review].
4. Hilfiker PR, Debatin JF, Schwizer W, Schoenenberger AW, Fried M, Marincek B. Defecography: depiction of anorectal anatomy and pathology. *J Comput Assist Tomogr.* 1998;22:749–55.
5. Roos JE, Weishaupt D, Wildermuth S, Willmann JK, Marincek B, Hilfiker PR. Experience of 4 years with open MR defecography: pictorial review of anorectal anatomy and disease. *Radiographics.* 2002;22:817–32.
6. Baldez JR. Achados Manométricos nas Doenças Ano Reto Cólicas. *Rev bras Coloproct.* 2004;24:10–4.
7. Dragsted J, Gammelgaard J. Endoluminal ultrasonic scanning in the evaluation of rectal cancer: a preliminary report of 13 cases. *Gastrointest Radiol.* 1983;8:367–9.
8. Law PJ, Bartram CI. Anal endosonography: technique and normal anatomy. *Gastrointest Radiol.* 1989;14:349–53 [Review].
9. Tjandra JJ, Milsom JW, Stolfi VM, Lavery I, Oakley J, Church J, et al. Endoluminal ultrasound defines anatomy of the anal canal and pelvic floor. *Dis Colon Rectum.* 1992;35:465–70.
10. Gold DM, Bartram CI, Halligan S, Humphries KN, Kamm MA, Kmiot WA. Three-dimensional endoanal sonography in assessing anal canal injury. *Br J Surg.* 1999;86:365–70.
11. Christensen AF, Nielsen MB, Engelholm SA, Roed H, Svendsen LB, Christensen H. Three-dimensional anal endosonography may improve staging of anal cancer compared with two-dimensional endosonography. *Dis Colon Rectum.* 2004;47:341–5.
12. Regadas SMM, Regadas FSP, Rodrigues LV, Silva FR, Lima DMR, Regadas-Filho FSP. Importância do Ultra-som Tridimensional na Avaliação Anorretal. *Arq Gastroenterol.* 2005;42:226–32.
13. Etienney I, de Parades V. Three-dimensional endoanal ultrasonography in daily proctological practice. *Clin Res Hepatol Gastroenterol.* 2011;35:260–70.
14. Beeets-Tan RG, Morren GL, Beets GL, Kessels AC, Naggar ELK, Lemaire E, et al. Measurement of anal sphincter muscle: endoanal US endoanal MR imaging, or phase-array MR imaging? A study healthy volunteers. *Radiology.* 2001;220:81–9.
15. West RL, Dwarkasing S, Briel JW, Hansen BE, Hussain SM, Schouten WR, et al. Can three-dimensional endoanal ultrasonography detect external and sphincter atrophy? A comparison with endoanal magnetic resonance imaging. *Int J Colorectal Dis.* 2005;20:328–33.
16. Siegel S, Castellan N. *Nonparametric statistics for the behavioral sciences.* 2nd ed. New York: McGraw-Hill; 1988. p. 284–5.
17. Fleis Joseph L. *Statistical methods for rates and proportions.* New York: John Wiley; 1981. p. 212–36.
18. Jorge JMN, Wexner SD. Etiology and management of fecal incontinence. *Dis Colon Rectum.* 1993;36:77–97 [Review].
19. Gordon PH, Nivatvongs S. *Principles and practice of surgery for the colon, rectum and anus.* 3th ed. New York: Informa Healthcare; 2007. p. 293–332.

20. Aspiroz F. Guía práctica sobre incontinencia anal. *Rev Esp Enferm Dig.* 2003;95:722–6.
21. Zetterström JP, Mellgren A, Madoff RD, Kim DG, Wong WD. Perineal Body measurement improves evaluation of anterior sphincter lesions during endoanal ultrasonography. *Dis Colon Rectum.* 1998;41:705–13.
22. Sentovich SM, Blatchford GJ, Rivela LJ, Lin K, Thorson AG, Christensen MA. Diagnosing anal sphincter injury with transanal ultrasound and manometry. *Dis Colon Rectum.* 1997;40:1430–4.
23. Kleinübing H Jr, Jannini JF, Malafaia O, Brenner S, Pinho TM. Transperineal ultrasonography: new method to image the anorectal region. *Dis Colon Rectum.* 2000;43:1572–4.
24. Williams AB, Bartram CI, Halligan S, Marshall MM, Nicholls RJ, Kmiot WA. Multiplanar anal endosonography – normal anal canal anatomy. *Colorectal Dis.* 2001 May;3:169–74.
25. Williams AB, Bartram CI, Halligan S, Marshall MM, Nicholls RJ, Kmiot WA. Endosonographic anatomy of the normal anal canal compared with endocoil magnetic resonance imaging. *Dis Colon Rectum.* 2002;45:176–83.
26. Murad-Regadas SM, Regadas FS, Rodrigues LV, Souza MH, Lima DM, Silva FR, et al. A novel procedure to assess anismus using three-dimensional dynamic anal ultrasonography. *Colorectal Dis.* 2007;9:159–65.
27. Azpiroz F, Enck P, Whitehead WE. Anorectal functional testing: review of collective experience. *Am J Gastroenterol.* 2002;97:232–40.