



## Original Article

# Interobserver variability in histological diagnosis of serrated colorectal polyps



Rosimeri Kuhl Svoboda Baldin<sup>a,\*</sup>, Raul Alberto Anselmi Júnior<sup>b</sup>, Marina Azevedo<sup>b</sup>, Ana Paula Martins Sebastião<sup>a,c</sup>, Mário Montemor<sup>d</sup>, Luiz Fernando Tullio<sup>e</sup>, Luiz Felipe de Paula Soares<sup>e</sup>, Lúcia de Noronha<sup>a,b</sup>

<sup>a</sup> Universidade Federal do Paraná (UFPR), Curitiba, PR, Brazil

<sup>b</sup> Pontifícia Universidade Católica do Paraná (PUCPR), Curitiba, PR, Brazil

<sup>c</sup> Universidade Positivo, Curitiba, PR, Brazil

<sup>d</sup> Universidade Estadual de Ponta Grossa, Ponta Grossa, PR, Brazil

<sup>e</sup> Service of Endoscopy, Hospital Santa Cruz, Curitiba, PR, Brazil

## ARTICLE INFO

## Article history:

Received 31 March 2015

Accepted 8 June 2015

Available online 2 October 2015

## Keywords:

Colon

Polyps

Serrated

## ABSTRACT

**Objectives:** To compare the interobserver variability in the diagnostic of serrated and non-serrated adenomatous lesions and hyperplastic polyps of colon between two groups of pathologists.

**Methods:** 310 colorectal polyps were studied, with histological diagnoses established by a group of pathologists comprising three general pathologists for initial diagnosis, and two gastrointestinal pathologists for expert diagnosis.

**Results:** High interobserver variability was observed in the diagnosis of serrated polyps, when comparing the initial diagnosis with the expert diagnosis ( $\kappa=0.102$ ). For the majority of both traditional serrated adenomas and sessile serrated adenomas (27/31), a diagnosis of hyperplastic polyps was established at the initial diagnosis.

**Conclusions:** Poor agreement was observed in the diagnosis of serrated polyps between the two groups of pathologists. The accuracy in the diagnosis of these lesions is essential for the prevention of colorectal cancer.

© 2015 Sociedade Brasileira de Coloproctologia. Published by Elsevier Editora Ltda. All rights reserved.

## Variabilidade interobservador no diagnóstico histológico de pólipos colorretais serrilhados

## RESUMO

**Objetivo:** Comparar a variabilidade interobservador dos diagnósticos das lesões adenomatosas serrilhadas e não serrilhadas e pólipos hiperplásicos do cólon entre dois comitês de patologistas.

## Palavras-chave:

Cólon

Pólipos

Serrilhado

\* Corresponding author.

E-mails: [rosimeribaldin@gmail.com](mailto:rosimeribaldin@gmail.com), [rksbaldin@ufpr.br](mailto:rksbaldin@ufpr.br) (R.K.S. Baldin).

<http://dx.doi.org/10.1016/j.jcol.2015.06.008>

2237-9363/© 2015 Sociedade Brasileira de Coloproctologia. Published by Elsevier Editora Ltda. All rights reserved.

**Métodos:** Foram estudados 310 pólipos colorretais, diagnosticados histologicamente por um comitê de patologia, composto por três patologistas gerais para o diagnóstico inicial e por dois patologistas gastrointestinais para o diagnóstico dos especialistas.

**Resultados:** Houve alta variabilidade interobservador no diagnóstico dos pólipos serrilhados, ao serem comparados o diagnóstico inicial com o diagnóstico dos especialistas ( $\kappa = 0,102$ ). A maioria das lesões adenomatosas serrilhadas sésseis e tradicionais (27/31) foi diagnosticada pelo diagnóstico inicial como pólipos hiperplásicos.

**Conclusões:** Houve baixa concordância no diagnóstico dos pólipos serrilhados colorretais entre os dois comitês de patologistas. A acurácia desses diagnósticos é fundamental para a prevenção do carcinoma colorretal.

© 2015 Sociedade Brasileira de Coloproctologia. Publicado por Elsevier Editora Ltda. Todos os direitos reservados.

## Introduction

Serrated polyps (SP), which represent 20% of colorectal polyps, may be precursors of 15–20% of colorectal cancers.<sup>1</sup>

The histological diagnosis of SP has been improved since 1990, from the new concepts of Longacre and Fenoglio-Preiser until the present day, being natural that difficulties arise due to changes which had occurred; however, the lack of precision jeopardizes the patient follow-up and undervalues the method.<sup>2</sup>

The current classification and nomenclature of colorectal SP recommended by the World Health Organization<sup>3</sup> subdivide colorectal serrated polyps (SP) into three groups:

- Hyperplastic polyps (HP)
- Adenomas/sessile serrated polyps (A/SSP)
  - With cytological dysplasia
  - Without cytological dysplasia
- Traditional serrated adenomas (TSA)

At first, hyperplastic polyps (HP), considered as benign conditions, did not require follow-up. Usually the endoscopists did not bother to carry out resection of minor HP-like injuries, thanks to the absence of the risk of malignancy. But currently, in the face of the known risk of malignant transformation of adenomas/serrated sessile polyps (A/SSP), especially those in the right colon and in the face of difficulties of differentiating between colorectal SP through colonoscopy, removal and histological examination of these lesions are mandatory.<sup>4-6</sup>

Unknown factors lead to changes in the location of the cryptal proliferative zone, as well as in crypts' anchoring in these lesions, with variants of histological appearance.<sup>7</sup> What primarily allows us to distinguish between the different categories of polyps are some architectural changes resulting of these proliferative abnormalities.

According to some authors,<sup>8</sup> a variation occurs at the location of the proliferative zone, which usually is located in the lower third of crypts, and the mature cells are pushed toward the intestinal lumen.

In HP patients, the proliferative zone is maintained in the lower portion of the crypt, occupying more than half of the length of the crypt. Cells continue to mature toward the surface; but due to a late apoptosis, these cells tend to pile up, forming serrated structures.

In A/PSS, the proliferative zone moves toward the lateral aspect of the crypt. This allows that mature cells move both toward the intestinal lumen and to the base of the crypt, which becomes enlarged and distorted, because the muscularis mucosae blocks the cryptal growth.

In cases of traditional serrated adenoma (TSA), the proliferative zone is located in small ectopic crypts that develop at the side of the original crypt. These mini-crypts develop a complex pattern of growth.

## Objective

To compare the interobserver variability of diagnoses of large bowel serrated and non-serrated adenomatous polyps and of HP, in particular in the SP group (HP, A/PSS and TSA) between two groups of pathologists.

## Methods

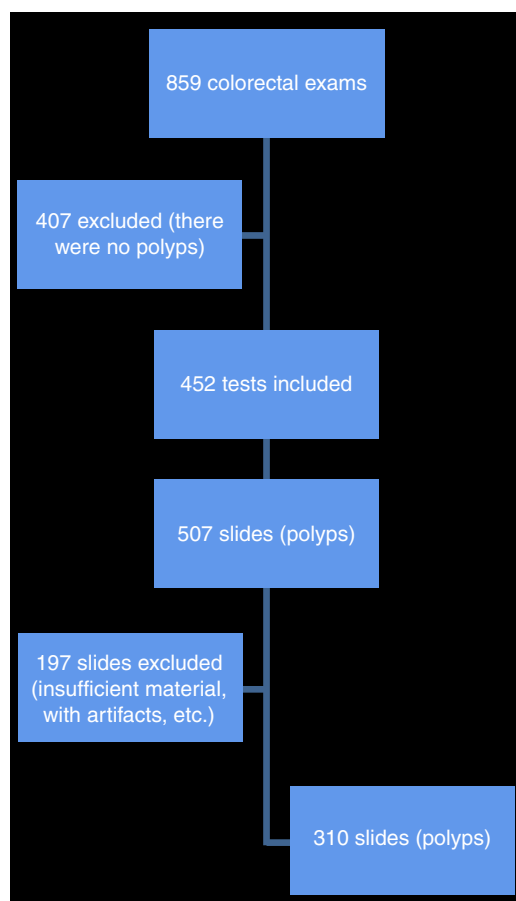
The cases were selected from files of reports from the Service of Pathology of Hospital Santa Cruz, Curitiba-Pr. Histological slides from collected polyps by colonoscopy during 2008 and stained with hematoxylin-eosin (H&E) were used.

This project was approved by the Ethics Committee for Research in Human Beings of HC-UFPR, according to the tasks set out in Resolution CNS 466/2012 and in Operational Norm No. 001/2013 of CNS under opinion No. 820,432.

We collected clinical data, including patient age, gender, polyp location in the colon (right, left or sigmoid), presence of single or multiple polyps, association with cancer, polyp size at endoscopy, polyp appearance (sessile or pedunculated), initial pathological diagnosis (by the Department of Pathology of Hospital Santa Cruz, composed of three general pathologists) and expert diagnosis (two gastrointestinal pathologists).

Inclusion criteria (eligible cases):

- polyps collected by colonoscopy procedure performed in patients at the Service of Endoscopy, Santa Cruz Hospital, in 2008.
- serrated and non-serrated adenomatous colorectal polyps and HP.
- absence of sample fragmentation.
- absence of fulguration artifacts.
- non-scarcity of sample.



**Fig. 1 – Sequential flowchart of collection of cases of colorectal polyps.**

- absence of inflammatory polyps.
- absence of diagnostic disagreement among general pathologists.
- absence of diagnostic disagreement among gastrointestinal pathologists.

The sequence of collection of cases from the beginning till attaining the study “n” can be seen in Fig. 1.

A reinterpretation of the slides was carried out by two doctors with gastrointestinal pathology specialization blinded for the diagnosis initially established by general pathologists.

For statistical evaluation, SP were divided into two groups: the first composed by HP and the second by serrated adenomatous lesions (SAL) comprising A/PSS and TSA, since these last conditions clearly demonstrate potential for malignancy.<sup>9</sup>

### Statistical analysis

To evaluate the agreement between diagnoses of paired evaluators, Cohen’s Kappa coefficient was estimated.<sup>10</sup> For a comparison of the evaluators regarding the likelihood of diagnosis, the binomial test was considered. *p*-Values <0.05 were considered statistically significant.

**Table 1 – Clinical and endoscopic data of colorectal polyps in this study.**

Polyps, total (n)	310
Total number of patients (or of colonoscopy procedures)	240
Age of polyp carriers	Minimum 19 years Maximum 91 years Median 60 years
Gender	129 women 181 men
Aspect of the polyp	281 sessile (90.6%) 29 with pedicle (9.4%)
Localization	135 on the right side (right and transverse colon) 175 on the left side (left colon and sigmoid)
Single or multiple	113 single polyps 197 multiple polyps
Size	2–30 mm >10 mm (22%) 6–9 mm (11%) 4–5 mm (43%) 2–3 mm (24%)

## Results

310 cases of colorectal polyps from a total of 240 patients (some with more than one polyp) were considered eligible for the study. Of the total number of cases, 129 polyps in women and 181 in men were observed. The median age was 60 years, ranging from 19 to 91 years of age.

As to the endoscopic form of the polyp, 29 polyps (9.4%) were classified by the endoscopist as pedicled polyps, and 281 (90.6%) as sessile polyps. Endoscopically, the polyp size ranged from 2 to 30 mm in its largest diameter, with a mean of 6.5 mm per polyp, with the following distribution: polyps  $\geq$ 10 mm, 22% of cases; 6–9 mm, 11%; 4–5 mm, 43%; and 2–3 mm, 24%. Polyps <2 mm were not removed.

As for the location in the colon, 135 polyps were located on the right (ascending and transverse colon) and 175 on the left (descending and sigmoid colon). At endoscopy, 113 single polyps and 197 multiple polyps were found. Thirteen cases of polyp-associated carcinoma were diagnosed.

Table 1 shows partially the result of data tabulation of clinical and endoscopic data obtained.

Table 2 shows how was the distribution of diagnoses by the pathology committee (initial diagnosis) and by gastrointestinal pathologists (expert diagnosis).

### Serrated polyps

The 31 SAL diagnosed by gastrointestinal pathologists were previously distributed by the pathology committee as follows: 27 HP (87.1% of 31 polyps), 1 TA-LGD (3.2% of 31 polyps) and 3 SAL (9.7% of 31 polyps).

Fig. 2 shows how the pathology committee diagnosed those serrated polyps diagnosed by gastrointestinal pathologists.

**Table 2 – Histological diagnosis of 310 colorectal polyps in this study, established by a group of pathology and by experts in gastrointestinal pathology.**

	Initial Dx (group)	Expert Dx
HP	87 (28.1%)	46 (14.8%)
SAL	3 (0.9%)	31 (10%)
TA-LGD	172 (55.5%)	142 (45.8%)
TA-HGD	9 (2.9%)	5 (1.6%)
TVA-LGD	22 (7.1%)	46 (14.8%)
TVA-HGD	16 (5.2%)	4 (1.3%)
VA-LGD	0 (0%)	25 (8.1%)
VA-HGD	1 (0.3%)	11 (3.5%)

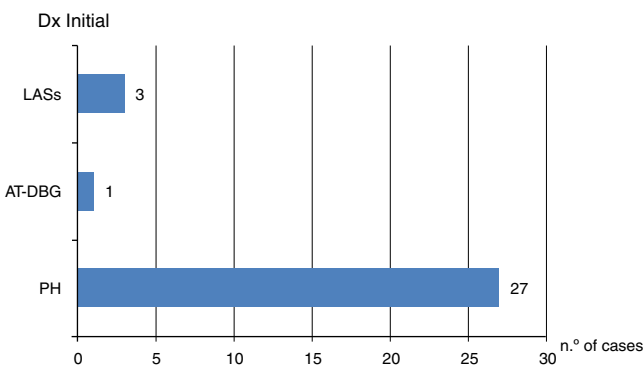
HP, hyperplastic polyp; SAL, serrated adenomatous lesion (adenoma/sessile serrated polyp and traditional serrated adenoma); TA-LGD, tubular adenoma with low-grade dysplasia; TA-HGD, tubular adenoma with high-grade dysplasia; TVA-LGD, tubule-villous adenoma with low-grade dysplasia; TVA-HGD, tubule-villous adenoma with high-grade dysplasia; VA-LGD, villous adenoma with low-grade dysplasia; VA-HGD, villous adenoma with high-grade dysplasia; initial Dx (group), initial diagnosis made by the pathology committee; expert Dx, diagnosis made by two expert pathologists in gastrointestinal pathology; SAL values were highlighted.

**Evaluation of agreement between initial and expert diagnoses**

We tested the null hypothesis of non-correlation between initial diagnostic evaluations and of the diagnosis of expert pathologists versus an alternative hypothesis of agreement. Table 3 presents the results obtained in the study.

The Cohen’s kappa coefficient was estimated at 0.102. The statistical test results indicated non-rejection of the absence of an agreement hypothesis between the two groups of evaluators ( $p = 0.151$ ). Thus, our study does not reject the hypothesis that the non-agreement has been a product of chance.

Additionally, we tested a null hypothesis for the probability that a diagnosis of SAL is equal for both groups of evaluators versus an alternative hypothesis of different probabilities.



**Fig. 2 – Initial diagnosis of 31 cases of serrated colorectal polyps evaluated by gastrointestinal pathologists as being serrated adenomatous lesions. Initial Dx, diagnostic of the pathology group; SALS, serrated adenomatous lesions (adenoma/sessile serrated polyp and traditional serrated adenoma); TA-LGD, tubular adenoma with low-grade dysplasia; HP, hyperplastic polyp.**

**Table 3 – Concordance of diagnostic of SAL between the initial diagnosis and that of experts.**

Expert Dx	Initial Dx		Total
	SAL	Other Dx	
SAL	2 (0.65%)	29 (9.35%)	31 (10%)
Other Dx	1 (0.32%)	278 (89.68%)	279 (90%)
Total	3 (0.97%)	307 (99.03%)	310 (100%)

Dx, diagnosis; SAL, serrated adenomatous lesion.

The test results indicated rejection of the null hypothesis ( $p < 0.001$ ). Thus, there is evidence that the expert group diagnosis has a higher probability of obtaining a classification of SAL (10% of sample cases) in comparison with the initial diagnosis (0.97% of sample cases).

**Discussion**

The recognition of the existence of a serrated carcinogenesis pathway makes it important to standardize the histological diagnosis of SP, as the follow-up in patients with a polyp will depend on its histologic classification.<sup>1</sup>

To describe the agreement between observers, we used the statistic index kappa (k), which uses mathematical coefficients to adjust the agreement to chance. In this index, a value close to 0 indicates an agreement similar to that which would be expected by chance. k values <0.21, 0.21–0.40, 0.41–0.60, 0.61–0.80 and >0.80 represent poor, weak, moderate, strong, and very strong interobserver agreement, respectively.<sup>11</sup>

In a review of 20 histological sections of colorectal polyps performed for 20 randomly chosen general pathologists, a correct diagnosis of adenoma was identified in 94% of the readings; on the other hand, for a correct diagnosis of cases with high-grade dysplasia, only 47% of the readings were correct. HP was correctly diagnosed in 75% of cases. The authors of that review concluded for the occurrence of discrepancy mainly in the diagnosis of high-grade dysplasia.<sup>12</sup>

From the colonic SP group, a greater interobserver variability is expected, as this is a relatively new concept among pathologists, and which has been perfected over time. In this study, the agreement of a diagnosis of serrated polyps between the pathology committee (initial diagnosis) and expert pathologists resulted in a kappa value = 0.102 (poor), showing a very low correlation between these two groups. A diagnosis of LSA was established in 0.97% of cases by the committee (first diagnosis) and in 10% of cases by gastrointestinal pathologists, showing that the latter were more likely to establish a diagnosis of SAL versus general pathologists.

In 2009, investigators carried out an assessment of 40 proximal colonic polyps (size  $\geq 5$  mm) removed in 2001 and originally interpreted as HP by general pathologists at Indiana University, and later revised by three gastrointestinal pathologists.<sup>13</sup> In this review, A/PSS diagnoses were established in 85%, 43% and 30% of these polyps by each gastrointestinal pathologist (kappa=0.16). The authors concluded that many polyps diagnosed as being hyperplastic conditions in 2001 were considered as A/SSP by gastrointestinal pathologists in 2007. But it was also noted a large

interobserver variation (little agreement on the diagnosis) among pathologists, similar to the variety found in our study: from 31 SAL diagnosed by gastrointestinal pathologists, 27 (87.1%) were initially classified as HP by the pathology committee.

Other researchers<sup>14</sup> evaluated 60 cases of polyps diagnosed by 4 gastrointestinal pathologists, with classification of colorectal polyps in 5 categories: serrated adenoma, hyperplastic polyp, conventional adenoma, mixed polyp, and other serrated polyps. A complete concordance occurred only in 40% of cases. The *k* value for observers was 0.49. The *k* value for the diagnosis of serrated adenoma versus all other polyps was 0.38. The authors concluded that gastrointestinal pathologists achieved a moderate agreement in the diagnosis of colorectal serrated polyps, with weak agreement in the diagnosis of serrated adenomas.

Some authors<sup>1</sup> applied an online questionnaire with 20 colorectal polyps, containing 3 images of each lesion, to 168 pathologists, in order to test the diagnostic variability, especially in distinguishing the two precursor lesions of the serrated pathway for colorectal cancer, TSA and A/PSS, compared to HP and tubular-villous adenomas (TVA). The correct responses for A/PSS (54%) and TSA (44%) were significantly lower than those responses for TVA (90%) and HP (80%). The authors mention that TSA could be confused with TVA in those cases in which the serrated architecture was less pronounced, and in the face of a prominent nuclear pseudo-stratification and hyperchromasia.

Some considerations can be proposed with respect to the growing curve of diagnoses of A/PSS by the pathology committee in relation to that of gastrointestinal pathologists:

- The diagnosis established by the committee was carried out earlier (2008), and the expert diagnosis was more recently established (2013) and therefore more updated.
- The greater experience and deeper understanding of criteria for the diagnosis of serrated polyps among gastrointestinal pathologists.

Therefore, we can conclude that, between the two groups studied, the interobserver variability in the diagnosis of colorectal serrated polyps was high, possibly due to differences in the dates of diagnoses, suspicion level, and a better knowledge of morphological characteristics by gastrointestinal pathologists. The relevance of this issue is important, because the follow-up depends solely on the histological diagnosis. Increasing the quality of prevention of colorectal cancer in the community can be achieved with a more consistent

diagnosis of these polyps. The value of this study is the sense of self-criticism that boosted their authors.

## Conflicts of interest

The authors declare no conflicts of interest.

## REFERENCES

1. Glatz K, Pritt B, Glatz D, Hartmann A, O'Brien MJ, Blaszyk H. Internet-based assessment of observer variability in the diagnosis of serrated colorectal polyps. *Am J Clin Pathol.* 2007;127:938–45.
2. Foucar E. Error identification a surgical pathology dilemma. *Am J Surg Pathol.* 1998;22:1–5.
3. Rex DK, Ahnen DJ, Baron JA, Batts KP, Burke CA, Burt RW, et al. Serrated lesions of the colorectum: review and recommendations from an expert panel. *Am J Gastroenterol.* 2012;107:1315–29.
4. Lieberman DA, Prindiville S, Weiss DG, Willett W, VA Cooperative Study Group 380. Risk factors for advanced colonic neoplasia and hyperplastic polyps in asymptomatic individuals. *JAMA.* 2003;290:2959–67.
5. Jass JR, Baker K, Zlobec I, Higuchi T, Barker M, Buchanan D, et al. Advanced colorectal polyps with the molecular and morphological features of serrated polyps and adenomas: concept of a 'fusion' pathway to colorectal cancer. *Histopathology.* 2006;49:121–31.
6. O'Brien MJ. Hyperplastic and serrated polyps of the colorectum. *Gastroenterol Clin N Am.* 2007;36:947–68.
7. Higuchi T, Jass JR. My approach to serrated polyps of the colorectum. *J Clin Pathol.* 2004;57:682–6.
8. Snover DC. Update on the serrated pathway to colorectal carcinoma. *Hum Pathol.* 2011;42:1–10.
9. Christophe R, David GH, Ian SB, Barbara AL, Vicki LJW. Serrated polyps of the large intestine: current understanding of diagnosis, pathogenesis, and clinical management. *J Gastroenterol.* 2013;48:287–302.
10. Landis JR, Koch GG. The measurement of observer agreement for categorical data. *Biometrics.* 1977;33:159–74.
11. Sim J, Wright CC. The kappa statistic in reliability studies: use, interpretation, and sample size requirements. *Phys Ther.* 2005;85:257–68.
12. Rex DR, Alikhan M, Cummings O, Ulbright TM. Accuracy of pathologic interpretation of colorectal polyps by general pathologists in community practice. *Gastrointest Endosc.* 1999;50:468–74.
13. Khalid O, Radaideh S, Cummings OW, O'Brien MJ, Goldblum JR, Rex DK. Reinterpretation of histology of proximal colon polyps called hyperplastic in 2001. *World J Gastroenterol.* 2009;15:3767–70.
14. Wong NA, Hunt LP, Novelli MR, Shepherd NA, Warren BF. Observer agreement in the diagnosis of serrated polyps of the large bowel. *Histopathology.* 2009;55:63–6.