



Original Article

Evaluation of the inflammatory response induced by different materials in the treatment of perianal fistulas: experimental study in rats



Mariana Ocampos Galvão^a, Carlos Henrique Marques dos Santos^{b,*},
Gustavo Ribeiro Falcão^b

^a Universidade Anhanguera Uniderp, Campo Grande, MS, Brazil

^b Universidade Federal de Mato Grosso do Sul (UFMS), Campo Grande, MS, Brazil

ARTICLE INFO

Article history:

Received 26 April 2015

Accepted 28 August 2015

Available online 23 December 2015

Keywords:

Fistula

Anal canal

Rats

Seton

ABSTRACT

The medical literature has no study evaluating the effectiveness of different materials used as setons in the treatment of perianal fistulas; therefore, there is no evidence of availability of a more effective material than others for this purpose.

Objective: To evaluate the inflammatory response induced by different materials used as seton in perianal fistulas in rats.

Method: Thirty Wistar rats, which were initially submitted for the construction of a perianal fistula by passing transfixing steel wire into the anal canal, were used. The rats were kept for 30 days; after this period, and with confirmation of the formation of the perianal fistula, the setons were introduced (10 rats – cotton thread #0; 10 rats – rubber; and 10 rats – silastic); after 30 days the animals were euthanized, and then the area of the fistula repaired by the seton was resected, and the material retrieved was submitted to histological analysis. The results were analyzed statistically.

Results: The mean degree of inflammatory process observed by histological analysis after 30 days was 2.3 for the cotton group; 1 for the rubber group; and 1.2 for the silastic group.

Conclusion: A greater inflammatory response was observed in the group treated with a cotton seton. In the remaining groups, a lower inflammatory response, with equal intensity for rubber and silastic-treated rats, was noted.

© 2015 Sociedade Brasileira de Coloproctologia. Published by Elsevier Editora Ltda. All rights reserved.

* Corresponding author.

E-mail: chenriquems@yahoo.com.br (C.H.M. dos Santos).

<http://dx.doi.org/10.1016/j.jcol.2015.08.008>

2237-9363/© 2015 Sociedade Brasileira de Coloproctologia. Published by Elsevier Editora Ltda. All rights reserved.

Avaliação da resposta inflamatória produzida por diferentes materiais utilizados como sedenho no tratamento de fístulas perianais: estudo experimental em ratos

R E S U M O

Palavras-chave:

Fístula
Canal anal
Ratos
Sedenho

Não foram encontrados na literatura médica estudos que avaliassem a eficácia dos diferentes materiais utilizados como sedenho no tratamento de fístulas perianais, portanto, não havendo evidências de que haja um material mais eficaz do que outro para esta finalidade. **Objetivo:** avaliar a resposta inflamatória induzida por diferentes materiais utilizados como sedenhs em fístulas perianais em ratos.

Método: foram utilizados 30 ratos Wistar, os quais foram inicialmente submetidos à criação de fístula perianal pela passagem de fio de aço transfixante no canal anal, mantido por 30 dias; após este período, confirmada a formação de fístula perianal, foram introduzidos os sedenhs (10 ratos – fio de algodão zero, 10 ratos – borracha e 10 ratos – silastic); após 30 dias os animais foram submetidos a eutanásia, ressecando-se a área da fístula reparada pelo sedenho, submetendo-se este material à análise histológica. Os resultados foram submetidos a tratamento estatístico.

Resultados: a média do grau de processo inflamatório observado pela análise histológica após 30 dias foi de 2,3 para o grupo de sedenho de algodão; de 1 para o grupo de sedenho de borracha e 1,2 para o grupo silastic.

Conclusão: Houve maior resposta inflamatória no grupo tratado com sedenho de algodão. Houve resposta inflamatória menor e de igual intensidade nos animais tratados por sedenho de borracha e silastic.

© 2015 Sociedade Brasileira de Coloproctologia. Publicado por Elsevier Editora Ltda. Todos os direitos reservados.

Introduction

Perianal fistula is a condition characterized by an abnormal communication between the intestinal epithelium (anal canal or rectum) and skin, its primary signal being a foul-odor, pious/blood tinged drainage through its perianal external os. This is a relatively common condition seen in the coloproctology office, and its real incidence is unknown, but this condition occurs predominantly in males. Perianal fistulas can occur at any age, with an incidence most commonly between the third and fifth decades of life and rarely from the sixth decade.

The optimal management of perianal fistulas remains a matter relatively controversial, because there is no single technique that can provide a high healing rate without complications, such as fecal incontinence. It is known that fistulotomy is currently one of the most widely employed techniques worldwide for superficial fistulas, for example, intersphincteric and low transsphincteric fistulas. In these situations, around 95% of cases are resolved, with low risk of fecal incontinence, of approximately 5% – figures considered very good for this scenario.¹

The major drawback in the care of perianal fistulas relates to the more complex ones, such as high transsphincteric, suprasphincteric and extrasphincteric fistulas – situations in which a fistulectomy would lead to unacceptable levels of fecal incontinence, due to the sphincteric injury produced. For these types of fistulas, many techniques have been described and used with reasonable results, but never reaching those outcomes with fistulotomy. Techniques such as mucosal flap advancement, LIFT (ligation of intersphincteric fistula tract),

and the use of glues and plugs, are being used worldwide with resolution rates ranging from 20% to 85%.²

A resource used for many years for the most complex cases consists in the placement of setons, with multiple objectives. This resource can simply be used for maintaining an open fistula, while avoiding the formation of abscesses, as in the case of Crohn's disease. The seton also functions as a single treatment for fistula, considering that, as a foreign body, there is a tendency for its elimination by the body, with consequent formation of scar tissue along the fistula tract and wound healing. Another purpose of the use of a seton is the induction of more fibrosis, producing a well-defined path with thick walls for further surgical treatment, for example with the LIFT technique. With LIFT, most surgeons apply a seton between 6 and 8 weeks before the procedure itself.³

There is much speculation among coloproctologists as to what is the best seton material to be used for different purposes. Some advocate that the best material would be silastic, thanks to its very interesting characteristics of smoothness, pliability and relative resilience. However, rubber seems to have the same characteristics, but at a lower cost. Another widely used material, especially in public services, where silastic is not always available, is the cotton thread, a material also very flexible and hard-wearing, but often criticized for being a multifilament device, thus capable of inducing an increased production of pus, a quite unpleasant nuisance for patients.

The fact is that such analyzes, although very relevant, are only in the field of assumptions, since there is no study in the literature comparing such materials for a proper investigation of the effectiveness of the various scenarios in which setons

may be used. Thus, it is critical to study the action of these materials, and the aim of this study is to carry out such an analysis and comparison.

Objective

To evaluate the inflammatory response induced by the different materials used as setons in perianal fistulas in rats.

Method

The study was approved by the Ethics Committee on Animal Use (CEUA) of the Federal University of Mato Grosso do Sul (UFMS).

A total of 30 *Rattus norvegicus*, Wistar albino strain, adult male rats with an average weight of 300 g were used in this study. The animals were kept in the experimental sector of Central Animal Facility, UFMS, and all required ethical standards were met. Water and *ad libitum* feeding was provided, with daily exchange of food and water and cleaning of cages.

The animals were anesthetized with intraperitoneal ketamine and xylazine combined in the same syringe with 1 ml solution of 10% ketamine and 1 ml of 2% xylazine, with infusion of 0.1 ml of solution per 100 g body weight.

After anesthesia, the animals were kept in a supine position with their four extremities in abduction. The entire surgical procedure was performed under aseptic and antiseptic conditions in the operated area.

Initially, a perianal fistula construction was made in all animals through the passage of a needled steel wire #5 (ACIFLEX®) with transfixion of the perianal area; the wire was inserted into the pectineal line, crossing the anal sphincter with the needle exiting at a point 1 cm lateral to the left anal margin. Then, the operator sectioned the steel wire and secured it by loosely rotating its ends, with no compression of the sphincter (Fig. 1).

The rats were kept under the conditions described above for 30 days, and after this period, all animals were again anesthetized by the technique described above, with replacement of the steel wire by a seton, with the following distribution:

- Group A: 10 animals with cotton #0 seton
- Group B: 10 animals with rubber seton
- Group C: 10 animals with silastic seton

All setons were tied loosely and with no sphincteric compression, and were thus kept for another 30 days. The outer portion of each seton, which was not in contact with the fistula, was covered with braided steel wire, so that the rat could not remove it (Figs. 2-4). After this period of time, the animals were euthanized with an intracardiac injection of sodium thiopental, after being anesthetized by the technique previously described. After the euthanasia, the area containing the fistula and the seton was resected *en bloc* and the seton was then removed, after identification of the vials intended for reception of the material, which was maintained in a 10% solution of formaldehyde for subsequent histological analysis.

The resected specimens were then subjected to 4- μ m cuts and then stained with hematoxylin and eosin; mounted slides

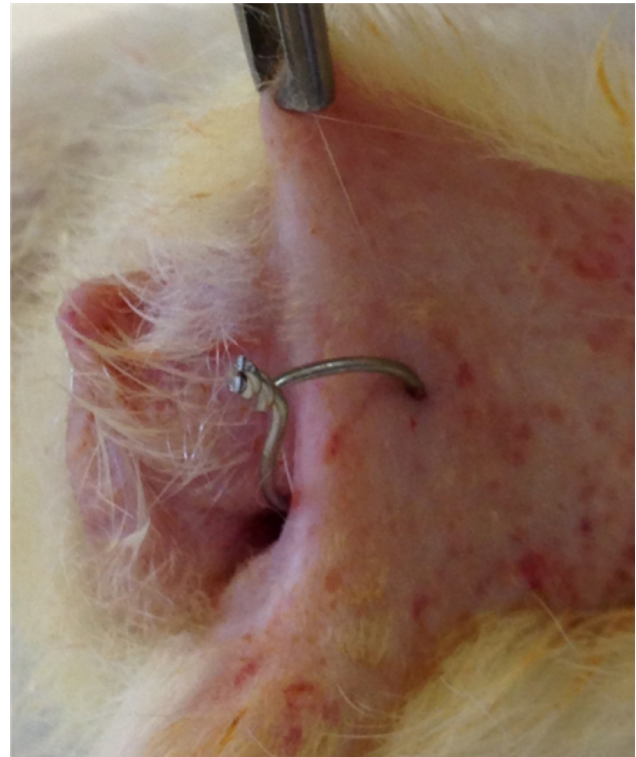


Fig. 1 – Perianal region after the passage of steel wire for making a fistula.

were analyzed by an experienced pathologist using an Eclipse E200 microscope at 100 \times and 400 \times .

The observed inflammatory response was classified into grades, according to the greater or lesser presence of inflammatory cells:

- Grade 0: no inflammatory response
- Grade 1: mild inflammatory response, with low cell density present in up to 25% of the analyzed area

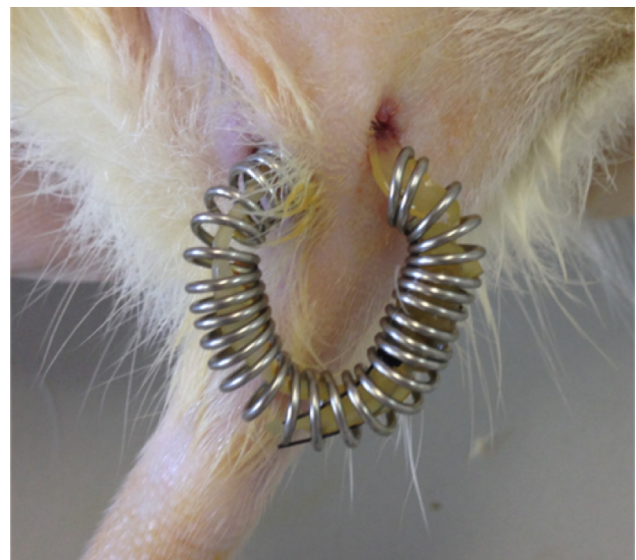

Fig. 2 – Rubber seton in position, only externally coated with a metallic spiral to prevent its removal.

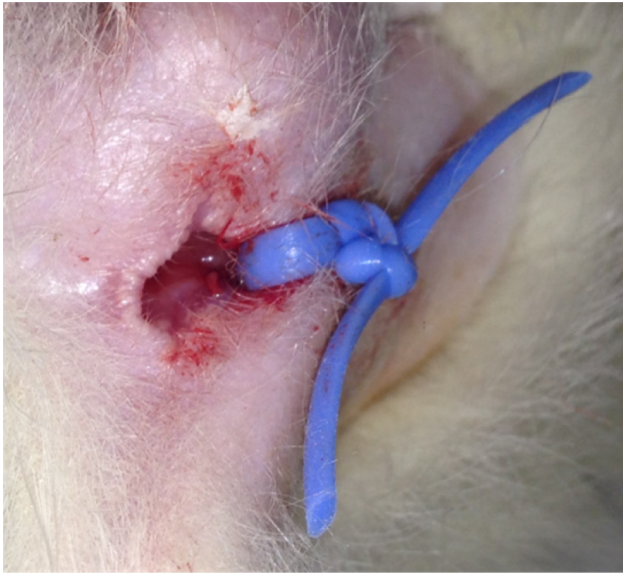


Fig. 3 – Silastic seton in position, before a metallic coating application.

- Grade 2: moderate inflammatory response, with medium cell density present in 26–75% of the analyzed area
- Grade 3: severe inflammatory response, with high cell density in over 75% of the analyzed area

In the statistical analysis of the results, the Kruskal-Wallis test was applied, considering as statistically significant a p -value <0.05 .

Results

In group A (cotton), three animals had a grade 1 inflammatory response, three animals were grade 2 and four animals were grade 3 (mean=2.3). In group B (rubber), all animals had a grade 1 inflammatory response (mean=1). In group C

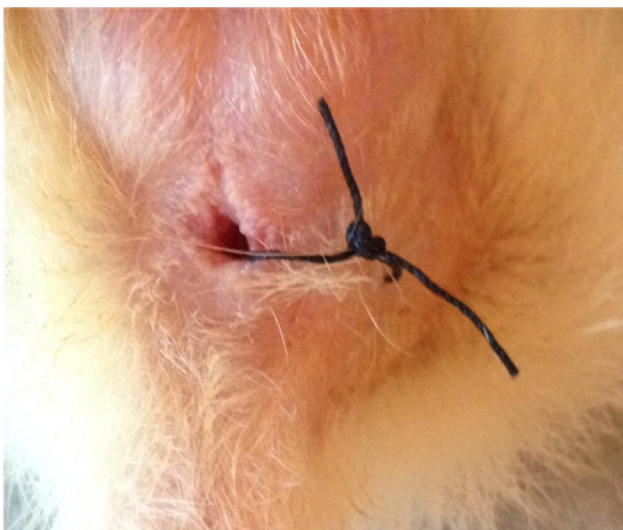

Fig. 4 – Cotton seton in position, before a metallic coating application.

Table 1 – Inflammatory response to the use of seton in the groups studied.

Rats	Grades of inflammatory response		
	Group A	Group B	Group C
1	1	1	2
2	1	1	1
3	1	1	1
4	2	1	1
5	3	1	1
6	3	1	1
7	2	1	2
8	3	1	1
9	2	1	1
10	3	1	1
Mean	2.3	1	1.2

Note: Between groups A and B, $p < 0.05$; between groups A and C, $p < 0.05$; between groups B and C, $p > 0.05$.

(silastic), only two animals had a grade 2 inflammatory response, while the others had a grade 1 answer (mean = 1.2) (Table 1).

Discussion

Recently, Subhas et al.¹ published a review of the literature analyzing the different materials used as setons in the correction of anorectal fistulas. Although this was a comprehensive review that included most of the materials used, its authors did not find a direct comparison between such products in the literature; therefore, currently it is not known whether or not there is some difference in the effectiveness of these devices.

In Proctology practice, it was observed that many practitioners have personal preferences as to the material to be used as a seton, with arguments in favor of siliconized products or rubber, because these products are potentially more comfortable for patients and also by producing less secretion, thanks to the absence of porosity. However, these potential advantages did not find a clear scientific support, as they are based only on the surgeons' personal experience and on some case reports.² Therefore, the importance of our study; but on the other hand, it does not allow a comparison of its results.

Some authors reported their experience with the use of a rubber seton (Penrose drain) with satisfactory results. In fulfilling its role as a seton, with a similar efficacy to other materials, it should be borne in mind the great advantage in the use of this product, because of its low cost and its availability in most of fistula treatment centers. Especially in developing countries, this factor is quite relevant and should be taken into consideration when choosing the material. Furthermore, rubber is an inert, very flexible, non-porous material and, in theory, it generates less purulent discharge during the time in which the seton is applied.³

About potential differences among the materials used, mostly in relation to the inflammatory reaction caused, one can choose the material, keeping in mind the objective to be achieved with the seton. In patients with Crohn's disease with complex perianal fistulas, drug treatment with anti-tumor necrosis factor alpha antibody in association with repeated

curettage of the fistula and placement of a seton is the first choice. In this particular situation, there is no interest in producing intense fibrosis, nor in obtaining an intense inflammatory response; on the contrary, the smaller this response, the better for the patient. In this scenario, the seton used should be soft, tough, and should cause little foreign body reaction, since it will remain fixed to the fistulous tract for relatively long periods.⁴ Extrapolating this to the findings in this study, the most appropriate materials to be used would be silastic and rubber (cotton being the worse option).

On the other hand, when one uses a seton aiming better definition of the fistula, with a more consistent fibrosis to assist during the surgical procedure on the fistulous tract, theoretically cotton setons best fulfill this function, since the present results demonstrated increased formation of the inflammatory process and, by inference, more fibrosis with the use of this material. This would be the case of LIFT (ligation of intersphincteric fistula tract), a technique which, although it tested yet with different seton materials, has been widely used worldwide. In this technique, the use of a seton is not an absolute condition, but most surgeons who practice LIFT advocate its use, 6–8 weeks ahead the LIFT procedure itself. The presence of a foreign body repairing the fistulous tract would lead to greater fibrosis, with improved safety in the application of sutures for the ligation of the tract.^{5,6}

Another approach to a fistula requiring the use of a seton consists in a “tight” application of this device, in order to gradually cut off the muscle contained by the fistula. This ancient technique has resulted in hugely conflicting results in the literature, especially in the face of the potential for fecal incontinence.⁷ On the other hand, the literature has not produced a direct comparison between different materials used, but it can be inferred that this factor could influence the outcome, since the presence of greater fibrosis could, in theory, fix the muscle cables, with lower rates of incontinence. Moreover, by inducing a greater inflammatory response, the procedure could lead (also theoretically) at a faster resolution of the fistula – an outcome which would benefit the patient. setons are also useful when applied loosely, preceding a definitive surgical procedure. In addition to the LIFT technique, mentioned in a previous paragraph, another time-proven surgical procedure is the skin or mucosal flap advancement. These approaches can also be performed with or without the previous use of a seton, but apparently there exists a greater tendency in favor of the use of this device.⁸ To this end, basically the seton would prepare the site to be operated, keeping it free from residues and especially from infection; thus, some authors recommend its placement already at the time of the perianal abscess drainage. With this purpose, there would be no need to induce a greater fibrosis, but simply to maintain a patent and drained tract. Thus, in such cases the soft, inert materials would be better options.

This study showed no difference between silastic and rubber in the production of the inflammatory process, when these materials are used as setons. While one must take into account the fact that ours is a solitary study, such evidence

speaks in favor of the rubber seton, thanks to its widespread availability and lower cost. Both materials (silastic and rubber) induced less inflammation *versus* cotton, but this finding in no way gives superiority to these materials, taking in account that, depending on the purpose in the use of the seton, the cotton device would be the best alternative, as already mentioned above, with respect to techniques such as LIFT, for instance. These results should serve – if not for obtaining a conclusive answer to the question about the differences between the materials analyzed, at least as a starting point for the conduction of further studies, with the aim to advance in this critical knowledge for the care of a very common and challenging disease.

Conclusion

The cotton strand induced a greater inflammatory response in comparison with silastic and rubber setons in the treatment of perianal fistulas in rats.

Conflicts of interest

The authors declare no conflicts of interest.

REFERENCES

1. Subhas G, Bullar JS, Al-Omari A, Unawane A, Mittal VK, Pearlman R. Setons in the treatment of anal fistula: review of variations in materials and techniques. *Dig Surg*. 2012;29:292–300.
2. Steele SR, Kumar R, Feingold DL, Rafferty JL, Buie WD. Practice parameters for the management of perianal abscess and fistula-in-ano. *Dis Colon Rectum*. 2011;54:1465–74.
3. Lim CH, Shin HK, Kang WH, Park CH, Hong SM, Jeong SK, et al. The use of a staged drainage seton for the treatment of anal fistulae or fistulous abscesses. *J Korean Soc Coloproctol*. 2012;28(6):309–14.
4. Causey MW, Nelson D, Johnson EK, Maykel J, Davis B, Rivadeneira DE, et al. An NSQP evaluation of practice patterns and outcomes following surgery for anorectal abscess and fistula in patients with and without Crohn's disease. *Gastroenterol Rep*. 2013;1:58–63.
5. Dalbem CS, Tomiyoshi SDT, Santos CHM. Assessment of LIFT (ligation of the intersphincteric fistula tract) technique in patients with perianal transsphincteric fistulas. *J Coloproctol*. 2014;34(4):250–3.
6. Hong KD, Kang S, Kalaskar S, Wexner SD. Ligation of intersphincteric fistula tract (LIFT) to treat anal fistula: systematic review and meta-analysis. *Tech Coloproctol*. 2014;18(8):685–91.
7. Vial M, Parés D, Pera M, Grande L. Faecal incontinence after seton treatment for anal fistulae with and without surgical division of internal anal sphincter: a systematic review. *Colorectal Dis*. 2010;12(3):172–8.
8. Ertem M, Gok H, Ozveri E, Ozben V. Application of advancement flap after loose seton placement: a modified two-stage surgical repair of a transsphincteric anal fistula. *Ann Coloproctol*. 2014;30(4):192–6.