



Original Article

Neoadjuvant radiotherapy in stage I cancer of the lower rectum



José Alfredo dos Reis Neto^a, José Alfredo dos Reis Junior^b, Odorino Hideyoshi Kagohara^b, Joaquim Simões Neto^b, Sergio Oliva Banci^b, Luciane Hiane Oliveira^b, Gustavo Alejandro Gutierrez Espinoza^a, Antonio José Tiburcio Alves Júnior^{a,*}

^a Service of Coloproctology, Clínica Reis Neto, Campinas, SP, Brazil

^b Clínica Reis Neto, Campinas, SP, Brazil

ARTICLE INFO

Article history:

Received 12 June 2015

Accepted 18 August 2015

Available online 21 December 2015

Keywords:

Rectal neoplasms

Radiotherapy

Mortality

Irradiation

ABSTRACT

Introduction: The mortality rate in low rectal cancer is related to pelvic and distant recurrence. For stage I tumors, local excision has been used increasingly, but recent studies show the need for caution with the use of this technique, as they do not consider the possibility of a positive node in stage I rectal tumors. Therefore, preoperative radiotherapy should be considered for early tumors, as an attempt to prevent recurrence.

Objective: Show the effectiveness of neoadjuvant radiotherapy in stage I cancer of the lower rectum of a cohort population.

Material and method: A cohort study in a prospective database was made with a total of 538 patients, of which were considered 75 patients with stage I lower rectal cancer. Preoperative radiotherapy was performed and patients were followed up for a minimum period of five years.

Results: Stage I/TI group had 27 patients. All of them presented complete response to the treatment and did not need to be operated. During the follow up time of five years, this group showed no recurrence rate. The stage I/TII group had 48 patients. During the follow up, 8 patients had to be operated due to suspicious lesion or scar. They were submitted to full total local excision. After evaluating the pathological specimen, none of them proved to be adenocarcinoma.

Conclusion: Preoperative radiation, not only reduced the local recurrence and mortality rate in lower rectal cancer, but also reduced the need for surgery in patients with stage I cancer.

© 2015 Sociedade Brasileira de Coloproctologia. Published by Elsevier Editora Ltda. All rights reserved.

* Corresponding author.

E-mails: antonio_xxxv@yahoo.com.br, reisneto@lexxa.com.br (A.J.T. Alves Júnior).

<http://dx.doi.org/10.1016/j.jcol.2015.12.001>

2237-9363/© 2015 Sociedade Brasileira de Coloproctologia. Published by Elsevier Editora Ltda. All rights reserved.

Terapia neoadjuvante para tumores de reto baixo estadio I

R E S U M O

Palavras-chave:

Neoplasias retais
Radioterapia
Mortalidade
Irradiação

Introdução: O percentual de mortalidade em pacientes com câncer de reto baixo está relacionado a recorrências pélvica e remota. No caso de tumores no estágio I, a excisão local vem sendo utilizada cada vez mais; contudo, estudos recentemente publicados demonstraram a necessidade de se ter cautela com o uso dessa técnica, por não se levar em consideração a possibilidade de um nodo positivo em tumores de reto no estágio I. Portanto, a radioterapia pré-operatória é uma opção viável para os tumores em fase inicial, como uma tentativa de evitar recorrência.

Objetivo: Demonstrar a eficácia da radioterapia neoadjuvante em casos de câncer de reto baixo no estágio I em uma coorte da população.

Materiais e métodos: Foi realizado um estudo de coorte em um banco de dados prospectivo, com envolvimento, no total, de 538 pacientes, dos quais 75 foram considerados como tendo câncer de reto baixo no estágio I. No pré-operatório, os pacientes foram tratados com radioterapia e seguidos durante um período mínimo de 5 anos.

Resultados: O Grupo no estágio I/TI consistia em 27 pacientes. Todos obtiveram resposta completa ao tratamento e não houve necessidade de reoperação. Durante o período de 5 anos de seguimento, não houve recorrências nesse grupo. O grupo no estágio I/TII consistia em 48 pacientes. Durante o seguimento, 8 pacientes tiveram que ser operados, devido à suspeita de lesão, ou cicatriz. Para esses casos, optou-se por excisão local total completa. Após a avaliação dos espécimes patológicos, nenhum deles teve diagnóstico de adenocarcinoma.

Conclusão: O uso da radiação pré-operatória não só diminuiu a recorrência local e o percentual de mortalidade em casos de câncer de reto baixo, mas também diminuiu a necessidade de cirurgia em pacientes com câncer no estágio I.

© 2015 Sociedade Brasileira de Coloproctologia. Publicado por Elsevier Editora Ltda.

Todos os direitos reservados.

Introduction

Preoperative radiotherapy in cancer of the lower rectum has been used since 1975.¹ However, during the last decade substantial progress has been made in treatment modalities. The surgical management currently includes a broad spectrum of operative procedures ranging from radical operations to innovative sphincter-preserving techniques; new and improved radiation techniques emerged (conformal radiotherapy, intra-operative radiotherapy) with or without combinations of chemotherapies.²⁻⁵ The mortality rate is related to pelvic and distant recurrence.⁶ Therefore, adequate surgical technique is mandatory in the treatment of the rectal cancer.^{6,7} Also critical is the role of prognostic factors such as the pathologic T (tumor) and N (nodal) classification, circumferential resection margin, and response to preoperative therapy.³ Nodes can be positive even in early tumors.⁸

For stage I rectal cancer, local excision has been used increasingly, but recent studies show the need for caution with the use of this technique, as they do not consider the possibility of a positive node in stage I rectal tumors.^{3,7,8}

Nowadays, appropriate staging plays an increasingly important role, because many treatment decisions must be based on preoperative staging.^{2,3}

Current guidelines advocate for neoadjuvant treatment for stage II and III tumors, once it has been proved that preoperative radiation reduces local recurrence risk and improve long-term survival.⁹⁻¹²

However, knowing that pre-operative radiotherapy is able to decrease, significantly, the number of undifferentiated cells; diminish the grade of tumor invasion in the rectal wall; reduce, statistically, the incidence of local recurrence and alter long-term survival rate leads to believe that neoadjuvant therapy should be used in early tumors as well, preventing a recurrence rate many times reported in stage I patients.¹

Objectives

Show the effectiveness of neoadjuvant radiotherapy in stage I cancer of the lower rectum of a cohort population.

Methods

A cohort study in a prospective database was made from 1978 to 2012, with a total of 538 patients with lower rectum cancer, of which were considered 75 patients with stage I cancer. These individuals were submitted to preoperative radiotherapy. They were 27 patients stage I/TI and 48 patients stage I/T2. All of them had lower rectum adenocarcinoma and were followed by a 5-year minimum.

There was no gender, race and age distinction.

Preoperative dosage of CEA, gamma GT, colonoscopy and abdominal ultrasound were performed in all the patients to stage the tumor. When available endorectal ultrasound was

performed to evaluate size and infiltration of the tumor before and after the irradiation.

Proctoscopy and digital examination were performed at diagnosis and after the end of the irradiation treatment to evaluate tumor extension and wall infiltration.

Preoperative radiotherapy was performed with 200 cGy/daily for 4 consecutive weeks up to a total of 4500 cGy, by means of a linear megavoltage accelerator (25 MeV), in anterior and posterior pelvic fields.

Post-radiation protocol included periodical examination every 3 months for the first two years, with digital examination (or careful perineal palpation) and evaluation of the CEA and every 6 months for the next consecutive three years. Abdominal ultrasound was performed yearly and colonoscopy every other year. When clinical assessment suggested local or general recurrence, a CT scan or MR was accomplished.

Results

The 75 patients with lower rectum cancer were followed for a minimum period of 5 years.

The stage I/TI group had 27 patients, all of them submitted to the same protocol of neoadjuvant therapy. Everyone presented complete response to the treatment and did not need to be operated. During the follow up time of five years, this group showed no recurrence rate.

The stage I/TII group had 48 patients, all of them submitted to the same protocol of neoadjuvant therapy. During the follow up, 8 patients had to be operated due to suspicious lesion or scar. They were submitted to full total local excision. After evaluating the pathological specimen, none of them proved to be adenocarcinoma. It was found dysplasia and adenoma (Fig. 1).

One patient of this group had a distant metastasis, after 5 years that occurred in the lungs (Fig. 2).

The other 40 patients had complete response after neoadjuvant radiotherapy.

Discussion

Treatment of rectal cancer has dramatically evolved during the last three decades shifting toward a tailored approach

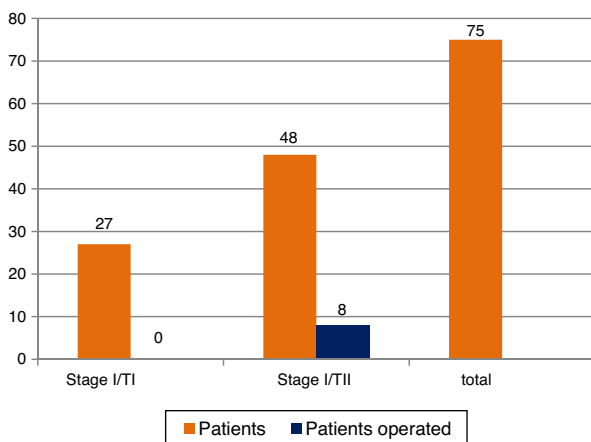


Fig. 1 – Operated patients.

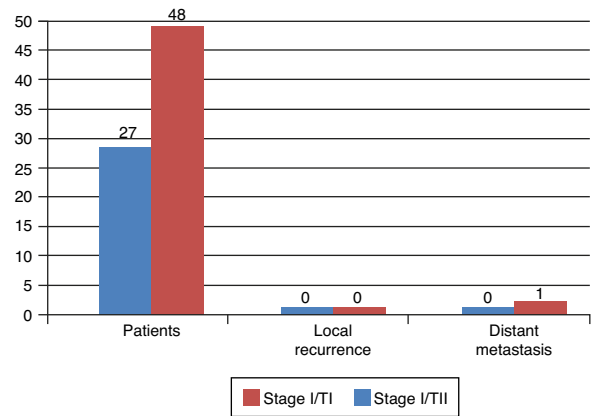


Fig. 2 – Follow up results after 5 years.

based on preoperative staging and response to neoadjuvant therapy.¹³

Preoperative radiotherapy reduces the risk of local recurrence in patients with operable rectal cancer and recurrence, especially locally, is responsible for the great majority of deaths in the first two years after surgery.¹⁴

Previous studies showed that there is a significant difference in the five-year survival rates in patients receiving preoperative radiotherapy, who had a corrected survival rate of 80% versus 34.4% of nonirradiated patients. The local recurrence rate was 2.9% in patients that received neoadjuvant therapy versus 23.5% in those who had not.¹

Endorectal ultrasound (ERUS) displays accuracy of 71–91% and 69–97% for T stage, and 62–83% for nodal staging.¹⁵ Results confirmed in 200 patients, that after the irradiation an involution of the tumor size and volume occurred.¹

Comparing to other studies when preoperative radiotherapy was not used the recurrence rate was much higher.^{15–19}

According to Aguilar, patients undergoing local resection presented recurrence rate of 18% (T1) and 37% (T2) with 54 months of follow-up.

Paty et al. showed rates of 17–74% for T1 rectal cancers and 26–72% for T2 cancers with a median time to relapse of 1.4 years (range 0.4–7.0).

Patients undergoing local excision with transanal endoscopic microsurgery presented recurrence of 13% (T1), 17% (T2) with follow up of 24 months.¹⁸

Bebenek showed 4.4% recurrence rate for T1 and T2 in two year follow up after abdominoperineal resection.²⁰

On the other hand, Lezoch showed a recurrence rate similar to the one presented in this study, with no recurrence in T1 and 2.85% in T2. The similar results are due to the use preoperative radiotherapy before performing a transanal endoscopic microsurgery.^{21,22}

Those results shown that receiving neoadjuvant therapy carries less risk of local recurrence than surgical techniques that did not receive pre operative radiotherapy (local excision, transanal endoscopic microsurgery, abdominoperineal resection, low anterior resection) (Table 1).

A decrease of lymphatic invasion in patients that received preoperative radiotherapy is observed, and also confirmed

Table 1 – Risk of local recurrence.

Local recurrence	T1	T2	Surgery
Aguilar (2000)	18%	37%	LR
Paty (2002)	17–74%	26–76%	LR
Stipa (2004)	13%	17%	TEM
Bebenek (2009)	4.4%	4.4%	APR
Lezoch (2002)	–	2.85%	RDT + TEM
Reis Neto (2012)	–	2.6%	RDT + SUR

through endorectal ultrasound, digital examination and endoscopic an involution on the size and volume of the tumor.^{23,24}

This study did not contemplate the possible complications presented by radiotherapy or alluded to molecular analysis since this was not its goal.

Conclusion

In this cohort, the use of neoadjuvant radiotherapy reduced the risk of local recurrence, the mortality rate, and the needed of surgery in stage 1 cancer of the lower rectum.

Conflicts of interest

The authors declare no conflicts of interest.

REFERENCES

1. Reis Neto JA, Reis JA Jr, Kagohara O, Simoes Neto J, Banci SO, Oliveira LH. Adjuvant therapy on cancer of the lower rectum. Evaluation of the effects of preoperative radiotherapy on the prognosis of patients with cancer of the lower rectum. *J Cancer Ther.* 2012;3:912–9.
2. Fichera A, Allaix ME. Paradigm-shifting new evidence for treatment of rectal cancer. *J Gastrointest Surg.* 2014;18:391–7.
3. Das P, Crane CH. Staging, prognostic factors, and therapy of localized rectal cancer. *Curr Oncol Rep.* 2009;11:167–74.
4. Kachnic LA. Adjuvant chemoradiation for localized rectal cancer: current trends and future directions. *Gastrointest Cancer Res.* 2007;1:64–72.
5. Sauer R. Adjuvant and neoadjuvant radiotherapy and concurrent radiochemotherapy for rectal cancer. *Pathol Oncol Res.* 2002;8:7–17.
6. Wagner TD, Fakhri MG, Yang GY. Management of stage II/III rectal cancer. *J Gastrointest Oncol.* 2010;1:112–9.
7. Sauer R, Rödel C. Adjuvant and neoadjuvant radiochemotherapy of rectal carcinoma. *Praxis.* 2002;91:476–84.
8. Pucciarelli S, Capirci C, Emanuele U, Toppan P, Friso ML, Pennelli GM, et al. Relationship between pathologic T-stage and nodal metastasis after preoperative chemoradiotherapy for locally advanced rectal cancer. *Ann Surg Oncol.* 2005;12:111–6.
9. Loos M, Quentmeier P, Schuster T, Nitsche U, Gertler R, Keerl A, et al. Effect of preoperative radio (chemo) therapy on long-term functional outcome in rectal cancer patients: a systematic review and meta-analysis. *Ann Surg Oncol.* 2013;20:1816–28.
10. Kulu Y, Ulrich A, Büchler MW. Resectable rectal cancer: which patient does not need preoperative radiotherapy? *Dig Dis.* 2012;30:118–25.
11. Rödel C, Trojan J, Bechstein W-O, Woeste G. Neoadjuvant short- or long-term radio(chemo)therapy for rectal cancer: how and who should be treated? *Dig Dis.* 2012;30:102–8.
12. Kim DY, Jung KH. Radiation therapy for rectal cancer. *Korean J Gastroenterol.* 2006;47:285–90.
13. Quirk P, Steele R, Monson J, Grieve R, Khanna S, Couture J, et al. Effect of the plane of surgery achieved on local recurrence in patients with operable rectal cancer: a prospective study using data from the MRC CR07 and NCIC-CTG CO16 randomized clinical trial. *Lancet.* 2009;373:821–8.
14. Sebag-Montefiore D, Stephens RJ, Steele R, Monson J, Grieve R, Khanna S, et al. Preoperative radiotherapy versus selective postoperative chemoradiotherapy in patients with rectal cancer (MRC CR07 and NCIC-CTG CO16): a multicentre, randomized trial. *Lancet.* 2009;373:811–20.
15. Garcia-Aguilar J, Mellgren A, Rothenberger DA. Local excision of rectal cancer without adjuvant therapy. *Ann Surg.* 2000;231:345–51.
16. Sengupta S, Tiandra JJ. Local excision of rectal cancer. *Dis Colon Rectum.* 2001;44:1345–61.
17. Phillip P, Nash GM, Wong WD. Long-term results of local excision for rectal cancer. *Ann Surg.* 2002;236:522–30.
18. Stipa F, Lucandri G, Ferri M, Casula G, Ziparo V. Local excision of rectal cancer with transanal endoscopic microsurgery (TEM). *Anticancer Res.* 2004;24:1167–72.
19. Suppiah A, Hunter IA, Cowley J, Garimella V, Cast J, Hartley JE, et al. Magnetic resonance imaging accuracy in assessing tumor down-staging following chemoradiation in rectal cancer, Medical Research Council (UK) and the National Cancer Institute of Canada. *Colorectal Dis.* 2009;11:249–53.
20. Bebenek M, Pudelko M, Cisarz K, Balcerzak A, Tupikowski W, Wojciechowski L, et al. Abdominosacral amputation of the rectum for low rectal cancers: ten years of experience. Therapeutic results in low rectal cancer patients treated with abdominosacral resection are similar to those obtained by means of anterior resection in mid- and upperrectal cancer cases. *Eur J Surg Oncol.* 2007;33:320–3.
21. Lezoch E, Guerrieri M, Paganini AM, D'Ambrosio G, Baldarelli M, Lezoche G, et al. Transanal endoscopic versus total mesorectal laparoscopic resections of T 2–N 0 low rectal cancers after neoadjuvant treatment. *Surg Endosc.* 2005;19:751–6.
22. Lezoch G, Baldarelli M, Guerrieri M, Paganini AM, De Sanctis A, Bartolacci S, et al. A prospective randomized study with a 5-year minimum follow-up evaluation of transanal endoscopic microsurgery versus laparoscopic total mesorectal excision after neoadjuvant therapy. *Surg Endosc.* 2008;22:278.
23. Habr-Gama A, Perez RO, Lynn PB, Neto AS, Gama-Rodrigues J. Nonoperative management of distal rectal cancer after chemoradiation: experience with the 'watch & wait' protocol. In: Santoro GA, editor. *Rectal cancer, a multidisciplinary approach to management.* Sao Paulo: InTech Inc.; 2011. Chapter 17.
24. Reis Neto JA, Quilici FA, Reis Junior JA. A comparison of nonoperative vs. preoperative radiotherapy in rectal carcinoma. A 10-year randomized trial. *Dis Colon Rectum.* 1989;32:702–10.