



Case Report

Recto-sigmoid lipoma: a case report and review of the literature



Gholamreza Bagherzade^a, Omid Etemad^{b,*}

^a Shahid Beheshti University of Medical Sciences, Colorectal Surgery Ward, Tehran, Iran

^b Shahid Beheshti University of Medical Sciences, Tehran, Iran

ARTICLE INFO

Article history:

Received 25 May 2016

Accepted 8 June 2016

Available online 9 July 2016

Keywords:

Lipoma

Recto-sigmoid

Colorectal

Palavras-chave:

Lipoma

Retossigmoide

Colorretal

ABSTRACT

Lipomas are a growth of fat cells in a fibrous capsule. They are most common in noncancerous tissues. Lipoma of rectum is uncommon and the most common site of its origin is the perianal region. Rarely they could cause rectal bleeding. In this study, we have reported a 53-yrs old man who had been referred to the hospital with symptoms of abdominal pain, rectal bleeding and the problem in bowel movement. Rectal prolapsed with solitary rectal were observed during the clinical observation. Colonoscopy, CT-Scan and MRI were performed for the patient and the results showed a mass suggestive to lipoma which was located in recto/sigmoid region. He underwent the surgery. Intra operative findings showed several soft masses in rectum and a large mass with dimension of 10 cm × 10 cm in sigmoid. Low anterior resection was performed for him and pathology diagnosis was lipoma.

© 2016 Sociedade Brasileira de Coloproctologia. Published by Elsevier Editora Ltda. This is an open access article under the CC BY-NC-ND license (<http://creativecommons.org/licenses/by-nc-nd/4.0/>).

Lipoma retossigmoide: relato de caso e revisão da literatura

R E S U M O

Lipomas são um crescimento de adipócitos em uma cápsula fibrosa. Essas formações são mais comuns em tecidos não cancerosos. O lipoma do reto é de rara ocorrência, e o local mais comum para sua origem é a região perianal. Raramente essas formações podem causar sangramento retal. Nesse estudo, descrevemos um paciente, homem, 53 anos, que foi encaminhado ao hospital com sintomas de dor abdominal, sangramento retal e problemas nos movimentos intestinais. Ao exame clínico, foram observados prolapso retal com solitária do recto. Foi realizada uma colonoscopia e obtidos estudos de TC e IRM; os

* Corresponding author.

E-mails: rasaeti@yahoo.com, omid.etemad@yahoo.com (O. Etemad).

<http://dx.doi.org/10.1016/j.jcol.2016.06.003>

2237-9363/© 2016 Sociedade Brasileira de Coloproctologia. Published by Elsevier Editora Ltda. This is an open access article under the CC BY-NC-ND license (<http://creativecommons.org/licenses/by-nc-nd/4.0/>).

resultados demonstraram uma massa sugestiva de lipoma, localizada na região retossigmoide. O paciente foi encaminhado à cirurgia. Os achados intraoperatórios demonstraram várias massas macias no reto e uma grande massa que media 10 cm × 10 cm no sigmoide. Foi realizada a ressecção anterior e o diagnóstico da patologia foi lipoma.

© 2016 Sociedade Brasileira de Coloproctologia. Publicado por Elsevier Editora Ltda. Este é um artigo Open Access sob uma licença CC BY-NC-ND (<http://creativecommons.org/licenses/by-nc-nd/4.0/>).

Introduction

Lipomas of rectum and colon are rare and the more common sites of their origin are the perianal region.^{1,2} Colonic lipoma was first described by Bauer in 1757.³ Lipomas often occur as solitary lesions in contrast to colonic lipomas which tend to occur as multiple lesions. Patients may be asymptomatic or may present with tenesmus when its location is in the distal rectum. A large lipoma may cause symptoms of obstruction because of its size. A pedunculated lesion may prolapse through the anal canal.⁴ The tumor is soft and well circumscribed on palpation, with its yellowish color visible through the overlying mucosa on visualization using a proctoscope or endoscope. The overlying mucosa can be pinched up, and the lesion is usually compressible.⁵

For treatment the large lesions of colonic lipomas, there are several surgical methods including hemicolectomy, segmental resection of involved colon or local excision.⁶

In case of rectal lipomas, treatment can be done by transanal incision or endoscopically if it is pedunculated.⁷ A large rectal lipoma may require a transabdominal approach for complete removal.

In this case report, we reported a recto-sigmoid lipoma with dimensions of 116 mm × 680 mm.

Case report

A 53-yrs-old man was referred to the hospital with symptoms of abdominal pain, rectal bleeding and problem in bowel movement. During clinical examinations, rectal prolapse with solitary rectal ulcer were observed. Colonoscopy was performed for him.

Colonoscopy reported one infiltrated ulcerative lesion in 3 cm from the anal verge till 8 cm from anal and one other large ulcerative fungating mass near total obstructive mass from 25 cm till 31 cm from anal verge. Non-diagnostic biopsy was performed for him and there was no evidence of dysplasia or malignancy.

As we can find in Fig. 1, spiral abdomino-pelvic CT-Scan was done for him and we observed thickness of rectal wall with pre-rectal fat standing and a 64 mm × 112 mm fat-density mass within the recto-sigmoid lumen that was displaced forward the urinary bladder.

Abdomino-Pelvic MRI showed a fat containing well-defined large (110 mm × 68 mm) mass at rectum and recto-sigmoid junction. The findings were suggestive of rectal lipoma. Fig. 2 shows the MRI for this patient.

CEA was checked with the result of 0.9 and according to the findings, the patient underwent surgery with diagnosis of rectal obstructive mass.

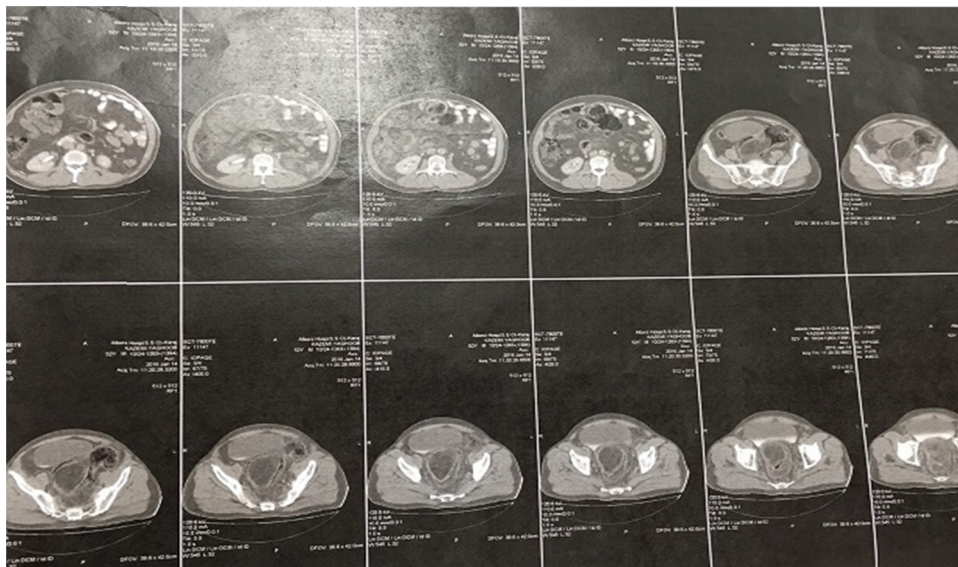


Fig. 1 – Spiral abdomino-pelvic CT-Scan.

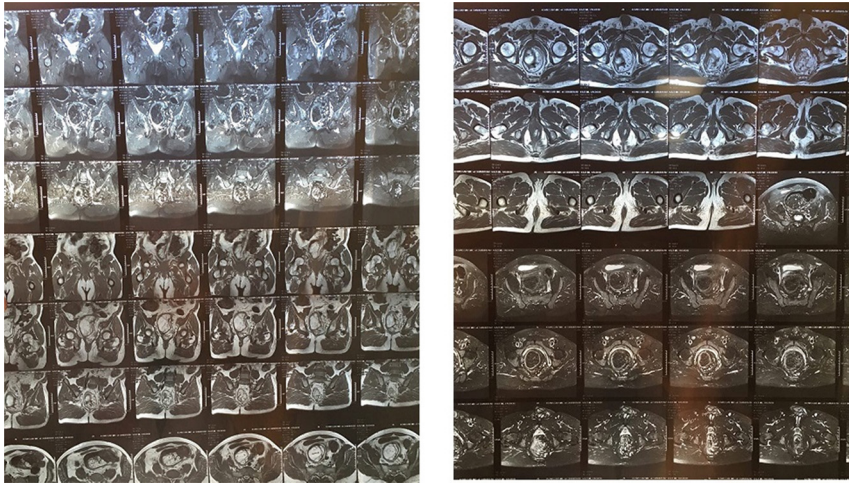


Fig. 2 - Abdomino-pelvic MRI.

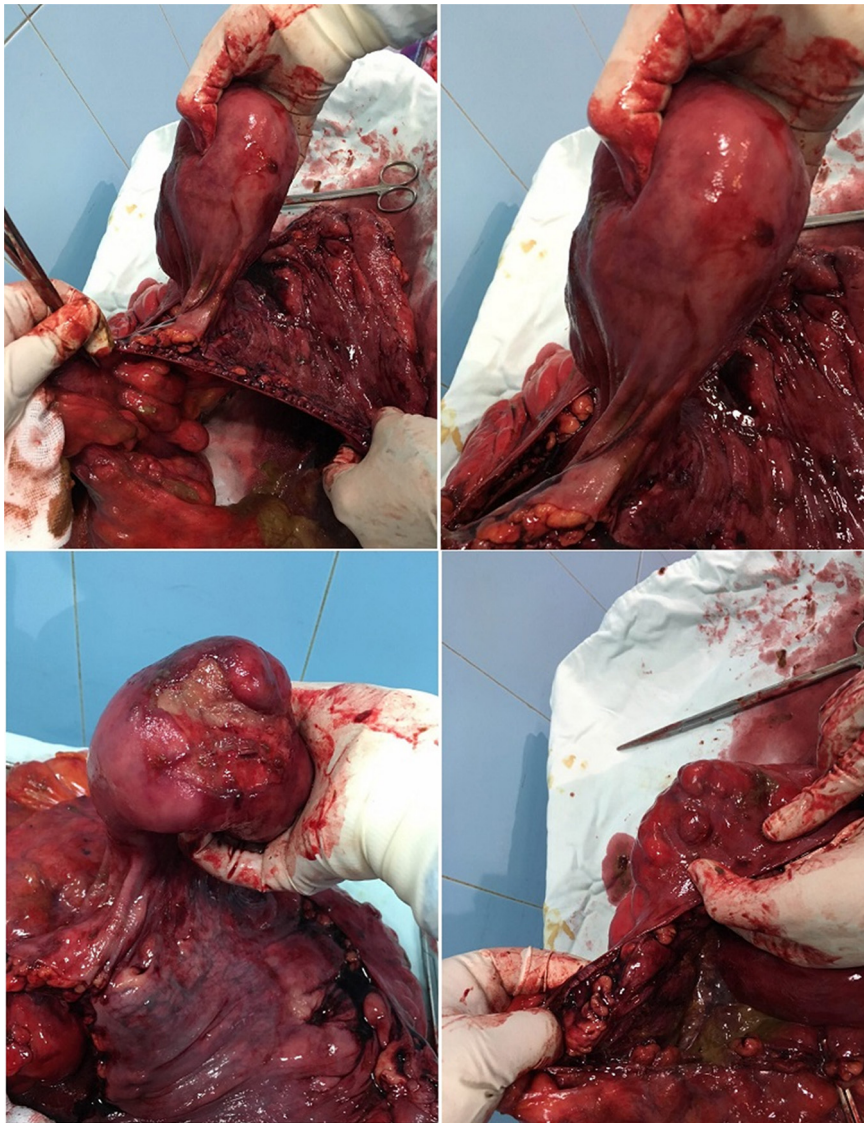

Fig. 3 - The removed sections of sigmoid and upper rectum.

Rectoscopy was performed that was suggestive to rectal prolapse, nodularity and solitary rectal ulcer. Biopsy was done and there was no malignancy. During the surgery, the intra-operative findings showed a soft intramural mass with dimensions of 10 cm × 10 cm in recto-sigmoid region.

Low anterior resection was performed and one other lipoma mass with fewer diameters was removed from the rectum. The operation was ended after rectopexy. Fig. 3 shows the removed sections of sigmoid and upper rectum.

Pathology findings are as follows:

- Multiple lipoma in recto-sigmoid with diameters of 1–15 cm
- Foci ulcerated mucosa
- 12 reactive lymph nodes
- Negative for malignancy

Discussion

Lipomas are composed of mature adipose tissue and are surrounded by a fibrotic capsule. They usually arise in the submucosal layer of the caecum or the sigmoid colon. Occurrence of lipoma in colon is uncommon. Until 2011, total 227 patients with colorectal lipoma were reported. Of this numbers, 9 patients experienced rectal lipoma. There are also some cases that were reported due to the rectal lipoma and presented with prolapse.^{8–11}

65% of lipomas in the gastrointestinal system were located in the colon and 20–25% of them in the small intestine.^{12,13} Lipomas are mostly common at the ascending colon and transverse colon and rarely at the descending and sigmoid colon and rectum.^{14,15}

In an 18-yrs analysis which was done on 17 patients with large-bowel lipoma, only three patients experienced rectal lipoma.¹⁶ In another 10-yrs analysis done in Mayo Clinic, of 91 patients with large-bowel lipoma, no patient was reported with rectal lipoma.¹⁷

Some authors reported that most of affected patients were between ages of 50- till 70-yrs.¹⁸

Lipomas are well differentiated arising from deposits of adipose connective tissue in bowel wall (90% submucosal, 10% subserosal).¹⁹ Most lipomas are diagnosed with colonoscopy as soft yellowish tumors or polyps identified by pressuring the biopsy forceps.²⁰

As long as the colonic lipomas are asymptomatic, they do not require treatment. However with size in excess of 2 cm they give rise to some symptoms: constipation, diarrhea, abdominal pain, rectal bleeding and intussusceptions.²¹ Colonoscopy resection is a treatment choice. If not possible a limited segmental resection or lipomectomy can be advised.²²

Depends on the conditions of the patient, both trans-anal excision and laparoscopic procedures can be done for them as a plan of treatment.²³

Conclusion

To distinguish the rectal/colonic lipomas from the other colorectal tumors, paraclinical examinations, colonoscopy and biopsy should be done. Due to the complications such as

rectal bleeding, obstruction and abdominal pain, colorectal lipomas with diameters of more than 2 cm should be removed. There are several methods for this aim. Colonoscopy removal is advised for the lipomas with diameter of less than 2 cm in case of exceeded size, surgical extraction is necessary.^{3,24} Due to the probability of existence of multiple lipoma masses, full observation is highly recommended.

Conflicts of interest

The authors declare no conflicts of interest.

REFERENCES

1. Chowdri NA, Parray FQ. Benign anorectal disorders. Edited version; 2016.
2. Hayes HT, Burr HB, Melton WT. Submucous lipoma of the colon: review of the literature and report of four cases. *Dis Colon Rectum*. 1960;3:145–8.
3. Mason R, Bristol JB, Petersen V, Lubyrn ID. Gastrointestinal: lipoma induced intussusception of transverse colon. *J Gastroenterol Hepatol*. 2010;25:1177.
4. Zurkirchen MA, Leutenegger A. Submucous lipoma of the colon. *Swiss Surg*. 1998.
5. Rodriguez DI, Drehner DM, Beck DE, McCauley CE. Colonic lipoma as a source of massive hemorrhage. *Dis Colon Rectum*. 1990;33:977–9.
6. Ghidirim G, Mishin I, Gutsu E, Gagauz I, Danch A, Russu S. Giant submucosal lipoma of the cecum: report of a case and review of literature. *Rom J Gastroenterol*. 2005;14:393–6.
7. Nijhawan. Benign anorectal disorders; 1993.
8. Babu KVS, Chowhan AK, Yootla M, Reddy ML. Submucous lipoma of sigmoid colon: a rare entity. *J Lab Physicians*. 2009;1:82–3.
9. Katsinelos P, Chatzimavroudis G, Zavos C, Kountouras J. Endoloop-assisted amputation of a large rectal lipoma. *Gastrointest Endosc*. 2007;66:636–7.
10. Nijhawan S, Rai RR, Mathur A, Bhargava N. Rectal lipoma treated by endoscopic polypectomy. *Indian J Gastroenterol*. 1993;12:23.
11. Yadoo S, Dintzman M, Chaimoff C. Lipoma of the rectum. Two case reports. *Am J Proctol*. 1971;22:120–2.
12. Aminian A, Noaparast M, Mirsharifi R, Bodaghabadi M, Mardany O, Ali FA, et al. Ileal intussusception secondary to both lipoma and angiolipoma. *Cases J*. 2009;2:7099.
13. Nebbia JF, Cucchi JM, Novellas S, Bertrand S, Chevallier P, Bruneton JN. Lipomas of the right colon: report on six cases. *Clin Imaging*. 2007;31:390–3.
14. Marra B. Intestinal occlusion due to a colonic lipoma: a propos 2 cases. *Minerva Chir*. 1993;48:1035–9.
15. Manchikalapati P, Levey J. Suspected asymptomatic large colon lipoma: biopsy? A case report. *Pract Gastroenterol*. 2008;32:35–40.
16. Rogy MA, Mirza D, Berlakovich G, Winkelbauer F, Rauhs R. Submucous large-bowel lipomas – presentation and management. *Eur J Surg*. 1991;157:51–5.
17. Taylor BA, Wolff BG. Colonic lipomas. Reports of two unusual cases and review of the Mayo Clinic experience, 1976–1985. *Dis Colon Rectum*. 1987;30:888–93.
18. Creasy TS, Baker AR, Talbot IC, Veitch PS. Symptomatic submucosal lipoma of the large bowel. *Br J Surg*. 1987;74:984–6.

19. Corman ML. Colon & rectal surgery. New York: Lippincott-Raven Publishers; 1998. p. 884-958.
20. Rodriguez DI, Drehner DM, Beck DE, McCauley CE. Colonic lipoma as a source of massive hemorrhage: report of a case. *Dis Colon Rectum*. 1990;33:977-9.
21. Zurkirchen MA, Leutenegger A. Submucous lipoma of the colon – report of two cases. *Swiss Surg*. 1998;4: 156-7.
22. Holzheimer RZ, Mannick JA. Surgical treatment: evidence-based and problem-oriented. Munich: Zuckschwerdt; 2001.
23. Ladurner R, Mussack T, Hohenbleicher F, Folwaczny C, Siebeck M, Hallfeld K. Laparoscopic-assisted resection of giant sigmoid lipoma under colonoscopic guidance. *Surg Endosc*. 2003;17:160.
24. Gohar A, Salam MD. Lipoma excision. *Am Fam Physician*. 2002;65:901-5.