



Original Article

LASER hemorrhoidal dearterialization



Paulo Boarini*, Lucas Rodrigues Boarini, Paulo de Azeredo Passos Candelaria, Edgard Mesquita de Lima, Marcelo Rodrigues Boarini

Hospital Municipal do Tatuapé, Residência de Cirurgia Geral, Serviço de Coloproctologia, São Paulo, SP, Brazil

ARTICLE INFO

Article history:

Received 24 August 2016

Accepted 4 December 2016

Available online 28 December 2016

Keywords:

Hemorrhoids

Hemorrhoidal LASER Procedure

Hemorrhoidal dearterialization

ABSTRACT

Introduction: Hemorrhoidal disease is associated with the theory of arterial blood hyperflow causing swellings in hemorrhoids and, consequently, hyperplasia and venous congestion. The technique helps to promote the obliteration of the terminals of the superior rectal artery branches without the need for anesthesia by electrofulguration with diode fiber LASER. The objective of this study is to describe the results of 55 patients with hemorrhoidal disease treated by the Hemorrhoidal LASER Procedure technique.

Method: Without the need of anesthesia, terminal arterioles of the upper rectal artery are identified by a Doppler transducer (20 MHz probe 3 mm) placed on a specially designed proctoscope. After identification, it promotes arteriolar electrofulguration at 980 nm fiber laser diode, causing interruption of hemorrhoidal flow. This procedure is repeated circumferentially, following the clockwise positions.

Results: Between 2011 and 2014, 55 patients underwent the Hemorrhoidal LASER Procedure technique for hemorrhoidal disease grades I, II and III. There was no need for anesthesia and only two patients required sedation for the procedure. The overall satisfaction rate was 89%, with symptom resolution in 84% and a decrease of at least one grade in hemorrhoidal disease in 80% of cases.

Conclusion: Hemorrhoidal LASER Procedure is a painless outpatient technique that does not require anesthesia, in addition to being safe and easy to perform. It is effective in reducing symptoms and complications of the hemorrhoidal disease grades I and II, with high satisfaction rates.

© 2017 Sociedade Brasileira de Coloproctologia. Published by Elsevier Editora Ltda. This is an open access article under the CC BY-NC-ND license (<http://creativecommons.org/licenses/by-nc-nd/4.0/>).

Desarterialização hemorroidária a LASER

RESUMO

Introdução: A doença hemorroidária está associada a teoria vascular de hiperfluxo arterial causando dilatações nos plexos hemorroidários e, conseqüentemente, hiperplasia e congestão venosa. A técnica HeLP promove a obliteração dos ramos terminais da artéria retal superior, sem a necessidade de anestesia, através da eletrofulguração com fibra de diodo

Palavras-chave:

Hemorroidas

Hemorrhoidal LASER Procedure

Desarterialização hemorroidária

* Corresponding author.

E-mail: pboarini@uol.com.br (P. Boarini).

<http://dx.doi.org/10.1016/j.jcol.2016.12.001>

2237-9363/© 2017 Sociedade Brasileira de Coloproctologia. Published by Elsevier Editora Ltda. This is an open access article under the CC BY-NC-ND license (<http://creativecommons.org/licenses/by-nc-nd/4.0/>).

LASER. O objetivo deste trabalho é descrever os resultados de 55 pacientes com doença hemorroidária tratados pela técnica HeLP.

Método: Sem a necessidade de anestesia, as arteríolas terminais da artéria retal superior são identificadas através de um transdutor doppler (20mhz probe de 3 mm) locado em um proctoscópio especialmente desenhado. Após a identificação, promove-se a eletrofulguração arteriolar através de uma fibra de 980 nm de diodo LASER, ocasionando interrupção do hiperfluxo hemorroidário. Este procedimento é repetido circunferencialmente, seguindo-se as posições das horas de um relógio.

Resultados: Entre 2011 e 2014, 55 pacientes foram submetidos a técnica HeLP para doença hemorroidária de graus I, II e III. Nenhum paciente utilizou anestesia e apenas dois necessitaram sedação para a realização do procedimento. O índice de satisfação global atingiu 89%, houve resolução dos sintomas em 84% e diminuição de ao menos um grau, na doença hemorroidária, em 80% dos casos.

Conclusão: HeLP é uma técnica ambulatorial e indolor, que não utiliza qualquer anestesia, é segura e fácil de ser realizada. Eficiente para reduzir sintomas e complicações da doença hemorroidária graus I e II, com índice de satisfação elevada.

© 2017 Sociedade Brasileira de Coloproctologia. Publicado por Elsevier Editora Ltda. Este é um artigo Open Access sob uma licença CC BY-NC-ND (<http://creativecommons.org/licenses/by-nc-nd/4.0/>).

Introduction

Hemorrhoidal disease affects a large part of the world's population. The prevalence in our country is not precisely documented, but in the United States it is approximately 4.4%.¹ The disease is associated with the vascular theory of arterial blood hyperflow, causing dilations in the hemorrhoidal plexuses and, consequently, venous hyperplasia and congestion.²

In 1995, Morinaga et al. proposed a new therapeutic method based on the etiopathogenesis described above. A Doppler (Moricorn) was used in the assessment and after the arterial flow identification, a high ligature was made in these branches, reducing the blood gradient reaching the hemorrhoidal plexus.³ Based on this principle, several techniques that require anesthesia have been developed, such as mechanical anopexy⁴ and transanal hemorrhoidal dearterialization (THD).^{2,5}

In search for a surgical technique for hemorrhoidal disease with less postoperative pain, Salfi et al., in 2009, described the Hemorrhoidal LASER Procedure (HeLP) technique. It is a minimally-invasive technique, which does not require anesthesia, and consists in the identification of the terminal branches of the rectal artery through a Doppler located in a specially adapted proctoscope, followed by photocoagulation of these branches using a 980 nm LASER diode fiber.^{6,7}

This publication aims to describe the first 55 cases in which the HeLP technique was used in Brazil. A three-year follow-up was carried out, analyzing clinical and functional aspects of patients operated by the same surgical team, evaluating pre- and postoperative symptoms, characteristics of the studied population, description of the technique used, need for anesthesia for the procedure and the overall satisfaction index related to the technique.

Materials and method

Between 2011 and 2014, 55 patients were submitted to the HeLP technique, by the same surgeon, for hemorrhoidal disease grades I and II, or grade III with little mucosal prolapse. Grade IV or grade III hemorrhoids with large mucosal prolapse identified during outpatient proctologic examination were excluded from the study. Data were prospectively collected and analyzed.

Before undergoing the surgical procedure, the patients were submitted to colonoscopy or rectosigmoidoscopy to exclude other possible causes of bleeding.

The patients signed the free and informed consent, which explained about the procedure to be performed. The patients were evaluated on days 7, 30, 90, 120 and 180 postoperatively. The visual analog scale (VAS) of pain was applied two hours after surgery in all patients and a retrograde questionnaire was applied on the day 7 postoperatively. Anoscopy was performed to evaluate internal hemorrhoids after 30 days postoperatively. Quality of life assessment was questioned after the third postoperative month. Control Doppler evaluation was performed in all patients, after 120 days, postoperatively.

HeLP technique

The patient is placed in the lithotomy position, without the need for any type of anesthesia. Only two cases required analgesia, per the patient's request. Antibiotic prophylaxis with cefazolin was used in all cases.

A proctoscope that was specially designed for the HeLP technique is placed in the patient's distal rectum. The terminal branches of the superior rectal artery are identified at 3 cm from the pectinate line through a Doppler transducer (20 MHz, 3-mm probe) located in a small working window drawn on the proctoscope (Fig. 1).

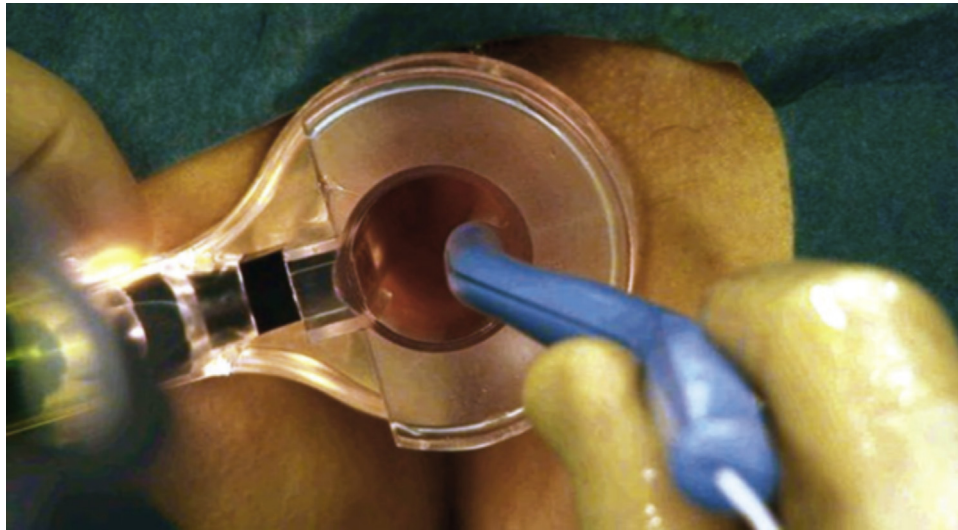


Fig. 1 – Identification of terminal arterioles through Doppler use.

After identification of the arterioles, the Doppler is withdrawn and the 980 nm LASER optical fiber is introduced in the same locus (Fig. 2). The Leonardo laser – diode device used in our study was calibrated with a power of 13 W. Interruption of the artery supplying blood flow is performed by activating LASER energy through the optical fiber. First, two operator-controlled shots are performed, at 2 mm from the mucosa, to promote scorching of the latter, followed by three preset shots for arterial obliteration (Fig. 3). Each shot lasts 1.2 s, with a 0.6 s interval between them.

The method efficacy is evaluated again by Doppler shortly after the last LASER shot and, if the flow persists, a new shot is carried out at the same site. There may be persistence of the arterial flow, and in this case, we believe it to be resonance of the larger peri-rectal arteries.

A clockwise rotation of the rectoscope allows the identification of all branches of the superior rectal artery. In this way, the position of the clock hours is followed, checking at 1, 2, 3 o'clock and so on. A maximum of 12 branches can be treated at the same surgical procedure.

Results

The HeLP technique was applied to 55 patients, 28 women and 27 men, with a mean age of 45 years (22–67 years). Most the population submitted to surgery (44 patients) was classified as having hemorrhoids grades I and II and 20% of the sample had grade III hemorrhoids at diagnosis (Table 1).

Eleven patients had previous surgeries for treatment of hemorrhoids (8 rubber band ligations, 2 PPHs and 1 THD). No patient showed complications due to the previous procedure, only hemorrhoidal disease recurrence (Table 1).

Regarding the surgical indication, 40 patients had hema-tochezia as the main complaint, 6 patients had episodes of hemorrhoidal thrombosis (acute pain and anal lumps) treated clinically in other services, 5 patients had anal discomfort secondary to prolapse during evacuation and 4 patients complained of anal pruritus (Table 2).

Table 1 – Patient characteristics.

| Characteristics | Patients (n = 55) |
|--------------------------------------|-------------------|
| Mean age (years) | 45.5 (22–67) |
| Gender (%) | |
| Male | 49% |
| Female | 51% |
| Hemorrhoid grade (%) | |
| Grades I and II | 80% |
| Grade III | 20% |
| Previous surgeries (%) | |
| Rubber band ligation | 14% |
| PPH | 4% |
| THD | 2% |
| Main symptom (%) | |
| Bleeding | 73% |
| Previous acute episodes (thrombosis) | 11% |
| Anal discomfort | 9% |
| Pruritus | 7% |

PPH, procedure for prolapse and hemorrhoids (PPH); THD, transanal hemorrhoidal dearterialization.

Table 2 – Perioperative and follow-up period.

| Characteristics | Patients (n = 55) |
|-----------------------------------|-------------------|
| Time of surgery (min) | 9.9 (7–19) |
| Perioperative bleeding (%) | 5% |
| Postoperative pain VAS (mean) | 1.4 (0–3) |
| Intraoperative anesthesia | 0 |
| Intraoperative sedation (%) | 4% |
| Postoperative tenesmus (%) | 15% |
| Evaluation at 6 months (%) | |
| Symptom disappearance | 84% |
| Overall satisfaction index | 89% |
| Nipple volume reduction (1 grade) | 80% |

Min, minutes; VAS, visual analog scale.

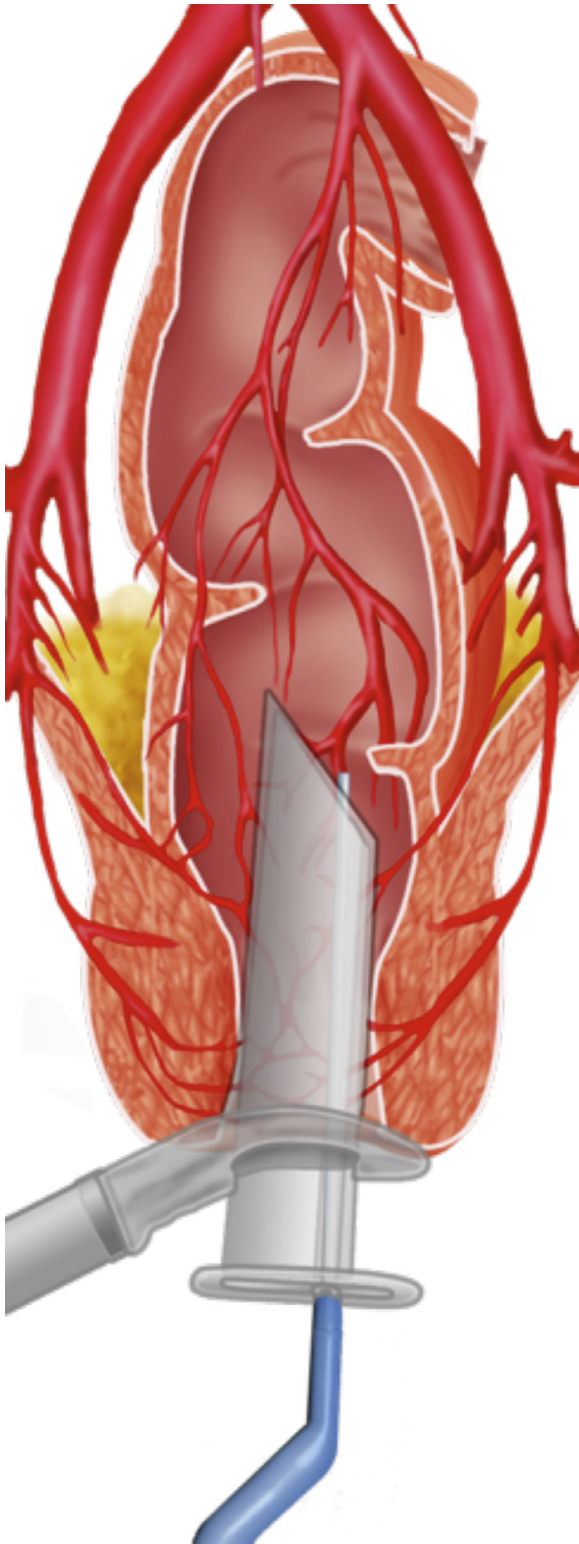


Fig. 2 – Identification of arterioles.

None of the surgeries required the use of anesthesia. The mean surgical time was 9.9 min, ranging from 7 to 19 min. The mean number of branches of the superior rectal artery that were obliterated was 10.1 arterioles (7–12). Only 2 patients were anxious in the preoperative period and we chose to

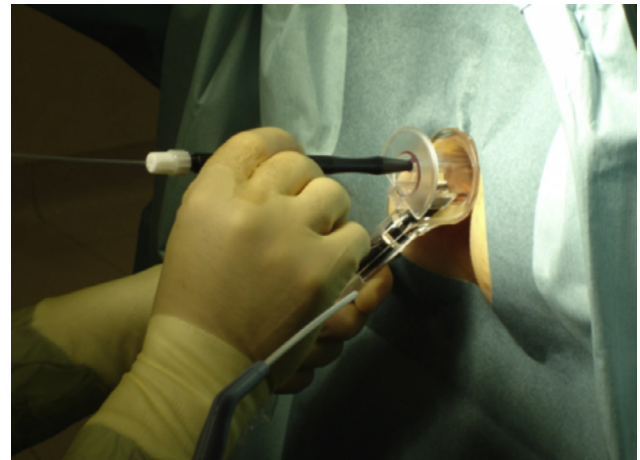

Fig. 3 – Arterial obliteration using 980 nm LASER fiber optics.

perform sedation with midazolam and fentanyl for the safety of the procedure. Bleeding during the surgical procedure occurred in three patients, but all were treated with LASER fiber, requiring no more invasive maneuvers for hemostasis. No procedure was performed on the external components (Table 2).

The mean visual analog pain scale in the first 2 h was 1.4 (0–3). The mean time between surgery and hospital discharge was 4 h.

At the re-evaluation on day 7 postoperatively, 11 patients complained of self-limited bleeding and 8 patients complained of tenesmus, which showed complete resolution during follow-up. On day 30 postoperatively, 44 of the 55 patients had a reduction of at least one grade in the classification of hemorrhoidal disease.

All patients were assessed with Doppler after day 120 postoperatively. We verified that some patients had flow at some of the previously photocoagulated points, albeit not necessarily accompanied by symptom return. The bleeding decreased in all cases for which it was the main complaint. At 180 days, postoperatively, 46 of 55 patients reported symptom disappearance. The overall satisfaction with the surgical and postoperative procedures reached 89%, and 80% of the patients showed reduction of at least one grade of hemorrhoidal disease (Table 2).

Discussion

The dearterialization of the terminal branches of the superior rectal artery undoubtedly constitutes an efficient way to treat hemorrhoidal disease.²⁻¹⁵

Several techniques used for the treatment of hemorrhoidal disease seek to balance efficiency and less postoperative pain. The conventional techniques bring fear to many patients,^{16,17} who refrain from being adequately treated, either due to previous experience, or from reports of friends and relatives.

Current techniques aim to interrupt the flow in the terminal portion of the arterioles, with minimal tissue excision and, consequently, less painful sensation,^{2-15,18-20} when compared

to the so-called excisional or conventional techniques.^{16,17} The importance in choosing the technique is paramount to the success in each case.

The HeLP technique is well-established for the treatment of grades I and II hemorrhoidal disease and some grade III cases, where the small prolapse is not part of the complaint. It has been successfully disseminated in the United Kingdom, Italy, Czech Republic, Spain, and Turkey, as well as in Mexico, Argentina and others.^{6,7,21-23} Despite our experience described in this study, new publications with larger samples and longer follow-up are necessary, always aiming at achieving excellence in the treatment of these cases.

Giamundo et al., in a comparative study with rubber band ligation for grades II and III hemorrhoidal disease showed less postoperative pain ($p < 0.001$), greater symptom resolution ($p < 0.001$), greater number of patients with a one-grade reduction of hemorrhoidal disease ($p < 0.001$) and better quality of life ($p = 0.002$). Therefore, although it is a higher-cost technique, it has very satisfactory short- and long-term results.²¹

It is noteworthy the fact that it is a technique that does not require anesthesia and can be repeated several times, as many as necessary, without causing damage to the anorectal anatomy and physiology. The fact that it does not require anesthesia does not prevent its performance with the aid of sedation or even compound analgesia. It is an advance in the outpatient treatment of hemorrhoidal disease, as well as a technological-scientific advance in the use of a specially-designed proctoscope for the precise identification of the terminal arterioles through Doppler, and its photocoagulation through LASER use.^{6,7,21-23}

Our study was limited to hemorrhoids grades I and II, as well as grade III hemorrhoids with small prolapse, but new studies have demonstrated good results of HeLP use with associated mucopexy when the patient has a large mucosal prolapse.²²

There are also some economic barriers, mainly because it is a relatively new and less disseminated technique in our country, but comparative studies with other existing techniques have reported a higher index of patient satisfaction.^{6,7,21-23} This procedure decreases the costs of the hospital stay, which represents an important part of the amount spent with treatment.

We conclude that this is an efficient, painless, ambulatory, and easy-to-perform technique, in which the learning curve becomes small, given the number of times the same procedure of identification and photocoagulation is performed in a single patient.

Conflicts of interest

The authors declare no conflicts of interest.

REFERENCES

- Loder PB, Kamm MA, Nicholls RJ, Phillips RKS. Haemorrhoids pathology, pathophysiology and aetiology. *Br J Surg*. 1994;81:946-54.
- Ratto C, Donisi L, Parello A, Litta F, Doglietto GB. Evaluation of transanal hemorrhoidal dearterialization as a minimally invasive therapeutic approach to hemorrhoids. *Dis Colon Rectum*. 2010;53:803-11.
- Morinaga K, Hasuda K, Ikeda T. A novel therapy for internal hemorrhoids: ligation of the hemorrhoidal artery with a newly devised instrument (Moricorn) in conjunction with a Doppler flowmeter. *Am J Gastroenterol*. 1995;90:610-3.
- Longo A. Treatment of haemorrhoids disease by reduction of mucosa and haemorrhoidal prolapse with a circular suturing device: a new procedure. In: *Proceedings of the Sixth World Congress of Endoscopic Surgery*, Monduzzi. 1998. p. 777-84.
- Ratto C, Giordano P, Donisi L, Parello A, Litta F, Doglietto GB. Transanal haemorrhoidal dearterialization (THD) for selected fourth-degree haemorrhoids. *Tech Coloproctol*. 2011;15:191-7.
- Salfi R. A new technique for ambulatory hemorrhoidal treatment. *Coloproctology*. 2009;31:99-103.
- Giamundo P, Cecchetti W, Esercizio L, Fantino G, Geraci M, Lombezzi R, et al. Doppler-guided Hemorrhoidal LASER Procedure for the treatment of symptomatic hemorrhoids: experimental background and short-term clinical results of a new mini-invasive treatment. *Surg Endosc*. 2011;25:1369-75.
- Toh EL, Ng KH, Eu KW. The fourth branch of the superior rectal artery and its significance in transanal haemorrhoidal dearterialisation. *Tech Coloproctol*. 2010;14:345-8.
- Sohn N, Aronoff JS, Cohen FS, Weinstein MA. Transanal hemorrhoidal dearterialization is an alternative to operative hemorrhoidectomy. *Am J Surg*. 2001;182:515-9.
- Sobrado CW Jr, Hora JAB. Tratamento Cirúrgico da Doença Hemorroidária por Desarterialização Transanal Guiada por Doppler associada ao Reparo Anorretal: A Técnica do THD. *Atualização em Cirurgia do Aparelho Digestivo e em Coloproctologia*, 2012. São Paulo: Departamento de Gastroenterologia da Faculdade de Medicina da USP; 2012. p. 319-26.
- Ramírez JM, Aguilera V, Elía M, Gracia JA, Martínez M. Doppler-guided hemorrhoidal artery ligation in the management of symptomatic hemorrhoids. *Rev Esp Enferm Dig*. 2005;97:97-103.
- Qin PP, Huang B, Cai HJ, Ge Q, Wang ZL. A prospective controlled comparative study of Doppler-guided hemorrhoidal artery ligation versus operative procedures for prolapse and hemorrhoids. *Zhonghua Yi Xue Za Zhi*. 2010;90:3131-4.
- Pol RA, van der Zwet WC, Hoornenborg D, Makkinga B, Kaijser M, Eeftinck SM, et al. Results of 244 consecutive patients with hemorrhoids treated with Doppler-guided hemorrhoidal artery ligation. *Dig Surg*. 2010;27:279-84.
- Jeong WJ, Cho SW, Noh KT, Chung SS. One year follow-up result of Doppler-guided hemorrhoidal artery ligation and recto-anal repair in 97 consecutive patients. *J Korean Soc Coloproctol*. 2011;27:298-302.
- Hora JAB, Klajner S, Kruglensky D, Sobrado CW Jr. Tratamento Cirúrgico da Doença Hemorroidária por Desarterialização Transanal Guiada por Doppler associada ao Reparo Anorretal (A Técnica do THD): Experiência Inicial. In: *1º Congresso Paulista de Coloproctologia*. São Paulo 8 e 9 de junho de 2012.
- Ferguson JA, Mazier WP, Ganchrow MI, Friend WG. The closed technique of hemorrhoidectomy. *Surgery*. 1971;70:480-4.
- Milligan ETC, Morgan C, Naughton JLF, Office RR. Surgical anatomy of the anal canal and the operative treatment of haemorrhoids. *Lancet*. 1937;II:1119-24.
- Infantino A, Altomare DF, Bottini C, Bonanno M, Mancini S. Prospective randomized multicentre study comparing stapler haemorrhoidopexy with Doppler-guided transanal haemorrhoid dearterialization for third-degree haemorrhoids. *Colorectal Dis*. 2012;14:205-11.

19. Greenberg R, Karin E, Avital S, Skornick Y, Werbin N. First 100 cases with Doppler-guided hemorrhoidal artery ligation. *Dis Colon Rectum*. 2006;49:485-9.
20. Giordano P, Overton J, Madeddu F, Zaman S, Gravante G. Transanal hemorrhoidal dearterialization: a systematic review. *Dis Colon Rectum*. 2009;52:1665-71.
21. Giamundo P, Salfi R, Geraci M, Tibaldi L, Murru L, Valente M. The hemorrhoid laser procedure technique vs rubber band ligation: a randomized trial comparing 2 mini-invasive treatments for second- and third-degree hemorrhoids. *Dis Colon Rectum*. 2011;54:693-8.
22. Giamundo P, Geraci M, Tibaldi L, Esercizio L, Agostini S, Testore P, et al. Laser haemorrhoidal arterial closure (HeLP) with recto-anal-repair (RAR): a novel procedure for the treatment of advanced haemorrhoidal disease (Abstract). *Colorectal Dis*. 2014;16 Suppl. 3:21-36.
23. Giamundo P. Advantages and limits of hemorrhoidal dearterialization in the treatment of symptomatic hemorrhoids. *World J Gastrointest Surg*. 2016;8:1-4.