



Technical Note

Double single-port transanal pouch surgery: a novel technique for rectal excision and ileo-anal pouch anastomosis for ulcerative colitis



Janindra Warusavitarne^a, Paulo Gustavo Kotze^{b,*}

^a St. Mark's Hospital, Department of Colorectal Surgery, London, United Kingdom

^b Pontifícia Universidade Católica do Paraná (PUCPR), Hospital Universitário Cajuru, Unidade de Cirurgia Colorretal, Curitiba, PR, Brazil

ARTICLE INFO

Article history:

Received 15 July 2017

Accepted 20 July 2017

Available online 6 September 2017

Keywords:

Colitis ulcerative

Rectum

Minimally invasive surgical procedures

ABSTRACT

Surgery for ileoanal pouch has evolved dramatically over the last 30 years. Many of the advances relate to minimally invasive approaches that not only offer cosmetic benefits but also have advantages that are well described in the literature. In this technical note, the authors describe the double single-port transanal pouch operation. An abdominal single-port is used for total colectomy, at the site of the ileostomy. A transanal single-port is used for the 'bottom-up' rectal resection. The technical steps and potential advantages of the technique are discussed in detail. Double single-port transanal pouch surgery is technically feasible and can have significant benefits in ulcerative colitis patients.

© 2017 Sociedade Brasileira de Coloproctologia. Published by Elsevier Editora Ltda. This is an open access article under the CC BY-NC-ND license (<http://creativecommons.org/licenses/by-nc-nd/4.0/>).

Cirurgia de reservatório ileal com duplo single-port: uma nova técnica para a ressecção retal e anastomose ileo-anal na retocolite ulcerativa

RESUMO

A cirurgia para bolsa ileoanal evoluiu excepcionalmente nos últimos 30 anos. Muitos dos avanços referem-se a abordagens minimamente invasivas, que não só oferecem benefícios estéticos, mas também significam vantagens já devidamente descritas na literatura. Nesta nota técnica, os autores descrevem a operação de reservatório ilealtransanal com duplo acesso por single-port. Um portal único abdominal é utilizado para a colectomia total, no local da ileostomia. Um segundo portal únicotransanal é usado para a ressecção retal

Palavras-chave:

Colite ulcerativa

Reto

Procedimentos cirúrgicos minimamente invasivos

* Corresponding author.

E-mail: pgkotze@hotmail.com (P.G. Kotze).

<http://dx.doi.org/10.1016/j.jcol.2017.07.005>

2237-9363/© 2017 Sociedade Brasileira de Coloproctologia. Published by Elsevier Editora Ltda. This is an open access article under the CC BY-NC-ND license (<http://creativecommons.org/licenses/by-nc-nd/4.0/>).

“de baixo para cima”. As etapas técnicas e potenciais vantagens da técnica são discutidas em detalhes. A cirurgia de reservatório ilealtransanal com duplo acesso por porta única é tecnicamente viável e pode representar benefícios significativos em pacientes com colite ulcerativa.

© 2017 Sociedade Brasileira de Coloproctologia. Publicado por Elsevier Editora Ltda. Este é um artigo Open Access sob uma licença CC BY-NC-ND (<http://creativecommons.org/licenses/by-nc-nd/4.0/>).

Introduction

Surgery for ileoanal pouch has evolved considerably over the years. Minimally invasive techniques have been the mainstay of recent developments and low stapled anastomoses have been possible with the advent of advanced stapling devices.^{1,2} The latest advance in minimally invasive surgery is the transanal rectal resection, and this technique has been well described in pouch surgery.³

There are several potential advantages to the transanal approach. The advantages are probably best conferred in the narrow male pelvis and in obese patients. This dissection laparoscopically is frequently difficult and may often lead to conversion. In addition, the technique avoids multiple stapler firings across the distal rectum which can increase the risk of anastomotic leak.⁴ Subsequent reinforcement of the anastomosis through the anus has the theoretical advantage of further reducing the leak rate.

Currently, only technical descriptions and small case series discuss the feasibility and outcomes of the transanal pouch procedure.^{3,5,6} There are also different anal platforms that can be used: TEM (Transanal Endoscopic Microsurgery, Richard Wolff, Germany), TEO (Transanal Endoscopic Operation, Karl Storz, Tuttlingen, Germany) or detachable single port devices. TEM and TEO are fixed platforms that can make the procedure challenging in some cases. Detachable devices do not have fixation, and allow the surgeon to have better triangulation and comfort to perform the procedure.

The aim of this technical note is to describe in detail the surgical steps of the double single-port transanal pouch surgery, and to discuss possible advantages of the technique.

Surgical technique

In the double single-port procedure, a GelPoint Port (Applied Medical, Rancho Santo Margarita, California) is placed at the ileostomy site, and a GelPoint Path (Applied Medical, Rancho Santo Margarita, California) is used for the transanal procedure. In order to establish a pneumoperitoneum, a single incision is performed at the stoma site, generally in the right iliac fossa. If the patient had a previous colectomy with mucous fistula, the fistula with the rectal stump can be mobilised and released into the abdominal cavity, after which the GelPoint is inserted. This has a ring to secure it to the abdominal wall and a lid through which ports are inserted.

The GelPoint device has three working ports and a standard 10 mm 30° laparoscopic camera (Karl Storz, Tuttlingen, Germany) is used, which can be inserted into any of the ports.

An additional 5 mm port can be placed in the left iliac fossa to allow better triangulation and retraction, if necessary. This site is usually used to place the pelvic drain at the end of the procedure. Pneumoperitoneum is usually maintained at a pressure of 12 mmHg.

The rectal dissection can be commenced in the TME (total mesorectal excision) plane or the close rectal approach from the abdominal port. The superior rectal artery is then divided. The rectal phase of the operation is commenced concurrently and a purse string suture is placed approximately 3–4 cm proximal to the dentate line with the aid of a Lonestar retractor (CooperSurgical, Trumbull, USA). The amount of rectal mucosa that is left behind after the initial distal rectal division is based on the degree of proctitis and the presence or absence of dysplasia. When dysplasia is not the indication for surgery or when the distal proctitis is not severe, a 1–2 cm rectal cuff is left to reduce the risk of stool leakage.

The GelPoint Path transanal device is placed in the anal canal (Fig. 1). Two standard ports are placed within the gel followed by a 12 mm Airseal port (Conmed USA). Air seal insufflation is commenced at 5 mmHg until the device is active and then increased to 20 mmHg. The dissection is started laterally using a diathermy hook. We prefer to use a hook rather than a harmonic scalpel, as it helps to reduce smoke and facilitates endoscopic viewing (Fig. 2). The close rectal dissection is continued such that the abdominal and rectal operators approach the mid rectum from opposite directions. In cases with associated dysplasia, the TME plane must be respected and followed. During this part of the procedure, the two operators can assist each other to ensure safety and adequate retraction (Fig. 3). Simultaneous dissection also reduces the operation time and can make the operation easier. Once the proctectomy is completed the specimen is brought out through the stoma site, or

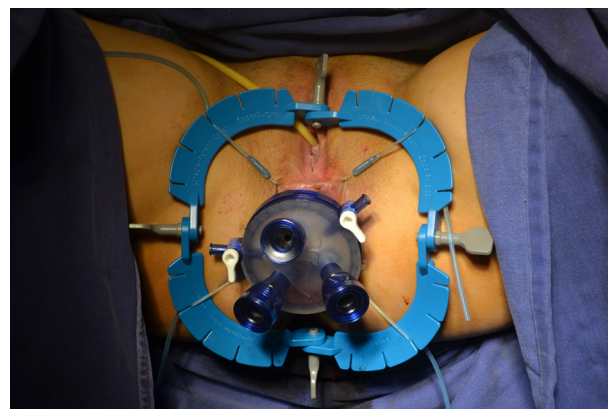


Fig. 1 – Port and trocars.

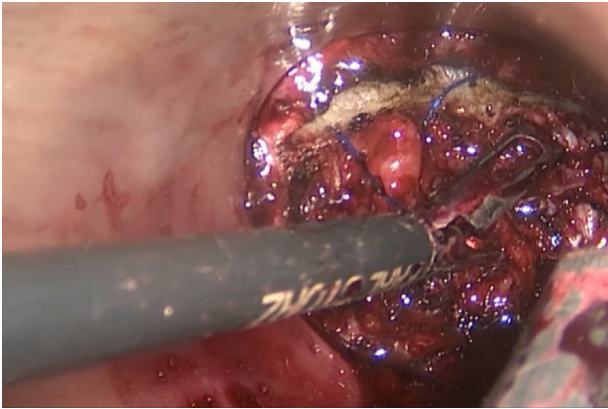


Fig. 2 – Commencing the dissection.

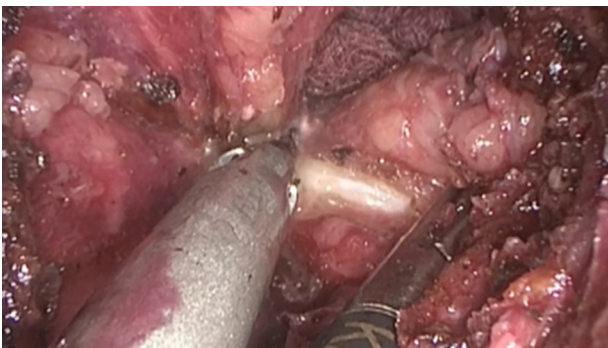


Fig. 3 – Retraction and dissection, with communication with the abdominal team (sponge).

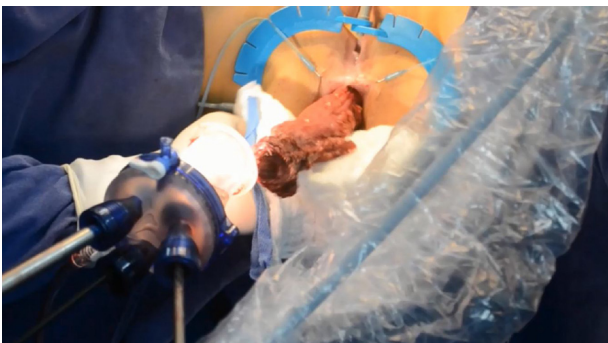

Fig. 4 – Transanal extraction of the specimen.

transanally (Fig. 4). The J-pouch is then created, by standard stapling, after bringing the ileum out through the stoma site, and the anvil of the stapling device is sutured and connected to an extender, usually a number 18 Foley catheter (Fig. 5). A full thickness purse string suture is then placed in the remaining rectal cuff. We recommend a strong suture with 0 prolene, that allows strong traction without tissue rupture. This is also examined to ensure that the vagina is not incorporated in the females. The anvil with its extender, as shown in Fig. 5, is placed in the pouch and the proximal purse string is secured.

The pouch is then returned to the peritoneal cavity. The patient is positioned in the right side up position to ensure that

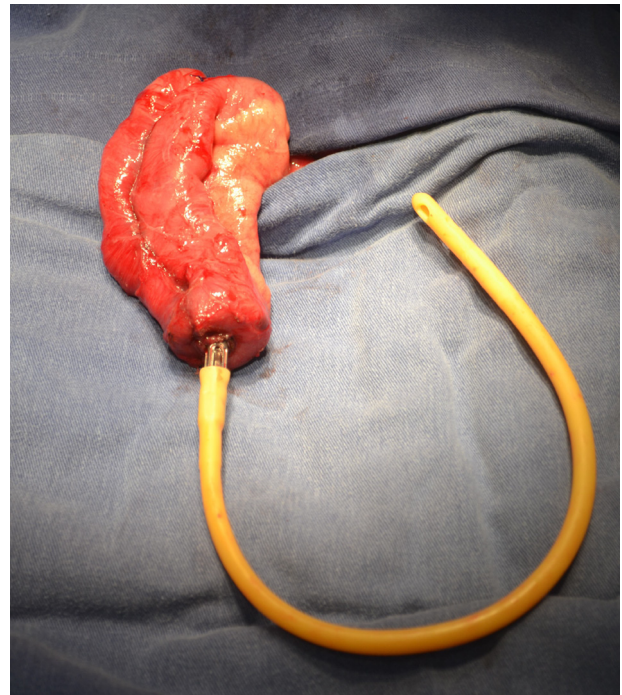


Fig. 5 – Pouch creation at stoma site, extensor and anvil.

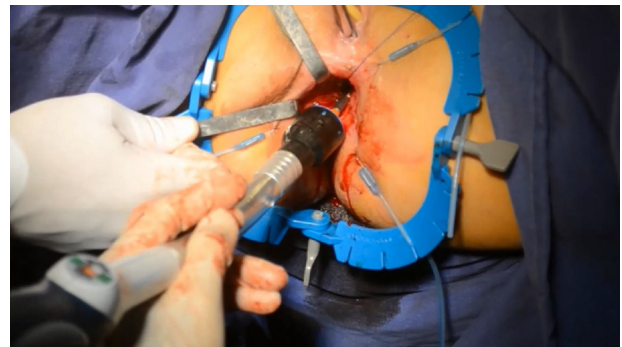


Fig. 6 – Stapling anastomosis.

all segments of small bowel lie on the left side and the mesentery is clearly visible and no small bowel is trapped under the mesentery. This also allows adequate visualisation to ensure there is no twist in the pouch. The extender is then passed to the rectal operator who places a Babcock forceps through the anus and retrieves the extender. The pouch then follows into the pelvis and the abdominal operator ensures that the vagina in the female and the vesicles in the male are free of the distal end of the pouch. It is also important to ensure there is no twist in the pouch. Once the anvil of the stapler is visible the distal purse string is secured and the head of the stapler is connected (Fig. 6). It is important to ensure that there is an audible click to ensure that the anvil and the head of the stapler are firmly connected. The anvil is then closed into the head and the stapler is fired. The donuts are examined. The anastomosis can be reinforced with 3-0 vicryl/PDS sutures to ensure that it is circumferentially closed, especially in the event of an incomplete donut. A pelvic drain is placed at the left iliac fossa 5 mm tro-

car site, and usually a loop ileostomy is matured in the single port site at the right lower quadrant.

Comments and final messages

Minimally invasive surgery for inflammatory bowel diseases should be the mainstay, not only for the cosmetic benefits for the predominantly young population but also for many other clinical reasons. Minimally invasive procedures are recommended for total colectomy with or without completion proctectomy in the European Crohn's and Colitis Organisation (ECCO) guidelines, owing to reduced hospital stay, faster return to normal activities and enhanced recovery pathways.⁷ Single-port approaches can also be technically feasible and performed in this group of patients and the advantages such as reduced conversion rates and reduced pain relief requirements have recently been described.

There can be technical differences between the transanal approach to rectal excision between patients with low rectal cancer and ulcerative colitis without dysplasia. In patients with cancer, the transanal total mesorectal excision (TaTME) is the approach of choice, with full excision of the mesorectum based on sound oncologic principles.⁸ This technique is being adopted worldwide as an alternative to the abdominal dissection of the rectum, that can be sometimes challenging and time consuming. In the management of ulcerative colitis, a close rectal dissection can be performed, if there are no signs of cancer or dysplasia in the rectum.^{9,10} This is due to the possibility of having smaller pre-sacral sinuses in cases of ileo anal anastomotic dehiscence. One prospective study demonstrated that the close rectal dissection was associated with lower complication rates as compared to TME.⁹ On this basis, for benign diseases where rectal resection is required close rectal dissection can be recommended.⁷

A case series including 16 patients with the double single-port approach for ulcerative colitis was recently published.⁵ The early surgical complication rate (up to 30 days after the procedure), was acceptable and comparable with other minimally invasive approaches. Based on the Clavien and Dindo classification of complications, four patients had grade 1, one patient had grade 2 and one patient had grade 3 complication. Five patients had minor complications (31.25%) and one patient had an anastomotic leakage 2 weeks after the procedure, and was considered to have a major complication. All the cases from this series were operated with the TaTME approach, and close rectal dissection was not performed.

In summary, double single port transanal pouch surgery is technically feasible and is an interesting alternative approach for the surgical management of ulcerative colitis. This approach offers the opportunity to perform a pure laparoscopic operation in all patients which has the potential benefit of better outcomes for patients where rectal dissection can be difficult from the abdomen. If this is extrapolated beyond the immediate benefits of laparoscopy, the technique has the potential to reduce the hybrid procedures where the rectal

dissection is performed via an abdominal incision. This has the potential to improve fertility rates after pouch surgery as the reduced fertility rates are mostly directly related to pelvic adhesions from open surgery. More prospective studies comparing the TaTME approach with the close rectal dissection can clarify the best alternative for patients with ulcerative colitis. Combining the transanal approach with an abdominal single-port results in better cosmesis and less surgical trauma, with faster recovery. More prospective studies are warranted in order to firmly demonstrate the benefits of this procedure and place it as a procedure of choice for IPAA.

Conflicts of interest

The authors declare no conflicts of interest.

REFERENCES

1. Bach SP, Mortensen NJ. Revolution and evolution: 30 years of ileoanal pouch surgery. *Inflamm Bowel Dis.* 2006;12:131–45.
2. Baek SJ, Dozois EJ, Mathis KL, Lightner AL, Boostrom SY, Cima RR, et al. Safety, feasibility, and short-term outcomes in 588 patients undergoing minimally invasive ileal pouch-anal anastomosis: a single-institution experience. *Tech Coloproctol.* 2016;20:369–74.
3. de Buck van Overstraeten A, Wolthuis AM, D'Hoore A. Transanal completion proctectomy after total colectomy and ileal pouch-anal anastomosis for ulcerative colitis: a modified single stapled technique. *Colorectal Dis.* 2016;18:O141–4.
4. Roumen RM, Rahusen FT, Wijnen MH, Croiset van Uchelen FA. "Dog ear" formation after double-stapled low anterior resection as a risk factor for anastomotic disruption. *Dis Colon Rectum.* 2000;43:522–5.
5. Leo CA, Samaranyake S, Perry-Woodford ZL, Vitone L, Faiz O, Hodgkinson JD, et al. Initial experience of restorative proctocolectomy for ulcerative colitis by transanal total mesorectal rectal excision and single-incision abdominal laparoscopic surgery. *Colorectal Dis.* 2016;18:1162–6.
6. Coffey JC, Dillon MF, O'Driscoll JS, Faul E. Transanal total mesocolic excision (taTME) as part of ileoanal pouch formation in ulcerative colitis – first report of a case. *Int J Colorectal Dis.* 2016;31:735–6.
7. Øresland T, Bemelman WA, Sampietro GM, Spinelli A, Windsor A, Ferrante M, et al. European Crohn's and Colitis Organisation (ECCO). European evidence based consensus on surgery for ulcerative colitis. *J Crohns Colitis.* 2015;9:4–25.
8. Wolthuis AM, Bislenghi G, de Buck van Overstraeten A, D'Hoore A. Transanal total mesorectal excision: towards standardization of technique. *World J Gastroenterol.* 2015;21:12686–95.
9. Bartels SA, Gardenbroek TJ, Aarts M, Ponsioen CY, Tanis PJ, Buskens CJ, et al. Short-term morbidity and quality of life from a randomized clinical trial of close rectal dissection and total mesorectal excision in ileal pouch-anal anastomosis. *Br J Surg.* 2015;102:281–7.
10. de Zeeuw S, Ahmed Ali U, van der Kolk MB, van Laarhoven KC. Ileal pouch anal anastomosis with close rectal dissection using automated vessel sealers for ulcerative colitis: a promising alternative. *Dig Surg.* 2011;28:345–51.