



Original Article

Influence of the application of enemas with oily extract of curcumin (*Curcuma longa*) on the tissue content of neutral and acidic mucins in the colonic mucosa without fecal stream☆



Carlos Augusto Real Martinez^{a,b,*}, Vitor Piquera de Oliveira^a, Fabio Guilherme Campos^c, Danilo Toshio Kanno^a, Oscar Orlando Araya Fernandez^a, Caled Jaoudat Kadri^a, José Aires Pereira^d

^a Universidade São Francisco (USF), Programa de Pós-Graduação em Ciências da Saúde, Bragança Paulista, SP, Brazil

^b Universidade Estadual de Campinas (UNICAMP), Departamento de Cirurgia, Campinas, SP, Brazil

^c Universidade de São Paulo (USP), Faculdade de Medicina, São Paulo, SP, Brazil

^d Universidade São Francisco (USF), Disciplina de Patologia, Bragança Paulista, SP, Brazil

ARTICLE INFO

Article history:

Received 29 August 2017

Accepted 30 August 2017

Available online 22 September 2017

Keywords:

Colitis

Mucins

Fatty acids, volatile

Image processing,

computer-assisted

ABSTRACT

Purpose: To verify if the application of enemas containing oily extracts of curcumin preserves the tissue content of mucins in the glands of the colonic mucosa without fecal stream.

Method: Thirty-six Wistar rats were submitted to diversion of the fecal stream by proximal colostomy and distal mucous fistula. The animals were subdivided into three groups, and accordingly received enemas with saline and oily extract of curcumin at concentrations of 50 mg/kg/day or 200 mg/kg/day. After two or four weeks of intervention, the irrigated colic segments were removed. Neutral and acidic mucins were identified by Periodic-acid Schiff and Alcian-Blue techniques, respectively. The content of both mucin subtypes was measured by computerized morphometry. Mann-Whitney test was used to analyze the results, adopting a significance level of 5% ($p \leq 0.05$).

Results: There was an increase in the tissue content of neutral mucins in animals treated with curcumin at a concentration of 50 mg/kg/day for four weeks, whereas in the group treated with 200 mg/kg/day there was an increase independent of the time of intervention. The content of acidic mucins increased in animals treated with 200 mg/kg/day regardless of the intervention time, whereas in those treated with 50 mg/kg/day an increase was observed only after four weeks.

☆ Study conducted at Universidade São Francisco (USF), Programa de Pós-Graduação em Ciências da Saúde, Laboratório de Investigação Médica (LIM), Bragança Paulista, SP, Brazil.

* Corresponding author.

E-mail: carmartinez@uol.com.br (C.A. Martinez).
<https://doi.org/10.1016/j.jcol.2017.08.002>

2237-9363/© 2017 Sociedade Brasileira de Coloproctologia. Published by Elsevier Editora Ltda. This is an open access article under the CC BY-NC-ND license (<http://creativecommons.org/licenses/by-nc-nd/4.0/>).

Conclusion: Enemas with curcumin preserve the content of neutral and acidic mucins in the colonic epithelium without fecal stream.

© 2017 Sociedade Brasileira de Coloproctologia. Published by Elsevier Editora Ltda. This is an open access article under the CC BY-NC-ND license (<http://creativecommons.org/licenses/by-nc-nd/4.0/>).

Influência da aplicação de clisteres contendo extrato oleoso de curcumina (*Curcuma longa*) no conteúdo tecidual de mucinas neutras e ácidas na mucosa cólica sem trânsito intestinal

R E S U M O

Palavras-chave:

Colite
Mucinas
Ácidos graxos de cadeia curta, voláteis
Análise de imagem assistida por computador

Objetivo: Verificar se a aplicação de clisteres com extrato oleoso de curcumina preserva o conteúdo de mucinas nas glândulas da mucosa cólica sem trânsito intestinal.

Método: Trinta e seis ratos Wistar foram submetidos à derivação intestinal por colostomia proximal e fistula mucosa distal. Os animais foram subdivididos em três grupos, segundo receberem clisteres com soro fisiológico 0,9%, extrato oleoso de curcumina nas concentrações de 50 mg/kg/dia ou 200 mg/kg/dia. Após duas ou quatro semanas de intervenção foram removidos os segmentos cólicos irrigados. As mucinas neutras e ácidas foram identificadas pelas técnicas do PAS e Alcian-Blue, respectivamente. O conteúdo tecidual de ambos os subtipos de mucinas foi mensurado por morfometria computadorizada. Utilizou-se teste de Mann-Whitney para análise dos resultados adotando-se nível de significância de 5% ($p \leq 0,05$).

Resultados: Houve aumento no conteúdo de mucinas neutras nos animais tratados com curcumina na concentração de 50 mg/kg/dia por quatro semanas, enquanto nos tratados com 200 mg/kg/dia houve aumento independente do tempo de intervenção. O conteúdo de mucinas ácidas aumentou nos animais tratados com 200 mg/kg/dia independente do tempo de intervenção, enquanto nos tratados com 50 mg/kg/dia encontrou-se aumento apenas após quatro semanas.

Conclusão: Clisteres com curcumina preservam o conteúdo de mucinas neutras e ácidas no epitélio cólico sem trânsito intestinal.

© 2017 Sociedade Brasileira de Coloproctologia. Publicado por Elsevier Editora Ltda. Este é um artigo Open Access sob uma licença CC BY-NC-ND (<http://creativecommons.org/licenses/by-nc-nd/4.0/>).

Introduction

The mucus layer that covers the colic epithelium represents the first line of defense against the aggression caused by antigens, virus, and bacteria in the intestinal lumen.^{1,2} Mucins, the main constituents of the mucus layer, are glycoproteins synthesized by goblet cells.^{3,4} The mucin molecule is formed by a glycidic fraction and by another protein fraction. Depending on the components present in the glycidic portion, they are subdivided into neutral mucins rich in glycogen, and into acidic mucins rich in sialic acid.^{1,4} Acidic mucins, on the other hand, are subdivided into sulfomucines when there is a predominance of the sulfate anion in its molecule, or into sialomucins when sialic acid is the predominant carbohydrate.^{1,4,5} In addition to providing mechanical protection, the mucins have a lubricating action, facilitating the progression of fecal contents throughout the colon. Mucins slow the diffusion of hydrogen ions, inhibit the activation of pepsinogen, and exert an antibacterial action against pathogenic bacteria that occur inside the colon. In this way, mucins are considered as the first line of defense of the colonic epithelium.⁶ Short chain fatty acids (SCFA) represent the main

energy substrate for goblet cells to produce adequate amounts of mucus, in order to maintain the integrity of this first line of mechanical defense.^{7,8} Deficiencies in the regular supply of SCFA decrease the expression of those genes responsible for the translation of the protein fraction of the glycoprotein molecule.^{2,7} Important changes in the constitution of mucins in bacterial colitis, inflammatory bowel disease (IBD), adenomatous polyps, colorectal cancer and, more recently, in diversion colitis (DC) have been described.^{1,4,7-9} Studies using experimental models of DC have shown that there is a reduction in the content of neutral mucins, acidic mucins, sulfomucines, and sialomucins in epithelial glands devoid of the normal supply of SCFA.^{1,4,5} It was also demonstrated that in experimental DC, the reduction in the content of the different types of mucins is directly related to the higher levels of tissue oxidative stress, due to the greater production of reactive oxygen species (ROS) from the colonic mucosal epithelial cells devoid of a regular supply of SCFA.^{4,10} Considering these findings, the application of substances with antioxidant activity in the excluded colon would constitute an interesting strategy to avoid the occurrence of epithelial damage and, consequently, to preserve the protection conferred by the layer of mucus.¹⁰ Subsequently, studies in experimental models of

DC confirmed this possibility by showing that the application of enemas with different antioxidant substances was able to reduce the colonic mucosal damage caused by ROS, decrease the tissue inflammatory infiltrate, and increase the mucin content in the colic epithelium devoid of intestinal transit.¹¹⁻¹⁴ Curcumin is the main active ingredient obtained from the *Curcuma longa* rhizome extract.¹⁵ This natural flavonoid has important antioxidant, anti-inflammatory, and anti-neoplastic activity.^{15,16} These properties have resulted in an increasing use of this substance in different diseases whose common denominator is the presence of oxidative stress and inflammation.¹⁶ It has already been demonstrated that the administration of curcumin brings promising results as a complementary therapy in patients with IBD.¹⁷ Experimental studies have shown that the preventive application of curcumin-containing enemas has improved mucosal inflammation and preserved sulfomucine and sialomucine contents and also the main constituent proteins of the intercellular occlusion junctions in an experimental model of DC.¹⁸⁻²⁰ Ultimately, these findings suggest that the antioxidant action of the substance is able to maintain the integrity of the mucus barrier of the colonic epithelium against the deleterious action of ROS.

Although the effects of curcumin have already been demonstrated in DC models, to date, no study has evaluated the substance's ability to preserve the content and expression pattern of neutral and acidic mucins in experimental models of EC. Thus, the aim of the present study was to evaluate the efficacy of curcumin-containing enemas in the reduction of the inflammatory process and in the maintenance of the neutral and acidic mucin content in the glands of the colononic mucosa excluded from intestinal transit.

Materials and methods

This study is in accordance with the guidelines of the Colégio Brasileiro de Experimentação Animal (COBEA). The Research Project was approved by the Comitê de Ética no Uso de Animal em Pesquisa (CEUA) of the Universidade São Francisco, Bragança Paulista, São Paulo (No. 002.04.10).

Experimental animal

Thirty-six male Wistar rats (*Rattus norvegicus albinus*) from Anilab, Animais de Experimentação Criação e Comércio Ltda., Paulínia, São Paulo, Brazil, were used. The animals' weight ranged from 300 to 320g and on average they aged four months.

Experimental groups

Three groups were studied with 12 animals each, divided into the daily application of enemas with 0.9% physiological solution (PS) and of curcumin oily extract (Sigma Aldrich do Brasil Ltda., São Paulo, Brazil) at concentrations of 50 mg/kg/day and 200 mg/kg/day, respectively. Six animals from each group were submitted to euthanasia after two weeks of intervention; the remaining animals were sacrificed after four weeks.

Surgical procedure

On the day of the intervention, the animals were weighed and anesthetized with 2% xylazine hydrochloride (Anasedan PET-Ceva Saúde Animal Ltda, Paulínia, São Paulo) and ketamine hydrochloride (Dopalen PET-Ceva Saúde Animal Ltda, Paulínia) at a dose of 0.1 mL/100 g intramuscularly. Then, the rats were placed on a surgical board, in a horizontal dorsal decubitus position for trichotomy followed by antisepsis. The laparotomy was performed by means of a median incision with 3 cm of extension and, after a cavity inventory, the Peyer's patch at the transition between the rectum and the sigmoid was identified. With the aid of a pachymeter, the left colon was sectioned 6 cm above the patch. The proximal colon was externalized as a terminal colostomy in the left hypochondrium. After the preparation of the proximal stoma, the caudal segment of the sectioned colon was catheterized and irrigated with 40 mL of saline heated at 37 °C until the effluent drained through the anus of the animal showed absence of stool output. After cleansing, the catheter was removed and the distal colon externalized in the form of a mucous fistula in the left iliac fossa. The abdominal wall synthesis was made by planes.

At the end of the operation, the animals were kept warm and, after returning to a waking state, were housed in individual cages, with water intake and standardized ration (Nuvilab CR1[®]) *ad libitum*. The rats were isolated until euthanasia time (two or four weeks), in the same environmental conditions of humidity, luminosity and temperature of the preoperative period. No additional care was taken with respect to operative wound or stomata; the rats received only one analgesic administered in the drinking water in the first three days after the operation (Dipirona PET, Biovet Ltda, Vargem Grande Paulista, São Paulo).

Intervention with proposed solutions

The animals were submitted daily to the application of enemas with the proposed solutions, according to the group to which they belonged. The use of the substances was always performed using a polyethylene catheter 14 F (internal diameter) graduated in centimeters. The catheter was introduced by the animal's anus at a standard depth of 2 cm from the anal border. Next, the enema containing the intervention solution proposed for each experimental group was applied until the solution drained through the distal mucous fistula. The intervention solutions were applied manually in 30 s with the aid of a syringe.

Collection of material

On the day before the date of euthanasia (2 or 4 weeks), the animals were fasted again. All received the application of the enema with the intervention solution in the morning of the scheduled date for euthanasia, always performed in the afternoon. For the removal of the colic segments to be studied, the animals were anesthetized with the same technique previously described. After laparotomy and release of adhesions (when present), the entire colon devoid of fecal stream, including the colostomy and anus, was removed. After colonic

removal, the animals were sacrificed with an intracardiac infusion of a lethal dose of thiopental.

Histological techniques

The removed colic segment was opened through the antimesenterial border, and washed with saline to remove fecal residues. A longitudinal segment of the excluded colon from each animal, measuring 30 mm in length, was fixed on a cork piece so that the fragment was stretched and then immersed in 10% buffered formaldehyde solution for 72 h. Once this period has elapsed, the specimens were dehydrated in alcohol and diaphanized in xylene. The material was embedded in paraffin blocks. In each block three 4- μ m thick longitudinal slices were obtained perpendicularly to the mucosal surface for assembly of the slides.

The first slide was stained by the hematoxylin–eosin (HE) technique to evaluate the histological changes found (presence of colitis). The second slide was stained by the Periodic Acid-Schiff (PAS) histologic technique, with the aim of identifying the neutral mucins, while the third slide was stained with the Alcian Blue (AB) technique to identify the acidic mucins. With the techniques used, the neutral mucins were stained in magenta, while the acidic mucins stained blue.

All the slides were analyzed by the same pathologist with experience in IBD who was unaware of the origin of the material. For the study of the slides, an optical microscope (Eclipse DS-50i, Nikon Inc., Osaka, Japan) was used. The images obtained at each selected focal field were captured by a camera (DS-Fi-50; Nikon Inc, Osaka, Japan) previously attached to the microscope and then digitized and stored for later computerized morphometric analysis.

The diagnosis of DC was considered in the face of the following findings: loss of epithelial surface; the presence of inflammatory infiltrates, and the presence of mucosal edema. For each variable a value (in crosses) was assigned that varied from zero to 3 crosses: (0 = absent, 1 = slight, 2 = moderate, and 3 = severe). For each animal, three different histological fields were read. The median obtained by the sum of the variables found in each animal after the readings of the three distinct fields resulted in the inflammatory graduation score.

Quantification of mucin content by computer assisted image analysis

Quantification of tissue content of mucin subtypes was done using a computer-aided image processing system (NIS-Elements, version 3.0, Nikon Inc., Japan). The program analyzed the images previously stored in the system. In each image, after selecting the histological field to be analyzed, the program determined the entire spectrum of the chosen color by color histograms with the use of a RGB (red, green, blue) system. After quantifying the content of the acidic mucins, always stained in a blue shade, the program automatically transformed every spectrum of the blue color in a percentage of pixels, with the calculation of the number of pixels in each histological field analyzed. Likewise, to determine the content of the neutral mucins stained in magenta by the PAS technique, the program identified the entire spectrum of colors containing the magenta shade. The evaluation of the con-

tents of each subtype of mucin was always carried out in a focal field in which it was possible to identify three contiguous and intact colonic glands. The final value considered for the content of neutral and acidic mucins in each animal was the average obtained after reading three different histological fields. The final content was always the average of the three readings, being expressed in percentage values per field (%/field).

Statistical analysis

The results obtained were analyzed by the application of the Biostat Program, version 5.0. The values for the inflammatory scores were expressed as a median. For the comparison of the inflammatory scores found in the three experimental groups, the median test was applied. Significant values for the inflammatory score were compared, with the assignment of one triangle (Δ) when $p < 0.05\%$, or of two triangles ($\Delta\Delta$) when $p < 0.01\%$. The values found in the content of neutral or acidic mucins in each experimental group were always expressed by mean values, with the respective standard error. The comparison of the neutral and acidic mucins contents among the three experimental groups was also done in a paired form (i.e., by comparing two groups at a time) by the use of the Mann-Whitney test. The significance level of 5% ($p \leq 0.05$) was adopted. Significant values for the content of both mucin subtypes were found in the comparison between the animals submitted to the intervention with curcumin (independent of the concentration used) versus animals submitted to intervention with saline. The significant values found for the contents of both mucin subtypes, when compared to the animals submitted to the intervention with both concentrations of curcumin (50 mg/kg/day and 200 mg/kg/day) were always identified with a cross (\dagger).

Results

Fig. 1A shows the mucosal surface obtained from the colon treated with PS for two weeks, while Fig. 1B shows the excluded colon submitted to the intervention with curcumin oily extract at a concentration of 200 mg/kg/day for the same period of time.

Fig. 2A shows the distribution of the neutral mucins in the animals submitted to saline intervention for two weeks, while Fig. 2B shows the distribution of the neutral mucins after the intervention with curcumin oily extract at a concentration of 200 mg/kg/day for the same period of time.

Fig. 3A shows the distribution pattern of acidic mucins in animals submitted to PS intervention for two weeks, while Fig. 3B shows the distribution of acidic mucins in the colonic mucosa submitted to the intervention with curcumin oily extract at the concentration of 200 mg/kg/day.

Table 1 compares the inflammatory score and tissue content of neutral and acidic mucins in animals submitted to saline intervention versus curcumin at concentrations of 50 mg/kg/day and 200 mg/kg/day, after two weeks or four weeks of intervention.

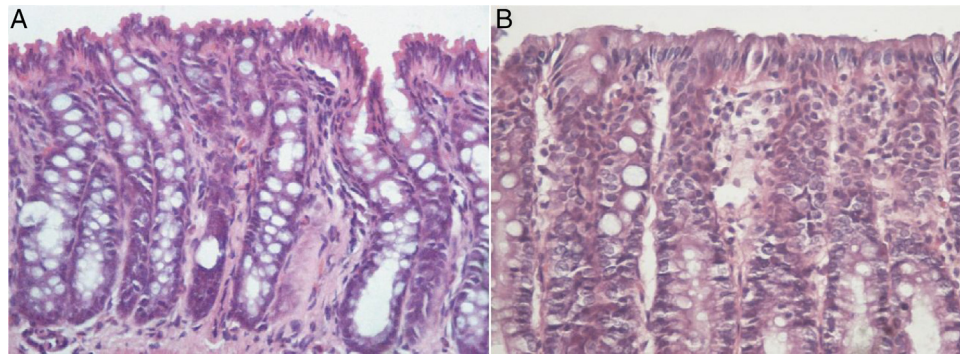


Fig. 1 – (A) Colonic mucosa devoid of fecal stream of animal submitted to the intervention with PS for four weeks. Note the irregularity of the mucosal surface, tortuosity of crypts, inflammatory infiltrate, and edema; **(B)** colonic mucosa devoid of fecal stream in an animal submitted to intervention with curcumin at a concentration of 200 mg/kg/day for four weeks. The epithelial surface is shown to integrate the aligned colonic crypts, with less edema between the colic glands (HE: 200×).

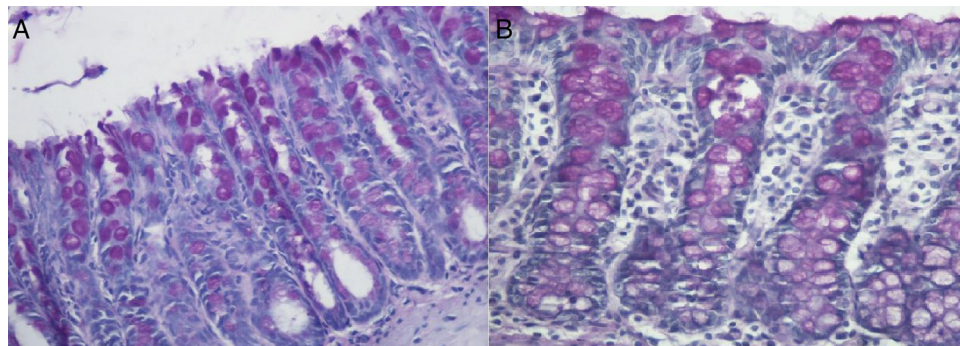


Fig. 2 – (A) Tissue expression of neutral mucins in the colonic mucosa devoid of fecal stream of an animal submitted to the saline intervention for two weeks. Note the atrophy of crypts and the reduction of the neutral mucin content in goblet cells; **(B)** tissue expression of neutral mucins in the colonic mucosa devoid of fecal stream in an animal submitted to intervention with curcumin at a concentration of 50 mg/kg/day for two weeks. We can observe a higher content of neutral mucins in the colic glands (PAS: 200×).

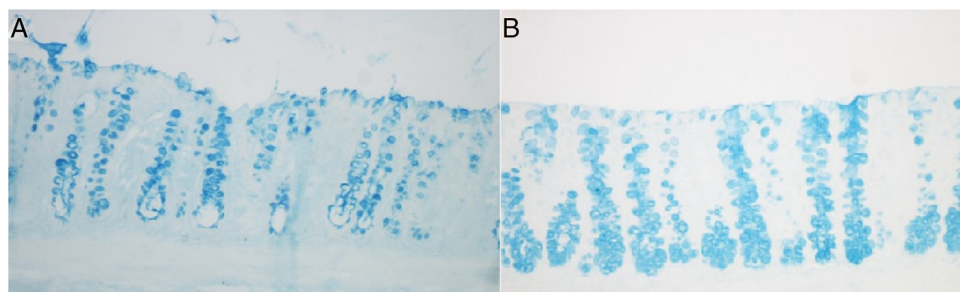


Fig. 3 – (A) Tissue expression of acidic mucins in the colonic mucosa without of an animal submitted to saline intervention for four weeks. One can note a significant reduction in the content of acidic mucins, mainly in the bottom of the colic glands; **(B)** tissue expression of acidic mucins in the colonic mucosa devoid of fecal stream of an animal submitted to curcumin at a concentration of 200 mg/kg/day for four weeks. One can observe an increase in the content of acidic mucins, especially in the deeper regions of the colic glands (AB: 200×).

Table 1 – Inflammatory score and tissue content of neutral and acidic mucins in animals submitted to intervention with PS and curcumin at dosages of 50 mg/kg/day and 200 mg/kg/day after two and four weeks.

	Physiological solution		Curcumin 50 mg/kg/day		Curcumin 200 mg/kg/day	
	2 w/o	4 w/o	2 w/o	4 w/o	2 w/o	4 w/o
Score	2 ^a	3 ^a	2	1	1	0
Neutral	7.3 ± 0.3	4.3 ± 0.2	5.7 ± 0.1	5.7 ± 0.2 ^b	7.9 ± 0.3 ^{b,c}	8.5 ± 0.4 ^{b,c}
Acidic	9.1 ± 0.3	6.1 ± 0.2	10.2 ± 0.6 ^b	12.0 ± 0.3 ^b	11.8 ± 0.2 ^{b,c}	13.7 ± 0.4 ^{b,c}

^a Physiological solution > curcumin 50 mg/kg/day or 200 mg/kg/day.

^b Curcumin 50 mg/kg/day or curcumin 200 mg/kg/day > physiological solution.

^c Curcumin 200 mg/kg/day > curcumin 50 mg/kg/day.

Discussion

The colic epithelium constitutes the most perfect morpho-functional barrier in living beings. Consisting of a single layer of polarized cells and firmly adhered to each other, the colonic epithelium separates the intestinal content, rich in bacteria and antigens, from the sterile internal environment. This key mechanism is formed by several lines of defense, represented mainly by the gelatinous layer of mucus that covers the intestinal epithelium, by the intricate mechanisms of intercellular junction, and by the basal membrane.¹¹ It is also worth mentioning the presence of a sophisticated immune system by different defense cells and by antibodies. The maintenance of this whole defense system depends on the adequate supply of an energetic substrate to the specialized cells of the intestinal epithelium, so that they can synthesize the proteins constituting the different structures that make up the mucosal barrier.^{20,19}

SCFA constitute the most important energy substrate for the cells of the colic epithelium. These substances are produced from the fermentation of undigested carbohydrates and polysaccharides from the diet by anaerobic microorganisms that are components of the microbiota present in the colon.²¹ Thanks to their high volatility, these substances are rapidly absorbed by the intestinal epithelium; it is estimated that of the total produced, less than 10% are present in the feces.²² Acetic, propionic and butyric acids are the main subtypes formed and are estimated to correspond to more than 95% of all SCFA present in the gastrointestinal tract.²³

The increasing interest in SCFA is related to a increase in scientific evidence regarding its beneficial physiological effects on the organism.²⁴ Among their various properties, it has been demonstrated that SCFA, in particular butyric acid, represent the main substrate used by cells of the colonic epithelium to produce all the energy necessary to the different stages of cellular metabolism dependent on energy expenditure. Among these stages, the gene transcription and synthesis of the different proteins present in cells stand out.²⁵ In the colon, β -oxidation of butyric acid is responsible for the consumption of about 70% of all available oxygen; it has been shown that this is the main fuel used by the cells of the colonic mucosa, for example for protein synthesis of mucins.¹ Studies have also shown that SCFA reduce the levels of oxidative stress in the colic epithelium because, besides reducing ROS production, these substances are able of stimulating the activity of the antioxidant systems present in the tissues.²⁶ On the

other hand, the lack of a SCFA supply, as occurs in the excluded colon, increases ROS production, causing damage to the different defense systems that form the colic epithelial barrier. Oxidative stress has been considered a convincing molecular explanation for the onset of DC.^{10,27}

A number of experimental studies have shown that important modifications occur in the content and expression pattern of the glycidic fractions of mucins in goblet cells present in colonic mucosal glands devoid of the regular supply of SCFA.^{1,4,5} Initially, these authors demonstrated that, in the colonic mucosa devoid of fecal stream, the content of neutral and acidic mucins was depleted, in contrast to what occurred in the mucosa with a preserved transit.¹ And it was showed that this mucin depletion was also maintained with the progression of the exclusion time. The authors hypothesized that the deficiency in SCFA supply, by modifying the mitochondrial energetic metabolism to obtain energy, would increase ROS production, and that the resulting oxidative stress would be the main responsible for reducing the content of the glycidic fractions of the mucin molecules.¹ The same group confirmed the previously described results, showing that the reduction in the total content of the acidic mucins occurred mainly by the reduction of the sialomucins, which practically disappeared after 18 weeks of intestinal exclusion.⁵ In order to verify if the oxidative stress could be related to the reduction of the content of these molecules, in a subsequent study in which the same animals were used the authors demonstrated the occurrence of a progressive increase of the levels of ROS with the course of the time of exclusion. Increased ROS production was related not only to an increased epithelial damage in those segments devoid of fecal transit, but also to the depletion of the content of all subtypes of mucin.¹⁰

The importance of a regular supply of SCFA in the synthesis of mucins was confirmed by studies that analyzed the tissue expression of several genes responsible for the transcription of the protein fractions of mucin.⁸ The results showed that butyrate stimulates the expression of *MUC1*, *MUC2*, *MUC3*, *MUC4*, and *MUC5B*, increasing in six times the expression of *MUC2*, the main gene related to mucin synthesis in colonic epithelium.⁸ These findings confirm the relevance of an adequate supply of SCFA, in particular butyrate, for an adequate synthesis of mucins.

All of these findings suggest that the molecular changes that occur in DC patients are related to the lack of a regular supply of SCFA. The lack of this key energy substrate generates dysfunction in the cellular energy metabolism, which is translated by increases in ROS production. Ultimately, these

cytotoxic radicals are responsible for the destruction of the mucus layer that makes up the epithelial barrier of the colonic mucosa. Thus, the use of substances with antioxidant activity becomes an interesting strategy to reverse the mucosal layer damage caused by ROS in cases of DC. A number of experimental studies seem to confirm this possibility. Substances with antioxidant action, such as n-acetylcysteine and mesalazine were able to reverse oxidative stress and improve the inflammatory process in experimental models of DC.^{13,14} However, the evaluation of the efficacy of the use of antioxidants in the maintenance of the mucin content in the epithelium excluded from fecal transit was only studied later, when two studies evaluated the effects of sucralfate application in an experimental model of DC.^{28,29} The first study evaluated the effects of the application of enemas with sucralfate, a substance with recognized antioxidant activity and which can stimulate the production of mucus by the epithelium of the gastrointestinal tract. The results showed that sucralfate, besides improving the inflammatory process, was able to increase the tissue content of neutral and acidic mucins in the epithelium excluded from fecal transit.²⁸ Soon after, a second study measured the tissue content of acidic mucin subtypes (sulfomucins and sialomucins) in these same animals.²⁹ The results showed that the use of sucralfate-containing enemas increased the total tissue content of the acidic mucins, mainly because this substance increases the content of sialomucins – precisely the subtype of acidic mucin that presents a greater reduction of its content in the epithelium devoid of fecal transit.^{4,5} Recently, in agreement with the findings of these two studies, it has been demonstrated that the use of sucralfate may also be able to increase the tissue content of the MUC2 protein in colonic mucosa devoid of intestinal transit in an experimental model of DC.³⁰ However, the mechanism that explains how this happens is still waiting for an explanation. It is possible that sucralfate may exert an antioxidant effect, protecting the mucosa from oxidative stress; however, one cannot dismiss the possibility that the substance may stimulate the transcription of the MUC2 gene – thereby increasing the content of the corresponding protein fraction.

All these findings have shown that the reduction of oxidative stress levels in the mucosa excluded from fecal transit through the use of antioxidant substances is effective in the treatment of DC. Thus, the use of curcumin, a potent natural antioxidant with therapeutic efficacy in the treatment of IBD – and especially when this substance is associated with other drugs – could become a valid strategy for the treatment of DC.¹⁷ Curcumin, in addition to its antioxidant effect, inhibits the inflammatory pathways by reducing the activity of IL-1 β and COX and modulating the AKT/mTOR pathway that controls cell energy mechanisms.¹⁸ One study proved that the use of a combination therapy with curcumin and mesalamine was shown to be superior *versus* the isolated use of mesalamine in the treatment of patients with IBD.¹⁸ Although there is clinical evidence that curcumin can increase the production of mucins in the colonic epithelium, a single study measured the tissue content of sulfomucins and sialomucins in the colon excluded from fecal stream in an experimental model of DC.²⁰ The authors observed that the application of enemas containing curcumin oily extract not only improved the mucosal inflammatory process, but also increased the content of both acidic

mucin subtypes. The study also showed that this increase in sulfomucine and sialomucine content was related to the concentration used and to the time of intervention.²⁰

The results of the present study confirm the effectiveness of the application of enemas with curcumin in cecal segments deprived of intestinal transit. We observed the occurrence of reduction of the inflammatory score in the animals submitted to the intervention with curcumin *versus* animals of the control group, independent of the concentration used. We also verified that the neutral mucin content in the colon without transit of those animals submitted to PS intervention decreased with the progression of the intervention time. On the other hand, in the animals submitted to the intervention with curcumin, especially in the groups treated with the highest concentration (200 mg/kg/day) and for a longer period of time, the content of neutral mucins increased significantly. When analyzing the tissue content of acidic mucins, we also found a reduction of the content in the animals submitted to the saline intervention, related to the time of exclusion. Conflicting with this finding, the intervention with curcumin, regardless of the concentration used, increased the tissue content of acidic mucins *versus* animals submitted to saline intervention. The increase in the tissue content of acidic mucins in the animals submitted to the intervention with curcumin was related to the use of higher concentrations, especially when applied for a longer interventional period.

The results of the present study confirm the findings of previous studies, showing the benefits of the application of enemas with curcumin oily extract for the treatment of experimental DC. The reduction of the inflammatory process in the mucosa devoid of fecal stream, as well as the increase in the production of both subtypes of mucins, seem to confirm the efficacy of this substance in the treatment of different forms of colitis. However, studies in humans are still necessary to confirm the viability of using enemas containing curcumin for the treatment of these diseases.

Funding

Fundação de Amparo à Pesquisa do Estado de São Paulo (FAPESP). Case Number 2010/12492-7.

Conflicts of interest

The authors declare no conflicts of interest.

REFERENCES

1. Nonose R, Spadari APP, Priolli DG, Máximo FR, Pereira JA, Martinez CAR. Tissue quantification of neutral and acid mucins in the mucosa of the colon with and without fecal stream in rats. *Acta Cir Bras.* 2009;24:267-75.
2. Gaudier E, Hoebler C. Physiological role of mucins in the colonic barrier integrity. *Gastroenterol Clin Biol.* 2006;30:965-74.
3. Mello RO, Silva CM, Fonte FP, Silva DL, Pereira JA, Margarido NF, et al. Evaluation of the number of goblet cells in crypts of the colonic mucosa with and without fecal transit. *Rev Col Bras Cir.* 2012;39:139-45.

4. Martinez CAR, Nonose R, Spadari APP, Máximo FR, Priolli DG, Pereira JA, et al. Quantification by computerized morphometry of tissue levels of sulfomucins and sialomucins in diversion colitis in rats. *Acta Cir Bras*. 2010;25:231-40.
5. Keli E, Bouchoucha M, Devroede G, Carnot C, Ohrant T, Cugnenc PH. Diversion-related experimental colitis in rats. *Dis Colon Rectum*. 1997;40:222-8.
6. Deplancke B, Gaskins HR. Microbial modulation of innate defense: goblet-cells and the intestinal mucus layer. *Am J Clin Nutr*. 2001;73:1131S-41S.
7. Willemsen LE, Koetsier MA, Van Deventer SJ, Van Tol EA. Short chain fatty acids stimulate epithelial mucin 2 expression through differential effects on prostaglandin E1 and E2 production by intestinal myofibroblasts. *Gut*. 2003;52:1442-7.
8. Gaudier E, Rival M, Buisine MP, Robineau I, Hoebler C. Butyrate enemas upregulate MUC genes expression but decrease adherent mucus thickness in mice colon. *Physiol Res*. 2009;58:111-9.
9. Johansson ME, Sjövall H, Hansson GC. The gastrointestinal mucus system in health and disease. *Nat Rev Gastroenterol Hepatol*. 2013;10:352-61.
10. Martinez CAR, Ribeiro ML, Gambero A, Miranda DDC, Pereira JA, Nadal SR. The importance of oxygen free radicals in the etiopathogenesis of diversion colitis in rats. *Acta Cir Bras*. 2010;25:387-95.
11. Pereira JA, Rodrigues MR, Sato DT, Silveira Júnior PP, Dias AM, Silva CG, et al. Evaluation of sucralfate enema in experimental diversion colitis. *J Coloproctol (Rio J)*. 2013;33:182-90.
12. Martinez CAR, Rodrigues MR, Sato DT, Silva CMG, Kanno DT, Mendonça RLS, et al. Evaluation of the anti-inflammatory and antioxidant effects of the sucralfate in diversion colitis. *J Coloproctol*. 2015;35:90-9.
13. Martinez CA, de Almeida MG, da Silva CM, Ribeiro ML, da Cunha FL, Rodrigues MR, et al. Enemas with n-acetylcysteine can reduce the level of oxidative damage in cells of the colonic mucosa diverted from the faecal stream. *Dig Dis Sci*. 2013;58:3452-9.
14. Caltabiano C, Máximo FR, Spadari AP, da Conceição Miranda DD, Serra MM, Ribeiro ML, et al. 5-Aminosalicylic acid (5-ASA) can reduce levels of oxidative DNA damage in cells of colonic mucosa with and without fecal stream. *Dig Dis Sci*. 2011;56:1037-46.
15. Aggarwal BB, Yuan W, Li S, Gupta SC. Curcumin-free turmeric exhibits anti-inflammatory and anticancer activities: identification of novel components of turmeric. *Mol Nutr Food Res*. 2013;57:1529-42.
16. Samarghandian S, Azimi-Nezhad M, Farkhondeh T, Samini F. Anti-oxidative effects of curcumin on immobilization-induced oxidative stress in rat brain, liver and kidney. *Biomed Pharmacother*. 2017;87:223-9.
17. Lang A, Salomon N, Wu JC, Kopylov U, Lahat A, Har-Noy O, et al. Curcumin in combination with mesalamine induces remission in patients with mild-to-moderate ulcerative colitis in a randomized controlled trial. *Clin Gastroenterol Hepatol*. 2015;13:1444-9.
18. Kadri CJ, Pereira JA, Campos FG, Ortega MM, Bragion CB, Martinez CA. Anti-inflammatory effects of enemas containing an oily extract of curcumin in an experimental model of diversion colitis. *Histol Histopathol*. 2017;32:161-9.
19. Martinez CA, Kadri CJ, Kanno DT, Alves Júnior AJJ, Coy CS, Pereira JA. Claudin-3 and occludin content in the glands of colonic mucosa devoid from fecal stream submitted to topical intervention with oil extract of *Curcuma longa*. *Acta Cir Bras*. 2017;32:65-73.
20. Alves AJ, Júnior, Pereira JA, Pansani AH, Magro DO, Coy CS, et al. Tissue sulfomucin and sialomucin content in colon mucosa without intestinal transit subjected to intervention with *Curcuma longa* (curcumin). *Acta Cir Bras*. 2017;32:182-93.
21. Henningsson AM, Bjorck IM, Nyman EM. Combinations of indigestible carbohydrates affect short-chain fatty acid formation in the hindgut of rats. *J Nutr*. 2002;132:3098-104.
22. den Besten G, van Eunen K, Groen AK, Venema K, Reijngoud DJ, Bakker BM. The role of short-chain fatty acids in the interplay between diet, gut, microbiota, and host energy metabolism. *J Lipid Res*. 2013;54:2325-40.
23. Hu J, Lin S, Zheng B, Cheung PC. Short-chain fatty acids in control of energy metabolism. *Crit Rev Food Sci Nutr*. 2016;27:1-7.
24. Tan J, McKenzie C, Potamitis M, Thorburn AN, Mackay CR, Macia L. The role of short-chain fatty acids in health and disease. *Adv Immunol*. 2014;121:91-119.
25. Agarwal VP, Schimmel EM. Diversion colitis: a nutritional deficiency syndrome? *Nutr Rev*. 1989;47:257-61.
26. Hamer HM, Jonkers DM, Bast A, Vanhoutvin SA, Fischer MA, Kodde A, et al. Butyrate modulates oxidative stress in the colonic mucosa of healthy humans. *Clin Nutr*. 2009;28:88-93.
27. Martinez CAR, Fabris FM, Silva CMG, Rodrigues MR, Sato DT, Ribeiro ML, et al. Oxidative stress and changes in the content and pattern of tissue expression of β -catenin protein in diversion colitis. *J Coloproctol*. 2012;32:343-58.
28. Chaim FM, Sato DT, Rodrigues MR, Dias AM, Silveira Júnior PP, Pereira JA, et al. Evaluation of the application of enemas containing sucralfate in tissue content of neutral and acid mucins in experimental model of diversion colitis. *Acta Cir Bras*. 2014;29:544-52.
29. Bonassa CE, Pereira JA, Campos FG, Rodrigues MR, Sato DT, Chaim FD, et al. Tissue content of sulfomucins and sialomucins in the colonic mucosa, without fecal stream, undergoing daily intervention with sucralfate. *Acta Cir Bras*. 2015;30:328-38.
30. Fernandez OOA, Pereira JA, Campos FG, Araya CM, Marinho GE, Novo RS, et al. Evaluation of enemas containing sucralfate in tissue content of MUC-2 protein in experimental model of diversion colitis. *ABCD Arq Bras Cir Dig*. 2017;30:132-8.