



Original Article

Technique and results of the first six cases of anal sphincteroplasty with Deoti's flap for complex anatomical deformity of the perineum



Beatriz Deoti Silva Rodrigues^{a,*}, Igor Guedes Nogueira Reis^b, Isabelle Reis Daldegan^c, Kelly Cristine de Lacerda Rodrigues Buzatti^d

^a Universidade Federal de Minas Gerais (UFMG), Faculdade de Medicina, Departamento de Cirurgia, Belo Horizonte, MG, Brazil

^b Universidade Federal de Minas Gerais UFMG, Belo Horizonte, MG, Brazil

^c Universidade Federal de Juiz de Fora UFJF, Juiz de Fora, MG, Brazil

^d Universidade Federal de Minas Gerais (UFMG), Hospital das Clínicas, Belo Horizonte, MG, Brazil

ARTICLE INFO

Article history:

Received 2 March 2018

Accepted 7 March 2018

Available online 5 April 2018

Keywords:

Colorectal surgery

Surgical flaps

Fecal incontinence

Treatment outcome

Perineum

ABSTRACT

Objectives: Anal sphincteroplasty with Deoti's flap is a recently published procedure for the treatment of fecal incontinence with severe perineal deformity. The aim of this study is to report six cases of patients, analyzing their results in fecal incontinence questionnaires and proposing a new scale to better assess our technique's main objective, the reconstruction of the perianal anatomy.

Methods: Six patients were submitted to anal sphincteroplasty with Deoti's flap and follow-up was performed every six months. Functional results and Quality of Life were measured by Wexner Score and Fecal Incontinence Quality of Life Scale, respectively.

Results: All operations were carried out without failure to perform Deoti's flap rotation. The sample presented medians of 18.5 and 3.5 on Wexner Score, before and after surgery, respectively. In the Fecal Incontinence Quality of Life Scale, the medians before and after surgery are, respectively, 1.75 and 3.35 (Scale 1), 1.54 and 2.60 (Scale 2), 2.35 and 3.28 (Scale 3), 1.49 and 3.33 (Scale 4). The *p*-values were 0.0173 for Wexner Score and 0.0260, 0.0411, 0.0368 and 0.0952 for Scales 1, 2, 3 and 4 of Fecal Incontinence Quality of Life Scale, respectively. All patients presented sustained improvement in Wexner Score and in quality of life questionnaire (in all scales of Fecal Incontinence Quality of Life Scale).

Conclusions: Deoti's surgical flap with sphincteroplasty successfully reconstructs complex anatomical deformities of the perineum. Current questionnaires to assess fecal incontinence may not evaluate properly the anatomical result of the technique, thus we propose a visual scale. In addition, sphincteroplasty with Deoti's flap may have longer-term outcomes in functional results than sphincteroplasty alone.

© 2018 Sociedade Brasileira de Coloproctologia. Published by Elsevier Editora Ltda. This is an open access article under the CC BY-NC-ND license (<http://creativecommons.org/licenses/by-nc-nd/4.0/>).

* Corresponding author.

E-mail: bdeoti@gmail.com (B.D. Rodrigues).

<https://doi.org/10.1016/j.jcol.2018.03.003>

2237-9363/© 2018 Sociedade Brasileira de Coloproctologia. Published by Elsevier Editora Ltda. This is an open access article under the CC BY-NC-ND license (<http://creativecommons.org/licenses/by-nc-nd/4.0/>).

Técnica e resultados dos primeiros seis casos de esfínteroplastia anal com retalho Deoti para deformidade anatômica complexa do períneo

R E S U M O

Palavras-chave:

Cirurgia colorretal
Retalhos cirúrgicos
Incontinência fecal
Resultado do tratamento
Períneo

Objetivos: A esfínteroplastia anal com retalho Deoti é um procedimento publicado recentemente para o tratamento de deformidade perineal grave. O objetivo deste estudo é relatar seis pacientes, analisando seus resultados em questionários de incontinência fecal e propondo uma nova escala para avaliar melhor o objetivo principal da nossa técnica, a reconstrução da anatomia perianal.

Métodos: Seis pacientes foram submetidos à esfínteroplastia anal com retalho de Deoti e o acompanhamento foi realizado a cada seis meses. Os resultados funcionais e a qualidade de vida foram medidos pelas Escalas Wexner Score e FIQL, respectivamente.

Resultados: Não houve falhas na rotação do retalho Deoti. A amostra apresentou medianas de 18,5 e 3,5 na Wexner Score, antes e depois da cirurgia, respectivamente. Na Escala FIQL, as medianas antes e depois da cirurgia são, respectivamente, 1,75 e 3,35 (Escala 1); 1,54 e 2,60 (Escala 2); 2,35 e 3,28 (Escala 3); 1,49 e 3,33 (Escala 4). Os valores de p foram 0,0173 para Wexner Score e 0,0260; 0,0411; 0,0368 e 0,0952 para Escalas 1; 2; 3 e 4 de FIQL, respectivamente. Todos os pacientes apresentaram melhora sustentada na pontuação de Wexner e no questionário de qualidade de vida (em todas as escalas do FIQL).

Conclusões: O retalho de Deoti com esfínteroplastia reconstrói com sucesso as deformidades anatômicas complexas do períneo. Os questionários atuais para avaliar a incontinência fecal podem não avaliar adequadamente o resultado anatômico da técnica, por isso propomos uma escala visual. Além disso, a esfínteroplastia com retalho de Deoti pode apresentar resultados funcionais mais duradouros do que a esfínteroplastia isolada.

© 2018 Sociedade Brasileira de Coloproctologia. Publicado por Elsevier Editora Ltda. Este é um artigo Open Access sob uma licença CC BY-NC-ND (<http://creativecommons.org/licenses/by-nc-nd/4.0/>).

Introduction

Fecal incontinence (FI) is the involuntary loss of gas, liquid or solid stool and causes negative impact on patient's quality of life.¹ Its incidence remains unknown, mainly because of patient's embarrassment in reporting symptoms.² Anal continence depends on anatomical mechanisms (Internal Anal Sphincter – IAS; External Anal Sphincter – EAS; Corrugator cutis ani muscle and the Perivascular ring) functioning in synchrony, and also on the feces' consistency and volume.¹ Many factors related to abnormal sphincter mechanism can lead to FI and they can be grouped in major etiology groups: pelvic floor denervation, congenital abnormalities, miscellaneous and, the most common, trauma, specifically obstetric trauma.²

Several questionnaires evaluate quantitatively and qualitatively FI and also Quality of Life (QoL). The most used are the Jorge & Wexner Fecal Incontinence Score and the Fecal Incontinence Quality of Life Scale (FIQL).²⁻⁴ The primary treatment option for FI is conservative treatment, including psychotherapy, clinical therapy, perineal musculature strengthening, biofeedback.² Instruction for ideal defecation habits are always necessary in order to preserve perineal musculature.² In less advanced FI, clinical treatment has shown excellent results and it is based on high fiber diet and bulking agents, aiming a more consistent stool and, depending on the patient, antidiarrheal medication can be used.^{2,5} The classic surgery indication is for complete sphincter disruption, successfully treated with sphincteroplasty.² The most

used surgical technique available is the anterior overlapping sphincteroplasty, that shows good short-term functional results, but, over time, declines, starting specially after two years, which can be objectively assessed by FI questionnaires.⁶ However, in cases with perineal complex anatomical deformity, we recommend the overlapping sphincteroplasty with Deoti's surgical flap. The aim of this article is to present six cases treated by sphincteroplasty with Deoti's Flap.⁵

Methods

From September 2012 to October 2017, 6 Patients where submitted to sphincteroplasty using Deoti's Flap. Four of them at Alpha Institute of Gastroenterology, Hospital of Clinics Federal University of Minas Gerais and two, at Cristiano Machado Hospital, Hospital Foundation of Minas Gerais State. All patients were female with ages from 31 to 60 years, at time of surgery. The main indication for Deoti's flap use was severe perineal anatomical deformity caused by obstetric trauma (2), after perianal fistula surgery (3) or hemorrhoidectomy (1). Patient's characteristics are in Table 1. Functional results and QoL were assessed approximately every 6 months after surgery by Wexner Score and FIQL Scale, validated to Brazilian portuguese.^{4,7}

Our patients had different follow-up time and, our sample group does not meet the sample size required for parametric tests and the sample is not normally distributed. Therefore, we performed a nonparametric test, the Mann-Whitney test, for

Table 1 – Patient characteristics.

Case	Sex	Age (years)	Etiology	Postoperative course	Follow-up (months)
1	F	31	Fistulectomy	Uneventful	61
2	F	43	Obstetric trauma	Uneventful	58
3	F	56	Fistulectomy	Hematoma	53
4	F	45	Obstetric trauma	Uneventful	19
5	F	36	Fistulectomy	Uneventful	11
6	F	60	Hemorrhoidectomy	Partial flap dehiscence	8

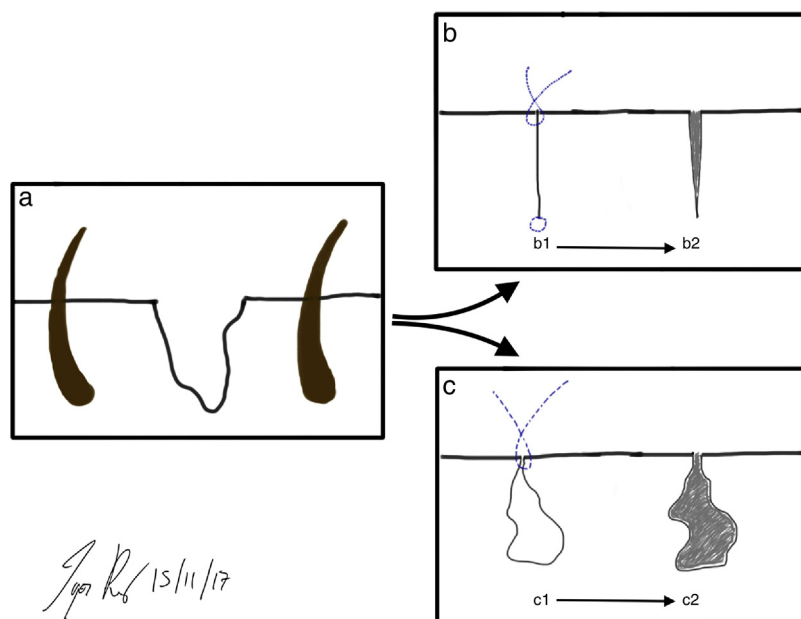


Fig. 1 – The principle for an optimal suture is represented by the filling of the empty space (a). Healthy tissue approximation (b1), leading to linear scar tissue (b2). Skin approximation without healthy tissue filling of the empty space (c1), leading to sectorial fibrosis (c2) (adapted from Rodrigues, Buzatti et al.⁷).

comparative statistical analysis to evaluate the significance between the median results of questionnaires.

The surgical technique used, described in details at Rodrigues, Buzatti et al.,⁵ is based on the principle for an optimal suture (Fig. 1) and the benefits of fat grafting.⁸ The overlapping sphincteroplasty with Deoti's flap was performed, highlighting four important aspects: (1) Dissect carefully, avoiding dissection of more than 180° of the anal circumference, to find the IAS, the EAS and the fibrotic tissue without injuring terminal branches of the pudendal nerve; (2) Make an overlapping that includes the subcutaneous portion and the superficial portion of the EAS; (3) Remove all unhealthy skin, because it will not fill the empty space and will not cover the muscles that were sutured, causing formation of sectorial fibrosis (Fig. 1); (4) Deoti's flap, which includes a rich adipose tissue, was planned, rotated and advanced, suturing its skin to the wound's border, making the adipose tissue fill the empty space and cover the overlap and sutured muscles (Fig. 2). Drainage should be performed according to surgeon's criteria.

Results

All operations were carried out without intraoperative complications or failure to perform Deoti's flap. Four of the patients

(67%) had an uneventful postoperative course, while 2 (33%) of them had moderate complications, hematoma and partial flap dehiscence, which were successfully treated without flap loss (Table 1).

The results obtained by application of Jorge & Wexner Fecal Incontinence Score are presented in Table 2 and, the medians of the questionnaire scores were 18.50 and 3.50, on the preoperative and post-operative evaluation, respectively. This result was statistically significant with a *p*-value of 0.0173.

The FIQL Scale results are in Table 2, along with percentage of improvement, medians and *p*-values. The lowest percentage improvement (0%) was observed in Scale 4 of Patient 5, because the patient already had maximum score, before surgery, in this scale. The greatest improvement (200%) is also noticed in Scale 4, but from Patient 3. The *p*-value was statistically significant for Scales 1 (*p* = 0.0260), Scales 2 (*p* = 0.0411) and Scales 3 (*p* = 0.0368), while the *p*-value for Scale 4 (*p* = 0.0952).

Discussion

The present series shows clinical evidence that the Deoti's surgical flap with sphincteroplasty is an effective technique for perineum anatomical reconstruction (Fig. 3) and, the

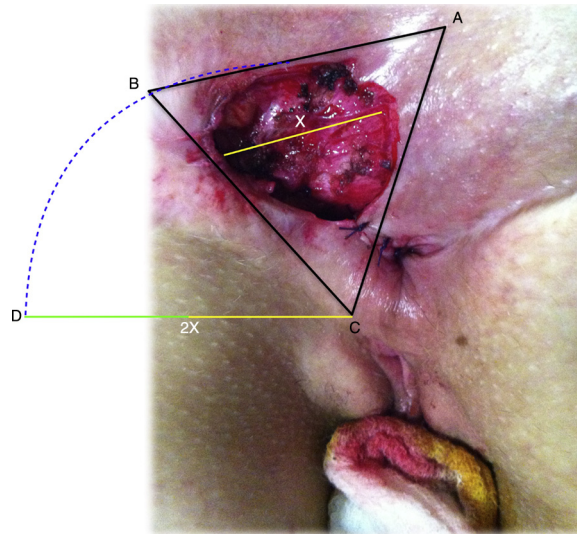


Fig. 2 – Planning of Deoti’s flap, in Patient 1, by imagining a model of simulated equilateral triangle of vertices A, B and C. The diameter (X) of the defect is measured and the double of X is marked from the apex (C), extending to the side chosen to make the flap (D). The incision is performed following the blue dotted line, from the base tangent to the wound until D.

Table 2 – Comparison between pre-operative and post-operative results in Wexner Score and FIQL.

Case	Wexner			Scale	FIQL			
	Pre-op	Post-op	p^a (95% CI)		Pre-op	Post-op	Improvement	p^a (95% CI)
1	20	10		S1	1.80	2.40	33%	
				S2	1.11	2.00	80%	
				S3	1.71	3.28	91%	
				S4	1.00	2.33	133%	
2	17	6		S1	1.50	3.20	113%	
				S2	1.22	2.33	90%	
				S3	1.85	2.85	54%	
				S4	1.66	2.66	60%	
3	20	0		S1	1.70	4.00	135%	
				S2	1.80	3.33	85%	
				S3	3.00	3.66	22%	
				S4	1.33	4.00	200%	
4	20	12		S1	1.00	2.90	190%	
				S2	1.33	2.88	116%	
				S3	2.00	3.14	57%	
				S4	1.00	2.66	166%	
5	12	0		S1	2.55	3.50	37%	
				S2	3.66	3.77	3%	
				S3	2.71	3.28	21%	
				S4	4.00	4.00	0%	
6	5	1		S1	3.28	3.57	8%	
				S2	1.75	2.25	28%	
				S3	3.50	4.00	14%	
				S4	3.50	4.00	14%	
Median	18.5	3.5	0.0173	S1	1.75	3.35		0.0260
				S2	1.54	2.60		0.0411
				S3	2.35	3.28		0.0368
				S4	1.49	3.33		0.0952

S1, Scale 1; S2, Scale 2; S3, Scale 3; S4, Scale 4.

^a p-Value.

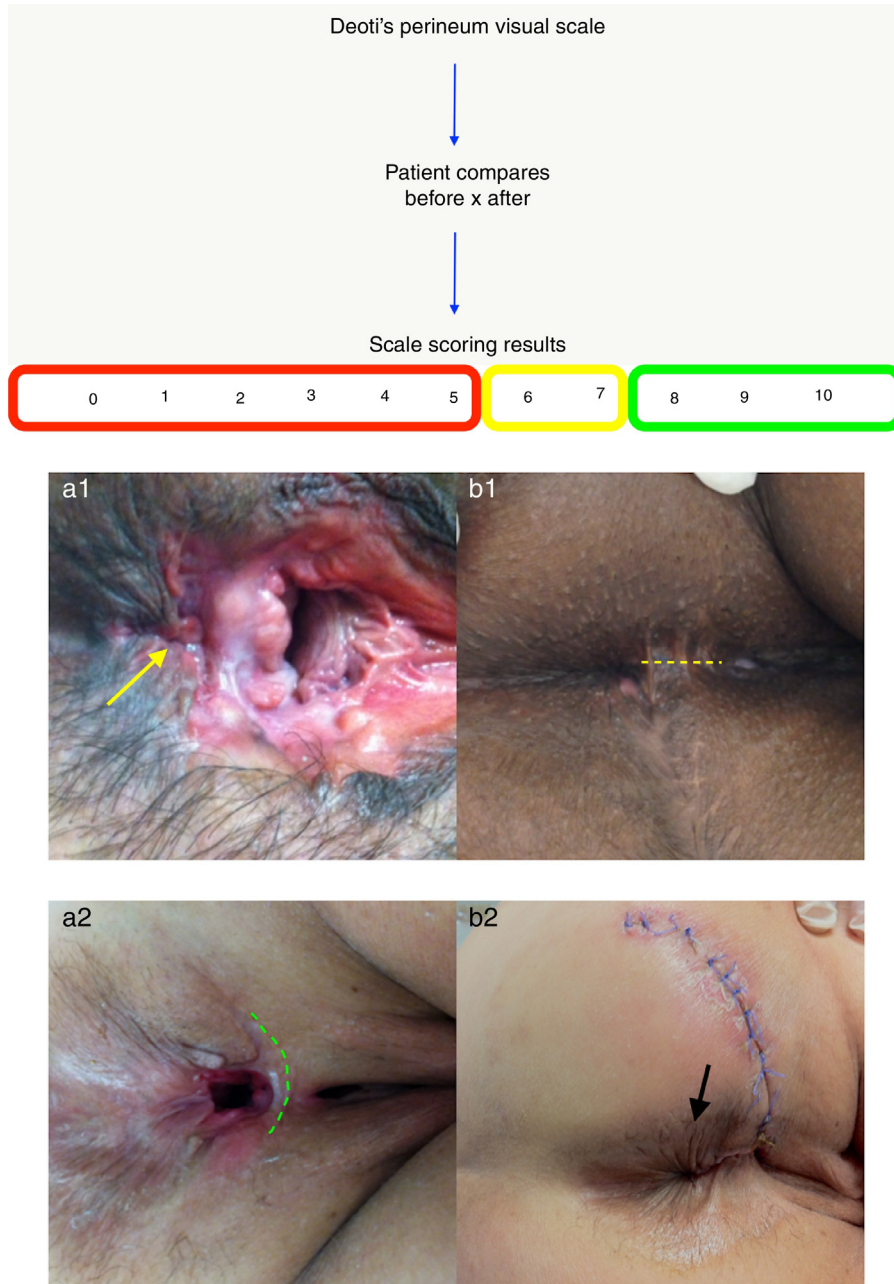


Fig. 3 – Deoti's Perineum Visual Scale ranging from 0 to 10. The range circled in red (0 to 5) is “poor result”; the range in yellow (6 to 7) is “fair to good result”; and the range in green (8 to 10) is “excellent result”; some examples are the esthetic and anatomical result in the perineum before (a1 and a2) and after (b1 and b2) surgery, in Patient 2 and 3, respectively. Observe complete absence of rectovaginal septum in Patient 2, before surgery (a1); after reconstruction, notice the excellent rectovaginal septum in yellow dotted line (b1). In Patient 3 there is scar tissue (green dotted line) without wrinkled skin before surgery; observe the wrinkled skin formed after Deoti's flap (black arrow).

results also suggest that performing the flap may sustain the improvement in fecal continence longer than sphincteroplasty alone. We attribute this secondary endpoint to the association between muscle repair and richly vascularized healthy adipose tissue of the Deoti's flap filling the deformity's empty space. This contact prevents extensive fibrosis and adhesion of the skin fibrosis to the muscle tissue, due

to many stem and progenitor cells present in subcutaneous fat.⁵

Our study aims to provide a useful report for the future treatment of severe perineal deformity, which is fortunately rare, giving us a small number of cases. These cases showed that the Deoti's flap had important and positive impacts on the patient's scores. The anorectal function improved in

all patients according to the Wexner questionnaire in up to 61 months follow-up with pre-operative and post-operative medians of 18.5 and 3.5, respectively (Table 2), which are statistically significant ($p=0.0173$). This outcome was also observed in QoL in all scales of FIQL (Table 2). The comparative statistical analysis suggests that most of our results are statistically significant and Scale 4 was the only result not significant ($p=0.0952$). However, this happened, because Patients 5 and 6 already had great scores in Scale 4 before surgery, 4.0 and 3.50, respectively. Scale 4 goes up to 4.0, therefore the improvement for these two patients was either none or small. Nevertheless, the statistical analysis does not allow conclusions due to our sample's characteristics. These results suggest better outcomes than sphincteroplasty alone, which presents a decrease in functional result after 24 months.⁹

A systematic review, from Glasgow and Lowry, showed that anal sphincter repair for FI presents functional worsening after about 24 months follow-up, despite the patients remaining satisfied.⁹ In our case series, sphincteroplasty is associated with Deoti's flap, and we have three patients over 50 months follow-up maintaining consistent sphincter function, while the other three patients are still under 24 months. Patient 3 is our best result with current Wexner score of 0 at 53 months follow-up. Patient 1 previously had a Wexner Score of 7, however she presented a worsening in continence due to a complicated appendicitis with sepsis by fistula, followed by right colectomy, in 2014. After surgery, the patient presented an increase in the number of bowel movements per day (Bristol 5 and 6).¹⁰ Patient 4 does not follow our clinical orientations, worsening her stools consistency, and even with greater sphincter contraction during physical examination, her Wexner Score is 12 and the worse among the cases.

It is also important to highlight that functional results and QoL improvement do not evaluate the perineal anatomical reconstruction, making it difficult to objectively assess the anatomical reconstruction of our technique, which is clearly visible in Fig. 3. Therefore, we propose a visual scale analyzing photos before and after surgery to assess the perineum esthetical and anatomical results since functional and QoL questionnaires are not appropriate to assess the outcome of this technique's main objective – the anatomical reconstruction of the perineum. The proposed scale (Fig. 3) is simple and objective. Scores from 0 to 10, in which 10 is the best outcome, are given by the patient to the surgery result. Although continence is rarely perfect after the operation using Deoti's flap for perineal reconstruction, we can offer a good esthetic result for our patients that give a positive impact on the self-esteem and quality of their lives, which explains the role of the visual scale to assess this result.

Conclusion

Deoti's surgical flap with sphincteroplasty successfully reconstructs complex anatomical deformity of the perineum and may be capable of prolonging functional results of the sphincteroplasty. Prospective studies with a larger number of patients are required to confirm our findings.

Compliance with ethical standards

Ethical Approval: All procedures performed in studies involving human participants were in accordance with the ethical standards of the institutional and/or national research committee and with the 1964 Helsinki declaration and its later amendments or comparable ethical standards.

Informed consent: Informed consent was obtained from all individual participants included in the study.

Data availability

All data generated or analyzed during this study are included in this published article.

Conflicts of interest

The authors declare no conflicts of interest.

Acknowledgments

We would like to thank the patients who entrusted their treatment to our team.

REFERENCES

1. Fonseca AM, Meinberg MF, Lucas DV, Monteiro MV, Figueiredo EM, Fonseca L, et al. Cultural adaptation and validation of the Wexner scale in patients with anal incontinence in a Brazilian population. *Int Urogynecol J*. 2016;27:959–63.
2. Jorge JMN, Wexner SD. Etiology and management of fecal incontinence. *Dis Colon Rectum*. 1993;36:77–97.
3. Rockwood TH, Church JM, Fleshman JW, Kane RL, Mavrantonis C, Thorson AG, et al. Fecal incontinence quality of life scale: quality of life instrument for patients with fecal incontinence. *Dis Colon Rectum*. 2000;43:9–16.
4. Rodrigues BDS, Reis IGN, Coelho FMD, Buzatti KCLR. Fecal incontinence and quality of life assessment through questionnaires. *J Coloproctol*. 2017;37:341–8.
5. Rodrigues BDS, Buzatti KCLR, Reis IGN, et al. Deoti surgical flap and sphincteroplasty for treatment of severe perineal deformity. *J Coloproctol*. 2017;37:95–9.
6. Van Koughnett JA, Wexner SD. Current management of fecal incontinence: choosing amongst treatment options to optimize outcomes. *World J Gastroenterol*. 2013;19:9216–30.
7. Yusuf SA, Jorge JM, Habr-Gama A, Kiss DR, Gama Rodrigues J. Avaliação da Qualidade de Vida na Incontinência Anal: validação do questionário FIQL (Fecal Incontinence Quality of Life). *Arq Gastroenterol*. 2004;41:202–8.
8. Kato H, Minoda K, Eto H, Doi K, Kuno S, Kinoshita K, et al. Degeneration, regeneration, and cicatrization after fat grafting: dynamic total tissue remodeling during the first 3 months. *Plast Reconstr Surg*. 2014;133:303e–13e.
9. Glasgow SC, Lowry AC. Long-term outcomes of anal sphincter repair for fecal incontinence: a systematic review. *Dis Colon Rectum*. 2012;55:482–90.
10. Lewis SJ, Heaton KW. Stool form scale as a useful guide to intestinal transit time. *Scand J Gastroenterol*. 1997;32:920–4.