



## Original Article

# Synergistic effects of hydro extract of *jujube* fruit in combination with Mesalazine (orally) and Asacol (intra-colonic) administration in ameliorating animal model of ulcerative colitis



Shahsanam Gheibi<sup>a</sup>, Seyyed Rahim Hashemi<sup>b</sup>, Mojtaba Karimipour<sup>c</sup>,  
Bahman Mansouri Motlagh<sup>a</sup>, Hadi Esmaeili Gouvarchin Ghaleh<sup>a,\*</sup>

<sup>a</sup> Urmia University of Medical Sciences, Maternal and Childhood Obesity Research Center, Urmia, Iran

<sup>b</sup> Urmia University of Medical Sciences, Shahid Motahari Hospital, Urmia, Iran

<sup>c</sup> Urmia University of Medical Sciences, Faculty of Medicine, West Azerbaijan, Iran

### ARTICLE INFO

#### Article history:

Received 20 March 2018

Accepted 26 May 2018

Available online 6 July 2018

#### Keywords:

Colitis

Acetic acid

hydro extract *jujube* fruit

### ABSTRACT

This study was done to investigate the synergistic impacts hydro extract of *jujube* fruit in combination with Mesalazine (orally) and Asacol (intra-colonic) administration in ameliorating animal model of ulcerative colitis (UC). After the induction of UC and with the development of signs, the treatment groups daily received the hydro extract of *jujube* fruit (200 mg/kg, orally, enema), Mesalazine (30 mg/kg, orally) and Asacol (10 mg/kg, enema). After 10 days, rats were euthanized and were studied. Findings indicated a significant increase in Myeloperoxidase ( $161.66 \pm 10.40$ ), Nitric oxide ( $216.01 \pm 17.55$ ), IL-6 ( $138.54 \pm 7.02$ ), and TNF- $\alpha$  ( $123.87 \pm 9.80$ ) colon tissue levels and pathological damage of positive control group compared with the negative control group. Hydro extract of *jujube* fruit in combination with Mesalazine (orally) and Asacol (intra-colonic) group represented a higher capability in significantly decreasing Myeloperoxidase ( $73.33 \pm 9.07$ ), Nitric oxide ( $81.66 \pm 10.50$ ), IL-6 ( $51.69 \pm 5.19$ ), TNF- $\alpha$  ( $30.59 \pm 5.50$ ) levels and pathological damage in compared with the other treatment groups. Considering accessibility and affordability of *jujube* fruit and the side effects of routine drugs, taking a combination of *jujube* fruit with low doses of routine pharmaceutical drugs can improve and cure ulcerative colitis disease.

Published by Elsevier Editora Ltda. on behalf of Sociedade Brasileira de Coloproctologia.

This is an open access article under the CC BY-NC-ND license (<http://creativecommons.org/licenses/by-nc-nd/4.0/>).

\* Corresponding author.

E-mail: [h.smaili69@yahoo.com](mailto:h.smaili69@yahoo.com) (H.E. Ghaleh).

<https://doi.org/10.1016/j.jcol.2018.05.008>

2237-9363/Published by Elsevier Editora Ltda. on behalf of Sociedade Brasileira de Coloproctologia. This is an open access article under the CC BY-NC-ND license (<http://creativecommons.org/licenses/by-nc-nd/4.0/>).

## Efeitos sinérgicos do extrato aquoso da fruta da jujuba em combinação com administração de Mesalazina (via oral) e Asacol (intracolônico) na melhora de colite ulcerativa em modelo animal

### R E S U M O

#### Palavras-chave:

Colite

Ácido acético

Extrato aquoso da fruta da jujuba

Este estudo foi realizado para investigar os impactos sinérgicos do extrato aquoso do fruto da jujuba em combinação com a administração de Mesalazina (por via oral) e Asacol (intracolônico) na melhora do modelo animal de colite ulcerativa. Após a indução da colite ulcerativa e com o desenvolvimento de sinais, os grupos de tratamento receberam diariamente o extrato aquoso do fruto da jujuba (200 mg/kg, via oral, enema), Mesalazina (30 mg/kg, via oral) e Asacol (10 mg/kg, enema). Após 10 dias, os ratos foram eutanasiados e estudados. Os achados indicaram um aumento significativo dos níveis de mieloperoxidase ( $161,66 \pm 10,40$ ), óxido nítrico ( $216,01 \pm 17,55$ ), IL-6 ( $138,54 \pm 7,02$ ) e TNF- $\alpha$  ( $123,87 \pm 9,80$ ) no tecido do cólon e dano patológico do grupo controle positivo comparado com o grupo controle negativo. O extrato aquoso da fruta de jujuba em combinação com Mesalazina (oral) e Asacol (intracolônico) representou maior capacidade de redução significativa dos níveis de mieloperoxidase ( $73,33 \pm 9,07$ ), óxido nítrico ( $81,66 \pm 10,50$ ), IL-6 ( $51,69 \pm 5,19$ ), TNF- $\alpha$  ( $30,59 \pm 5,50$ ) e dano patológico em comparação com os outros grupos de tratamento. Considerando a acessibilidade e disponibilidade do fruto da jujuba e dos efeitos colaterais dos medicamentos de rotina, tomar uma combinação de jujuba com baixas doses de medicamentos farmacêuticos de rotina pode melhorar e curar a colite ulcerativa.

Publicado por Elsevier Editora Ltda. em nome de Sociedade Brasileira de Coloproctologia. Este é um artigo Open Access sob uma licença CC BY-NC-ND (<http://creativecommons.org/licenses/by-nc-nd/4.0/>).

## Introduction

Inflammatory bowel disease is a common inflammatory condition in industrialized and developing countries. Types of IBD include Crohn's disease and ulcerative colitis both of which can be detrimental to patients.<sup>1</sup> Generally, all forms of inflammatory disease impact patients' quality of life for a number of reasons: an inflammatory disease can cause anal fistulas, stricture, perineal fissure, bloody stool and diarrhea, chronic constipation and abdominal pain.<sup>2</sup> Fatal IBD complications include acute blood loss anemia caused by intestinal ulcers, intestinal obstruction; malabsorption and malnutrition caused by severe mucosal damage.<sup>3</sup> Moreover, studies suggest IBD patients have a high risk of developing colorectal (CRC) and lymphoma (LC) cancers leading to a higher mortality rate of IBD.<sup>4</sup> Not only are current treatment procedures unable to cure IBD, but also their application is limited based on a number of factors including ineffectiveness, high toxicity and potential side effects<sup>5</sup>; hence, scientists' unending attempt to find stable treatment methods with less severe side effects. Some of the most common treatment practices include prescribing: corticosteroids, anti-inflammatory drugs like Mesalazine, immunosuppressive medication such as azathioprine, cyclosporine, anti-inflammation monoclonal antibodies, anti-diarrhea medications, antibiotics, painkillers and iron supplements.<sup>6</sup> In IBD, arachidonic acid metabolites are identifiable in cyclooxygenase and lipoxygenase pathways; Mesalazine seems to control inflammation through inhibition of cyclooxygenase and decreasing prostaglandin production within the colon. Studies today seek natural compounds with less severe side effects for the treatment

of inflammatory diseases, particularly, inflammatory bowel diseases.<sup>7</sup> In East Asia, *jujube* (*Ziziphus Vulgaris Lam*) has long been known as an herbal medicine for a variety of diseases: liver disorders, anemia, shortness of breath, nausea, cardiovascular disease, hypertension and gastrointestinal disorders, high cholesterol, renal malfunction, and diabetes.<sup>8</sup> Phytochemical analysis of *jujube* derived the following antioxidants and bioactive compounds, which are associated with its therapeutic properties: flavonoids, triterpenic acids, cerebrosides, phenolic acids, alpha-tocopherol, beta-carotene, saponins, tannins, sterols, cyclopeptide alkaloids, and polysaccharides.<sup>9</sup> Previous research examined the impact of *jujube* varieties on diabetes. Rafeian-kopaei et al. (2014) also verified the hyperlipidemic hypoglycemic impacts of *jujube* powder.<sup>10</sup> Asgari et al. (2016) examined the increasing impact of *jujube* powder on antioxidant capacity and prevention of diabetes-induced inflammation.<sup>11</sup> Koohi-Hosseiniabadi et al. (2015) examined the positive therapeutic properties of *jujube* powder on oral mucositis.<sup>12</sup> Considering the above-mentioned case studies, this research examines the therapeutic properties of the synergistic application of hydro extract *jujube* fruit (natural compounds) and Mesalazine in an animal model of ulcerative colitis with the purpose of reducing the doses of chemical medication to slightly reduce the probable side effects.

## Materials and methods

### Jujube fruit extraction process

*Jujube* fruits were purchased at a shop in Mashhad. A herbarium collections manager at the University of Urmia identified

**Table 1 – The characteristics of the studied groups.**

Characteristics	Group
1 mL PBS (orally-enema)	Negative control
1 mL PBS (orally-enema)	Positive control
Mesalazine (orally 30 mg/kg)	Mesalazine
Asacol (enema 10 mg/kg)	Asacol
200 mg/kg (orally)	Extract orally
200 mg/kg (Enema)	Extract enema
200 mg/kg extract + 30 mg/kg asacol	Extract + asacol

and specified the fruits. After rinsing/drying, fruits were ground to a powder then vacuum dried using an electric mill. The resulting powder was then soaked in distilled water for 48 h before passing the filter. The process consisted of two phases. The extract was in an incubator at 50 °C temperature, going through distillation again. The resulting hydro extract was refrigerated at –20° prior to application.<sup>13</sup>

#### Ulcerative colitis induction procedure

Intrarectal administration of acetic acid was used to induce ulcerative colitis. Rats were deprived of food for 48 h, only having access to water. To induce colitis, rats were anesthetized with ether and a catheter was inserted into each rat's rectum. 1 mL of acetic acid was injected into rats' rectums and they were kept slantwise for 30 s to keep the acid inside their rectums.<sup>14</sup>

#### Study population and experimental groups

The study population consisted of 70 Wistar rats, weighing 160–200 g each, purchased at the Pets House at the faculty of medicine. To adapt rats to the study environment, they were kept in the standard experiment condition for two weeks; 12-h day–night cycle, 22 °C–25 °C temperature, and easy access to food and water. Then, rats were randomly divided into 7 groups of 10 (Table 1).

#### Measurement colon tissue level of Myeloperoxidase (MPO) activity

Two mL of phosphate buffer contains 0.5% hexadecyl trimethyl ammonium bromide (HTAB) was added to 100 mg of colon tissue and homogenized on ice for six times of 45 s. Then, 10 s of sonication and freeze by liquid nitrogen were applied for three times. Centrifugation at 3000 rpm and 4 °C for 30 min was performed and the supernatant was harvested. 2.9 mL of phosphate buffer contain o-Dianisidine and 0.005% hydrogen peroxide was added to 0.1 mL of supernatant and after 5 min, 0.1 mL of 1.2 M HCl was added to the tube to orange color was appeared. The absorbance of the samples was measured at 460 nm by UV–visible spectrophotometer and the activity of MPO was calculated using a standard curve.<sup>15</sup>

#### Measurement colon tissue level of Nitric Oxide (NO)

This method determined Nitric Oxide levels resulted by colon tissue homogenization in supernatant cells through Griess reaction. Homogenized colon tissue samples were centrifuged

to omit the remaining microscopic cells. Samples were distilled with the kit buffer with a ratio of 2:1. Next, 100 mL of each sample was poured into 96-well plates in three replications. The kit also contained standard and blank samples that were poured into 96-well plates in three replications. An ELISA plate reader measured the samples at a wavelength of 570 nm.<sup>16</sup>

#### TNF- $\alpha$ and IL-6 colon tissue level measurement

Using ELISA test, this study bought kits made by Bender Medsystems from Australia and used them -fully obeying the instructions- to measure the serum levels of supernatant cells' TNF-6 and IL-6 resulted by the homogenization of colon tissue in study rats.<sup>15</sup>

#### Histopathological investigation of colon tissue

To examine the microscopic damage in colon tissue samples, 0.5 cm specimens were gathered from the colon tissue and then kept in 10% formalin. Next, samples were sent for H&E staining. Results were categorized according to the given score, from 0 to 3, based on a number of factors: intestinal crypts changes, inflammatory cells infiltration levels, bowel wall thickening, and the decrease of goblet cells. The resulting numbers of parameters were added up to determine the severity of damage.<sup>17</sup>

## Results

#### Myeloperoxidase activity measurement

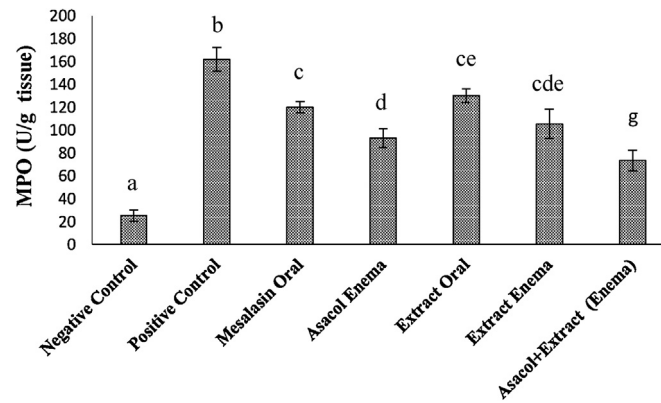
The results indicated a significant increase ( $161.66 \pm 10/40$ ) of produced MPO levels in the positive control group compared with the negative control group ( $p < 0.05$ ). Groups receiving Asacol (enema), Mesalazine (enema) and hydro extract (oral, enema) orderly represented a more significant decrease, compared with the positive control group. Statistically, MPO decrease in the group receiving the synergistic treatment proved more significant ( $73.33 \pm 9/07$ ), compared with other treatment groups (Fig. 1).

#### Nitric Oxide measurement

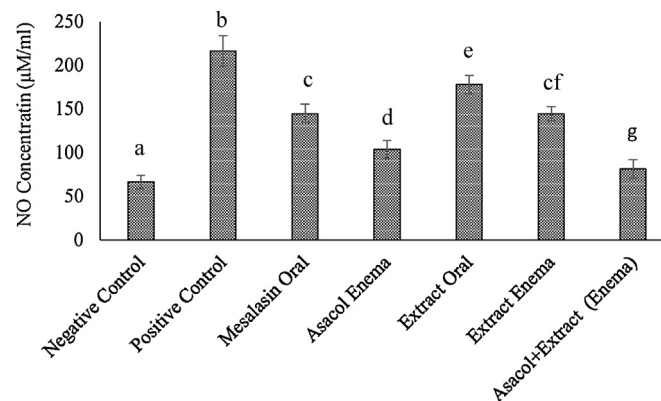
Fig. 2 indicated a significant increase ( $216.33 \pm 17.55$ ) of produced nitric oxide levels in the positive control group compared with the negative control group ( $p < 0.05$ ). Groups receiving Asacol (enema), Mesalazine (enema) and hydro extract (oral, enema) orderly represented a more significant decrease, compared with the positive control group. Statistically, the nitric acid decrease in groups receiving the synergistic treatment proved more significant ( $81.00 \pm 10.53$ ), compared with other treatment groups ( $p < 0.05$ ).

#### TNF- $\alpha$ and IL-6 colon tissue Level measurement

Fig. 3A and B examines the activity of IL-6 and TNF- $\alpha$ , respectively. The production of IL-6 and TNF- $\alpha$  in colon tissue of the positive control group rats significantly increased



**Fig. 1 – Comparison of mean and SD MPO level in colon tissues of different experimental groups. Significant statistical differences between groups in each index are indicated by the different superscript letter ( $p < 0.05$ ).**



**Fig. 2 – Comparison of mean and SD NO level in colon tissues of different experimental groups. Significant statistical differences between groups in each index are indicated by the different superscript letter ( $p < 0.05$ ).**

( $138.54 \pm 7.02$ ), ( $123.87 \pm 10.80$ ) respectively- compared with the rats of the negative control group. Groups receiving Asacol (enema), Mesalazine (enema) and hydro extract (oral, enema) orderly represented a more significant decrease in the levels of the two cytokines, compared with the positive control group. Statistically, IL-6 and TNF- $\alpha$  production decrease in groups receiving the synergistic treatment proved more significant ( $56.69 \pm 5/19$ ), ( $30.59 \pm 5.50$ ) respectively, compared with other treatment groups ( $p < 0.05$ ).

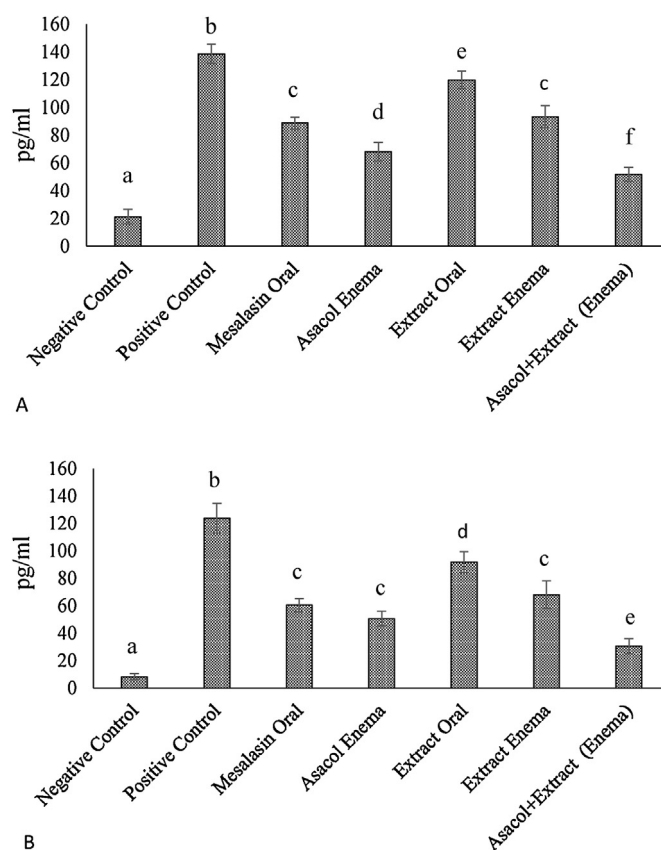
### Histology of damage

The microscopic study of colon tissue samples indicated that the positive control group had the highest mucosal damage to a degree that necrosis involved the entire epithelial layer (<90%), causing the destruction of the epithelium. Intestinal crypts changes, inflammatory cells infiltration levels, bowel wall thickening, and the decrease of goblet cells was higher in the positive control group compared with other groups; hence, receiving 3, as the highest potential score in the provided scoring system. The above-mentioned changes were insignificant in the negative control group; hence, receiving 0, the lowest score possible. Groups receiving jujube hydro extract (oral, enema), Mesalazine (oral), and Asacol (enema)

represented that epithelium was not destroyed completely; hence, receiving 2 for the level of epithelium damage. Given the observed tissue changes, the score is given to the group receiving jujube flesh and seed hydro extract (oral, enema) along with Asacol was 1 (Fig. 5). Statistical analysis indicated that in comparison with other groups, the group receiving synergistic treatment of Asacol and hydro extract intracolonicly (enema) represented a higher decrease of acetic acid-induced ulcers ( $p < 0.05$ ). Other treatment groups also represented significantly lower colon damage, compared with the positive control group ( $p < 0.05$ ). However, a statistically significant difference was not reported in the groups receiving Mesalazine (oral), Asacol (enema), hydro extract (oral, enema).

### Discussion

Types of IBD include ulcerative colitis and Crohn's disease, which are complicated, uncontrollable, and multifactorial; an occurrence of a chronic, relapsing, and deteriorating inflammation determines if IBD can involve the entire digestive system.<sup>18</sup> Inflammatory bowel disease represents a group of some of the most prevalent digestive system diseases with unknown etiologies. Due to the absence of a precise etiology, there is no absolute cure for these diseases; hence, many



**Fig. 3 – Changes of inflammatory cytokine in colon tissues of rats in different groups. (A) IL-6 level, (B) TNF- $\alpha$  level. Significant statistical differences between groups in each index are indicated by the different superscript letter ( $p < 0.05$ ).**

patients don't respond quite positively to current treatment procedures and the disease relapses periodically, which can lead to GI cancer.<sup>19</sup> Pathogenesis of IBD isn't fully demystified today, however, risk factors may include a variety of environmental, immunologic, genetic, microbial, and psychological factors combined with unnatural autoimmune response to some stimuli, involvement of cells and proteins, with immune dysfunction, oxidative stress, and the inflammatory mediators playing a major role in IBD development.<sup>20</sup> Infiltration of white globules and macrophages into intestinal mucosa is a salient sign of IBD. Activated neutrophils on mucosal surface produce free radicals, such as peroxide ion, radical hydroxyl, and hydrogen peroxide. These elements cause lipid peroxidation, increased vascular permeability, higher levels of neutrophils on intestinal mucosa, and chronic inflammation.<sup>21</sup>

Currently, conventional cures include administration of anti-inflammatory medication such as corticosteroids, amino salicylates, exclusive enteral nutrition (EEN), and antibodies functioning against tumoral necrosis. Having numerous side effects, these medications are parts of supportive and symptomatic treatment and most patients will need a surgical approach in the end.<sup>22</sup> On the other hand, most advances in etiology and treatment of many diseases including IBD are the results of empirical studies on animal models. Therefore, there is wide research exploring the etiology in addition to finding natural, safe treatment methods, particularly, in traditional medicine, such as antioxidant compounds found in fruits to control disease.<sup>23</sup>

Since ancient history, herbs containing antioxidants have been used to fight a wide number of diseases. Jujube, for instance, has anti-inflammatory, anticarcinogenic, antioxidant immunomodulatory properties and protects the liver and the digestive system. Phytochemical analysis of jujube derived the following antioxidants and bioactive compounds, which are associated with its therapeutic characteristics: flavonoids, saponins, tannins, sterols, cyclopeptide alkaloids.<sup>24</sup> This study examines the impact of jujube hydro extract on intestinal mucosal inflammation in rats.

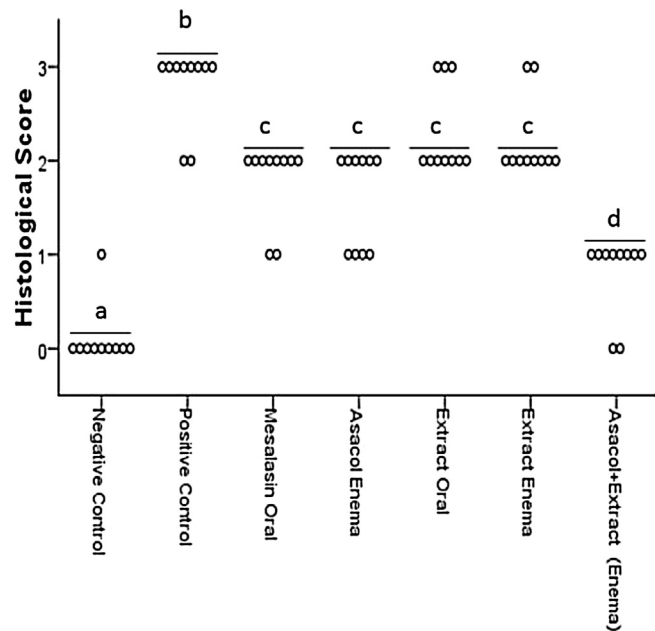
This study is unique in the sense that previous research hasn't compared the effectiveness of Mesalazine and Asacol with *jujube* in the treatment of induced colitis in rats by measuring IL-6 and TNF- $\alpha$ , and myeloperoxidase. Varshosaz et al. also examined the impact of ibuprofen on acetic acid-induced colitis in rats by measuring IL-6 and TNF- $\alpha$  and myeloperoxidase.<sup>25</sup> Also, Zhao et al. used the same method to examine the impact of magnolia on Dextran sulfate sodium-induced colitis.<sup>26</sup> However, Karawya et al. (Karawya et al., 2016) and Tanideh et al.,<sup>15</sup> in their separate studies in 2016, examined the impact of jujube on acetic acid-induced colitis in rats. Their studies are different from ours in that they used different doses of jujube extract and medications, measuring other cytokines. In other words, in their work, they either examined the impact of jujube on other diseases, the impact of other plants on induced colitis or measured other inflammatory indices<sup>15,27</sup>; hence, we compare our results with similar parts of other studies in the following section.

We used the same induction method as Hemayatkhah et al.,<sup>28</sup> Ahmadinejad et al.,<sup>29</sup> Koohpeyma et al.,<sup>30</sup> Karawya et al.,<sup>28</sup> and Tanideh et al.<sup>15</sup> employed in their studies, which were respectively conducted in 2010, 2014, and 2016, to examine the impacts of milk thistle, chamomile, *dracocephalum polychaetum*, and *jujube* on acetic acid-induced large intestine ulcers. Other available methods for induced colitis studies include Dextran sulfate sodium-induced colitis (DSS) and trinitrobenzene sulfonic acid (TNBS).<sup>30</sup> In this study, we used acetic acid because of easy availability.

Considering studies of Ebrahimi<sup>31</sup> and Taati et al.,<sup>32</sup> we used 200 mg/kg of *jujube* because higher doses had yielded more effective results.<sup>31</sup> Karawya et al. used a higher dose of *jujube* extract (5 times more than our study) (1 g/kg) to treat acetic acid-induced colitis in rats.<sup>27</sup> Both our results represent the similar, positive impact of *jujube* on amelioration of colitis. Morphological study of colon mucosa indicates that the group receiving *jujube* extract has lower mucosal damage.<sup>15</sup> Tanideh et al.<sup>15</sup> used a lower dose of Mesalazine (10 mg/kg, oral) and Asacol (enema) but high doses of hydroalcoholic *jujube* extract, 40% and 20% *jujube* gel (enema) and doses of 1500–300 mg/kg body weight (gavage). They put *jujube* above Mesalazine and the chosen medication for the treatment of UC,<sup>15</sup> while in our study, *jujube* represented almost the same results as Mesalazine; however, combined with Asacol, it proved more effective. This difference is based on the different doses of medication and *jujube* in the two studies, as we administered a conventional dose of Mesalazine (three times higher than Tanideh et al. administered dose), but their *jujube* dose was fifteen times higher than ours. Type of extraction process (hydro, hydroalcoholic) can also play a role in this difference though.

While animal models of study often focus on inflammatory mediators, biochemical factors, and histology<sup>33</sup> and Karawya et al. and Tanideh et al.<sup>15</sup> focus on morphological and biochemical changes, we also examined UC clinical symptoms including stool consistency and bloody stool to verify the induction of colitis in rats.

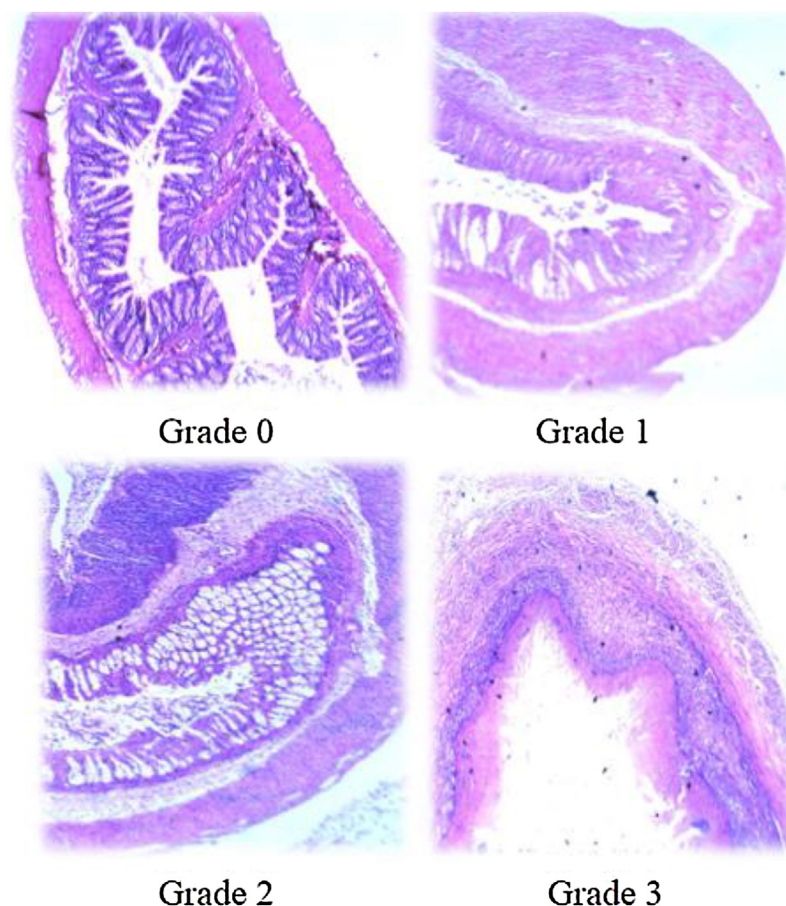
The primary results of this study indicated the occurrence of ulcerative colitis after the administration of acetic acid with rats representing some of the clinical symptoms including diarrhea and bleeding. Samples analysis also revealed that compared with the negative control group, levels of inflammation and tissue damage in the positive control group significantly increased to a degree that led to the total destruction of intestinal epithelium (Fig. 4). Conducted microscopic studies are in essence some of the most important achievements of this study. As depicted in the picture, the group receiving the synergistic treatment through enema (*jujube* hydro extract and Asacol) represented the best results, even in a short-term treatment (7-day-treatment), ulcers started to improve. The group receiving *jujube* hydro extract (oral, enema), Mesalazine (oral), and Asacol (enema) represented the same results, but tissue amelioration wasn't completed. Nevertheless, comparing these three treatment groups with the positive control group indicates a significant difference. Zhang et al.<sup>34</sup> and Vochyañoaét al.<sup>35</sup> also examined microscopic findings of the colon in their works to study the impacts of other plants on induced colitis in rats.



**Fig. 4 – Results of blind analysis of histopathological sections. The sections were scored, as described in material and methods and Fig. 4. Each point is the value of 10 mice in the same group. The line drawn across each group indicates the mean. Significant statistical differences between groups in each index are indicated by the different superscript letter ( $p < 0.05$ ).**

As mentioned in the results section, hydro extract of *jujube* had the same positive impacts on acetic acid-induced colitis as other treatment groups, however, synergistic treatment brings about more effective results; as depicted in Figs. 1–3, colon tissue levels of myeloperoxidase, nitric oxide, IL-6 and TNF- $\alpha$  inflammation indices – represent a significant decrease in groups that received the synergistic medications: *jujube* extract and Mesalazine. While sole treatment groups – receiving individual medication – represented a significant difference in comparison with the positive and negative control groups, there wasn't an observable difference among sole treatment groups. Combined treatment groups – receiving synergistic medication; hydro extract of *jujube* and Asacol – represented a significant difference compared with the negative (healthy) and positive (unhealthy) control groups.

Myeloperoxidase is a peroxidase enzyme playing a major role in the production of oxygen free radicals. Neutrophil granulocytes store high amounts of MPO that are released from granulocytes in response to the existence of inflammation antigens. The best method for examining myeloperoxidase activity in inflamed tissue is exploring the whole tissue.<sup>36</sup> This study is based on measuring MPO activity in inflamed colon tissue. Results indicated that colon tissue MPO activity increases significantly in acetic acid-induced UC. However, colon tissue MPO activity in treatment groups receiving the hydro extract of *jujube* fruit and Mesalazine separately and the treatment group receiving synergistic treatment hydro extract of *jujube* fruit and Mesalazine was lower than the positive control group (Figs. 3 and 4). Karawya et al.<sup>27</sup> and Tanideh



**Fig. 5 – Representative sections depict scoring system used for histopathological examinations (400×). (A) Grade 0: normal structure of the epithelial cells and basal area observed; (B) Grade 1: high recovery of microvilli in some epithelial cells and in the basal area the inflammatory cell infiltration was almost absent observed; (C) Grade 2: slight recovery of microvilli in some epithelial cells and in the basal area the inflammatory cell infiltration were observed; (D) Grade 3: loss of microvilli, swollen mitochondria with loss of cristae and nuclear alteration such as dilation of the nuclear envelope was also observed.**

et al.<sup>15</sup> have also reported a decrease of colon tissue MPO activity in acetic acid-induced UC after administration of the hydro extract of *jujube* fruit. Menghini et al.<sup>37</sup> in their study to compare the impact of hydroalcoholic extract of *chamomile* with sulphasalazine on rats' colon also measures MPO activity as a sort of inflammation marker, reporting that *chamomile* hydroalcoholic extract, like sulphasalazine, decreases levels of inflammatory biomarkers including the myeloperoxidase enzyme in rats colons.

Cytokines are important elements in the examination of IBD. IL-6 and TNF- $\alpha$  are more often measured because they play an important role in the expansion of inflammation in IBD<sup>28</sup>; however, Karawya et al. and Tanideh et al. did not monitor them in their studies examining other cytokines such as IL-1 $\beta$  and caspase, whereas many researchers consider these cytokines as inflammatory biomarkers in their studies examining the impacts of herbs on induced colitis in rats, gaining similar results to ours.<sup>18</sup> Regarding the results of this study, it seems that hydro extract of *jujube* fruit along with Asacol are effective in ameliorating clinical symptoms of ulcerative colitis in our empirical model. Since *jujube* fruit extraction is

an incredibly easy and rapid process, findings of this study open the door to new horizons regarding the application of traditional medicine in inflammatory disease treatment; decreasing doses of Mesalazine and Asacol, we can eliminate their side effects.

### Conflicts of interest

The authors declare no conflicts of interest.

### Acknowledgments

None.

### REFERENCES

1. Burisch J, Munkholm P. Inflammatory bowel disease epidemiology. *Curr Opin Gastroenterol.* 2013;29:357–62.
2. Molodecky NA, Soon IS, Rabi DM, Ghali WA, Ferris M, Chernoff G, et al. Increasing incidence and prevalence of the

- inflammatory bowel diseases with time, based on systematic review. *Gastroenterology*. 2012;142:46–54.
3. Büsch K, Ludvigsson JF, Ekström-Smedby K, Ekblom A, Askling J, Neovius M. Nationwide prevalence of inflammatory bowel disease in Sweden: a population-based register study. *Aliment Pharmacol Ther*. 2014;39:57–68.
  4. Manninen P, Karvonen AL, Huhtala H, Rasmussen M, Collin P. The epidemiology of inflammatory bowel diseases in Finland. *Scand J Gastroenterol*. 2010;45:1063–7.
  5. Jussila A, Virta LJ, Salomaa V, Mäki J, Mäki J, Jula A, Färkkilä MA. High and increasing prevalence of inflammatory bowel disease in Finland with a clear North-South difference. *J Crohn's Colitis*. 2013;7, e256–62.
  6. Van Assche G, Dignass A, Bokemeyer B, Danese S, Gionchetti P, Moser G, et al. European Crohn's and Colitis Organisation. Second European evidence-based consensus on the diagnosis and management of ulcerative colitis part 3: special situations. *J Crohn's Colitis*. 2013;7:1–33.
  7. Khan N, Abbas AM, Koleva YN, Bazzano LA. Long-term mesalamine maintenance in ulcerative colitis: which is more important? Adherence or daily dose. *Inflamm Bowel Dis*. 2013;19:1123.
  8. Solati S, Soleiman N. [Antidiabetic effects of ethanolic extract of *Ziziphus vulgaris* L. in streptozocin-induced diabetic adult male Wistar Rats]. *Physiol Pharmacol*. 2010;14:174–80.
  9. Mishra KK, Kashyap P, Sawarkar HA, Mule BP, Verma SK, Kumar S. Evaluation of antifungal activity of stones of *Ziziphus vulgaris* lam for ringworm infection. *Int J Herb Drug Res*. 2012;3:8–11.
  10. Rafeian-kopaei M, Asgari S, GolimalekAbadi N, Rouzbahani SH. Effects of jujube fruit powder to prevent increases in glucose and lipid profile disorders in Rats. *J Shahrekord Uni Med Sci*. 2014;15:141–9.
  11. Asgari S, Rafeyan M, Golimalekabadi N. The effects of Jujube Fruit (*Ziziphus vulgaris*) powder in antioxidant capacity elevation and prevent of inflammation detection due to diabetes in wistar rat. *Sci J Ilam Univ Med Sci*. 2016;24:55–64.
  12. Koohi-Hosseinabadi O, Andisheh-Tadbir A, Bahadori P, Sepehrimanesh M, Mardani M, Tanideh N. Comparison of the therapeutic effects of the dietary and topical forms of *Ziziphus jujuba* extract on oral mucositis induced by 5-fluorouracil: a golden hamster model. *J Clin Exp Dentist*. 2015;7, e304–9.
  13. Rao GHJ, Lakshmi P. Anti diarrhoeal activity of *Ziziphus vulgaris* lam extract in rats. *Int J Pharma Biosci*. 2012;3, 0975–6299.
  14. Safarpour AR, Kaviyani F, Sepehrimanesh M, Ahmadi N, Koohi Hosseinabadi O, Tanideh N, et al. Antioxidant and anti-inflammatory effects of gel and aqueous extract of *Melilotus officinalis* L. in induced ulcerative colitis: a *Rattus norvegicus* model. *Ann Colorect Res*. 2015;3, e29511.
  15. Tanideheh N, Jamshidzadehc A, Ghanbari Sagheslooc A, Rahmanifar F, Mokhtari M, Koohi-Hosseinabadif A. Effects of hydroalcoholic extract of *Ziziphus jujuba* on acetic acid induced ulcerative colitis in male rat (*Rattus norvegicus*). *J Coloproctol*. 2016;36:189–95.
  16. Bryan NS, Grisham MB. Methods to detect nitric oxide and its metabolites in biological samples. *Free Rad Biol Med*. 2007;43:645–57.
  17. Maines LW, Fitzpatrick LR, French KJ, Zhuang Y, Xia Z, Keller SN, et al. Suppression of ulcerative colitis in mice by orally available inhibitors of sphingosine kinase. *Dig Dis Sci*. 2008;53:997–1012.
  18. Zhao M, He J, Shen Y, Zhang C, Wang J, Chen Y. New frontiers in genetics, gut microbiota, and immunity: a rosetta stone for the pathogenesis of inflammatory bowel disease. *BioMed Res Int*. 2017;2017, 8201672.
  19. Yamauchi R, Kominato K, Mitsuyama K, Takedatsu H, Yoshioka S, Kuwaki K, et al. Stereomicroscopic features of colitis-associated tumors in mice: evaluation of pit pattern. *Oncol Lett*. 2017;14:3675–82.
  20. Szandruk M, Merwid-Lad A, Szelag A. The impact of mangiferin from *Belamcanda chinensis* on experimental colitis in rats. *Inflammopharmacology*. 2017.
  21. Tertychnyi AS, Akhrieva KM, Maev IV, Zayratyants OV, Selivanova LS. [Diagnostic problems of histological remission in patients with inflammatory bowel disease]. *Arkhiv patologii*. 2017;79:3–9.
  22. Habtemariam S, Belai A. Natural therapies of the inflammatory bowel disease: the case of rutin and its aglycone. *Quercetin*. *Mini Rev Med Chem*. 2017;18:234–43.
  23. Salaga M, Zatorski H, Sobczak M, Chen C, Fichna J. Chinese herbal medicines in the treatment of IBD and colorectal cancer: a review. *Curr Treatment Opt Oncol*. 2014;15:405–20.
  24. Gheibi S, Galeh HEG, Motlagh BM. Protective effects of *Ziziphus jujube* on clinical and paraclinical findings of glycogen storage disease Ib, a case report and literature review. *J Fasa Univ Med Sci*. 2017;7:291–6.
  25. Varshosaz J, Minaian M, Mollanoori I. Anti-inflammatory effects of ketotifen in acetic acid-induced ulcerative colitis in rats. *J Isfahan Med School*. 2013;31:138–49.
  26. Zhao L, Xiao HT, Mu HX, Huang T, Lin ZS, Zhong LLD, et al. Magnolol, a natural polyphenol, attenuates dextran sulfate sodium-induced colitis in mice. *Molecules*. 2017;22.
  27. Karawya F, Metwally ES. Effects of jujube fruit extract on acetic acid-induced colitis in adult male rats. *J Exp Clin Anat*. 2016;15:19–26.
  28. Hemayatkhah J. The Investigation of silymarin effect on colon ulcer induced acetic acid in mice. *Journal of Cell & Tissue*. 2011;1:21–8.
  29. Ahmadinejad S, Abbasnejad M, Derakhshanfar A, Esmaili Mehani S, Kohpeyma H. The effect of intracolonic *Matricaria recutita* L. aqueous extract on acetic acid-induced ulcerative colitis in adult male rats. *Govaresh*. 2014;19:32–9.
  30. Kohpyma H, Abbasnejad M, Ahmadinejad S, Mostafavi A, Derakhshanfar A. The effect of aqueous extract of *dracocephalum polychaetum burnm* on ulcerative colitis in adult male rats. *Pars J Med Sci*. 2016;14:7–14.
  31. Ebrahimi S, Sadeghi H, Pourmahmoudi A, Askariyan S, Askari S. Protective effect of *Ziziphus vulgaris* extract on liver toxicity in laboratory rats. *Armaghan Danesh*. 2010;4:172–80.
  32. Taati M, Alirezaei M, Meshkatsadat MH, Rasouljan B, Kheradmand A, Neamati S. Antioxidant effects of aqueous fruit extract of *Ziziphus jujuba* on ethanol-induced oxidative stress in the rat testes. *Iran J Vet Res*. 2011;12:39–45.
  33. Yang Y, Zhu X, Qin Y, Chen G, Zhou J, Li L, et al. The anti-inflammatory effect of guchangzhixie-pill by reducing colonic EC cell hyperplasia and serotonin availability in an ulcerative colitis rat model. *Evid-based Complem Altern Med*. 2017;2017, 8547257.
  34. Zhang F, Ma N, Gao YF, Sun LL, Zhang JG. Therapeutic effects of 6-gingerol, 8-gingerol, and 10-gingerol on dextran sulfate sodium-induced acute ulcerative colitis in rats. *Phytotherapy Res*. 2017;31:1427–32.
  35. VochoyáňováŽ, PokornaM, Rotrekl D, Smekal V, Fictum P, SuchyP, et al. Prenylated flavonoid morning protects against TNBS-induced colitis in rats. *PLoS ONE*. 2017;12:e0182464.
  36. Pulli B, Ali M, Forghani R, Schob S, Hsieh KL, Wojtkiewicz G, et al. Measuring myeloperoxidase activity in biological samples. *PLoS ONE*. 2013;8, e67976.
  37. Menghini L, Ferrante C, Leporini L, Recinella L, Chiavaroli A, Leone S, et al. A Hydroalcoholic chamomile extract modulates inflammatory and immune response in HT29 cells and isolated rat colon. *Phytother Res*. 2016;30:1513–8.