



## Original Article

## Clinic-pathological aspect of gastro-intestinal stromal tumors at tertiary care Hospital India

Sankar Subramanian \*, Amamndeeep Sing Sandhu, Jagan Balu, Suresh P

Surgical Gastroenterology, Sri Ramachandra Institute of Higher Education and Research, Sri Ramachandra University, Porur, Chennai, India

## ARTICLE INFO

## Article history:

Received 7 August 2019

Accepted 15 September 2019

Available online 27 October 2019

## Keywords:

Gastro-intestinal stromal tumors

Immunohistochemistry

CD-117, CD-34

## ABSTRACT

**Background:** This study defines the disease profile in south Indian population and determine the clinic-pathological aspects of Gastro-Intestinal Stromal Tumors.

**Method:** In this prospective study patients diagnosed of gastrointestinal stromal tumors were taken thorough clinical examination and a database of Anthropometric details and clinical details were analyzed. Pathological data included tumor size, presence or absence necrosis, mitotic counts, immunohistochemistry for CD-117, CD-34.

**Results:** There were 44 patients with confirmed diagnosis of gastro-intestinal stromal tumor. The highest incidence was found in the 6<sup>th</sup> decade. The most common symptoms were abdominal pain and gastrointestinal bleed. Stomach was most frequent site for gastro-intestinal stromal tumors. Immunohistochemistry for CD-117 was positive in 93.18% cases. Majority of tumors (79.5%) had pure spindle cell morphology and mitotic activity showed that 34% of the GISTs were of the high risk group. Forty two patients were suggestive of surgery as the primary treatment after presentation.

**Conclusion:** Abdominal pain was the most common presenting complaint. Majority of the tumors aroused from the stomach. The majority of the tumors had pure spindle cell morphology and 93% of the tumors were CD-117 positive. A significant relationship between tumor size, tumor necrosis and mitotic activity with large tumors having necrosis and high mitotic rate having high risk of malignancy, was observed. Surgical resection is considered mainstay of treatment of gastro-intestinal stromal tumor. Imatinib therapy should be given to patients in moderate to severe risk categories.

© 2019 Sociedade Brasileira de Coloproctologia. Published by Elsevier Editora Ltda. This is an open access article under the CC BY-NC-ND license (<http://creativecommons.org/licenses/by-nc-nd/4.0/>).

\* Corresponding author.

E-mail: [drsshankar@gmail.com](mailto:drsshankar@gmail.com) (S. Subramanian).<https://doi.org/10.1016/j.jcol.2019.09.006>2237-9363/© 2019 Sociedade Brasileira de Coloproctologia. Published by Elsevier Editora Ltda. This is an open access article under the CC BY-NC-ND license (<http://creativecommons.org/licenses/by-nc-nd/4.0/>).

## Aspecto clínico e patológico dos tumores estromais gastrointestinais em hospital terciário da Índia

### R E S U M O

#### Palavras-chave:

Tumores estromais  
gastrointestinais  
Imuno-histoquímica  
CD-117, CD-34

**Justificativa:** Este estudo define o perfil da doença na população do sul da Índia e determina os aspectos clínicos e patológicos dos tumores estromais gastrointestinais.

**Método:** Neste estudo prospectivo, os pacientes diagnosticados com tumor estromal gastrointestinal foram submetidos a um exame clínico completo, e uma série de dados dos pacientes, incluindo detalhes antropométricos e clínicos, foram analisados. Os dados patológicos incluíram tamanho do tumor, presença ou ausência de necrose, contagem mitótica e imuno-histoquímica para CD-117, CD-34.

**Resultados:** Havia 44 pacientes com diagnóstico confirmado de tumor estromal gastrointestinal. A maior incidência foi encontrada na 6ª década de vida. Os sintomas mais comuns foram dor abdominal e sangramento gastrointestinal. O estômago foi o local mais frequente para tumores estromais gastrointestinais. A imuno-histoquímica para CD-117 foi positiva em 93,18% dos casos. A maioria dos tumores (79,5%) apresentava morfologia pura de células fusiformes e a atividade mitótica mostrou que 34% dos GISTs pertenciam ao grupo de alto risco. Quarenta e dois pacientes receberam indicação para cirurgia como tratamento primário após a apresentação.

**Conclusão:** A dor abdominal foi a queixa mais comum. A maioria dos tumores afetava o estômago, apresentava morfologia pura de células fusiformes e 93% eram CD-117 positivos. Foi observada uma relação significativa entre o tamanho do tumor, a necrose tumoral e a atividade mitótica, com os tumores grandes apresentando necrose e alta taxa mitótica com alto risco de malignidade. A ressecção cirúrgica é considerada o principal tratamento do tumor estromal gastrointestinal. A terapia com imatinibe deve ser administrada a pacientes em categoria de risco de moderadas a grave.

© 2019 Sociedade Brasileira de Coloproctologia. Publicado por Elsevier Editora Ltda. Este é um artigo Open Access sob uma licença CC BY-NC-ND (<http://creativecommons.org/licenses/by-nc-nd/4.0/>).

### What is already known?

The complexities of Gastro-Intestinal Stromal Tumors make it hard to establish a universally followed treatment algorithms.

Supervision of these tumors is individualized, depending on patient characteristics, morphology of tumor, molecular characteristic and clinical activities of the disease.

Most of reports have been published from developed countries and there is an insignificant data present in public domain from our country on clinical aspect of GISTs.

### What is new in this study?

This study could be first from south Asia defining the GISTs profile in south Indian population and its clinic-pathological aspects.

### What are the future clinical and research implications of the study findings?

Larger numbers of patients with high-risk GIST need to be followed-up after adjuvant imatinib therapy for meaningful conclusions to be drawn from our patients.

Molecular studies of KIT and PDGFRA gene mutations need to be correlated with treatment protocols

Patterns of KIT expression and morphological differentiation can occur in GISTs treated with imatinib that develop resistance to therapy.

### Introduction

Gastrointestinal Stromal Tumor (GIST), first discovered in 1998 is gastrointestinal neoplasms virtually positive to tyrosine kinase KIT (CD-117) receptor in immunohistochemically and mutations of KIT gene leading to ligand-independent.<sup>1,2</sup> Although there a small GIST fraction does not demonstrate these properties assumed to be having alternative pathogenetic mechanisms. The most important characteristic of gastrointestinal neoplasm is that a benign activity of GISTs is not possible to identify from histopathology. Until now therapeutic diagnosis takes leads from empirically scoring systems anticipated to predict possible malignancy risk. GISTs are extremely heterogeneous from a clinical perspective. They may perhaps occur in the complete gastrointestinal tract anywhere linking the lower esophagus and the anal canal.<sup>3,4</sup> The complexity of GISTs and its clinical heterogeneity make it very hard to establish a universally followed treatment algorithms, and therefore supervision of these tumors is individualized, depending on patient characteristics, morphology

of tumor, molecular characteristic and clinical activities of the disease.<sup>5-7</sup>

Most of reports have been published from developed countries and there is an insignificant data present in public domain from our country on clinical aspect of GISTs. Here in this study, we present the oncological aspects of GISTs with its clinical, pathologic, profile, clinic pathologic variants associated to tumor site and pathogenesis. This study is aimed at defining the disease profile in south Indian population and at determining the clinic-pathological aspects of Gastro-Intestinal Stromal Tumors which includes clinical presentation, morphology (gross and microscopic), location of tumors, risk stratification and management among patients hailing from the South Indian state of Tamil Nadu.

## Materials and methods

We conducted a prospective study carried out at Sri Ramachandra University between October 2013 to February 2016, on patients who were diagnosed and managed as a case of Gastrointestinal Stromal Tumors. The study was approved and designed by Institutional ethical review board, SRIHER, Chennai, India. Patients were enrolled in study after getting their consent in written.

On admission detailed history was taken and thorough clinical examination was done. Diagnosis of GIST was based on symptoms and clinical presentation, severity and extent of disease at presentation, endoscopy findings, and anatomical site and biopsy results. An qualified pathologist reviewed all tumours for verification of diagnosis and evaluation of immuno-histochemical characteristics.

A database of Anthropometric details such as age, sex, past medical history, and clinical presentation, drug history, adjuvant therapy and type of surgical resection, was created for patients diagnosed with GISTs. Patient tumors characteristics were analyzed. Pathological data included tumor size, presence or absence necrosis, mitotic counts, immunohistochemistry for CD-117, CD-34.

Resection was considered complete when whole gross ailment was removed despite of microscopic margins. When gross residual ailment was present at the end of resection process, resection was classified incomplete. Standard hematoxylin and eosin staining was performed in addition to specific immunohistochemical staining for CD-34 and CD-117. Pathological examination was performed using standard hematoxylin and eosin staining and specific immunohistochemical techniques. Tumor was classified into epithelioid type, spindle cell, and mixed type. As per Fletcher criteria, tumors were categorized into classes depending upon size and mitotic count. Patients were categorized as high and intermediate risk and considered for adjuvant chemotherapy with imatinib mesylate.

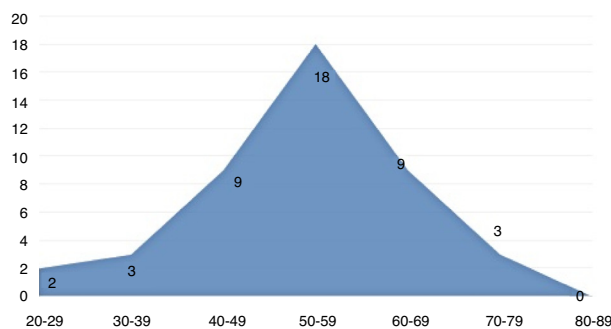
## Results

### Anthropometric data

During the period from February 2010 to February 2016 there were 44 patients (30 males and 14 females) with confirmed

**Table 1 – Age distribution of study cases.**

Age in years	Number	Percentage
20-29	2	4.50%
30-39	3	6.80%
40-49	9	20.45%
50-59	18	40.90%
60-69	9	20.45%
70-79	3	6.80%



**Fig. 1 – Hist wide spectrum of histologic features of gastric gist. (A) Paucicellular tumor with sclerosing matrix. (B) Perinuclear vacuolization and nuclear palisading. (C) Epithelioid cytology (D) Sarcomatoid appearance with numerous mitoses.**

**Table 2 – Common symptoms of GISTs.**

S n <sup>o</sup>	Presentation	Number
1	Abdominal Pain	29
2	Gastrointestinal bleed	18
3	Weight loss	11
4	Abdominal mass	3
5	Abdominal distension	2
6	Vomiting	9
7	Dyspepsia	14
8	Asymptomatic	3

diagnosis of GIST. The age distribution ranges from 3rd decade to 7th decade. The youngest patient's age was 29 and oldest being 75. The mean age of presentation was 57.14. The highest incidence was found in the 6th decade (Table 1 and Fig. 1). The most common symptoms was abdominal pain (n = 29) followed by gastrointestinal bleed (n = 18) and weight loss (n = 11). The other symptoms were vomiting (n = 9), abdominal distension, change in bowel habit, abdominal mass, dyspepsia and three cases were asymptomatic (Table 2).

### Primary site

Stomach was most frequent site for GISTs (52% of all GISTs) (Table 3), followed by other GIS track organs such as the small intestine, colon-rectum, and esophagus. In small intestine region, jejunum was the frequent site (n = 15) followed by ileum (n = 2). No considerable disparity was observed in frequency of the primary site of tumor between both sexes.

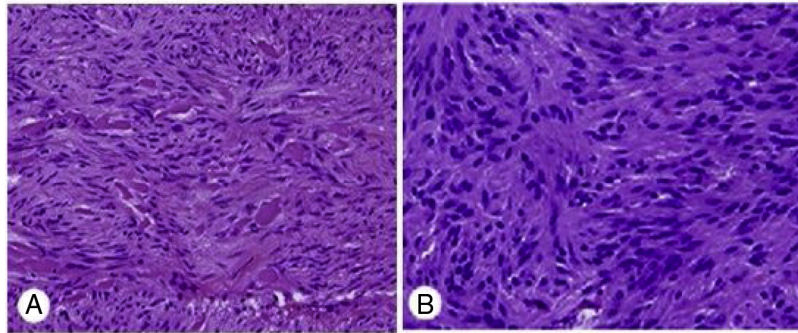


Fig. 2 – (A) Gastric gist stained with CD-117; (B) Gastric gist stained with CD-34.

Primary site	Number	Percentage
Esophagus	0	0
Duodenum	2	4.50%
Stomach	23	52.27%
Small intestine	16	36.36%
Colon	0	0%
Rectum	1	2.20%
Retroperitoneum	2	4.50%

**Immuno-histochemistry**

Immunochemistry for CD-117 was positive in 41 of the 44 cases (93.18%) and negative in three cases, CD-34 was positive in 37 of the 44 cases (84%), PDGFR was positive in 3 cases (Fig. 2).

**Histology**

Histological staining H&E showed wide spectrum gastric GIST characteristic included paucicellular tumor with sclerosing matrix (Fig. 3A), perinuclear vacuolization and nuclear palisading (Fig. 3B), epithelioid cytology (Fig. 3C) and sarcomatoid appearance with numerous mitoses (Fig. 3D). Majority of tumors (79.5%) had pure spindle cell morphology and only few (n=4; 9%) were having pure epithelioid cell morphology. The other type such as mixed spindle and epithelioid cell morphology was seen in only 5 (11.3%) of the cases (Fig. 4).

**Mitosis/HPF**

Mitotic activity was evaluated to assign tumors into risk groups as per Fletcher et al. description. The overall categorization of risk groups was based on size and mitotic activity showed that 34% of the GISTs were of the high risk group, 18% were of the intermediate-risk group, with 43% and 4.5% in the low and/or very-low-risk groups, respectively. 46.6% of the high risk GISTs was situated in the stomach followed by 33% in the small intestine (Table 4).

**Necrosis and tumor size**

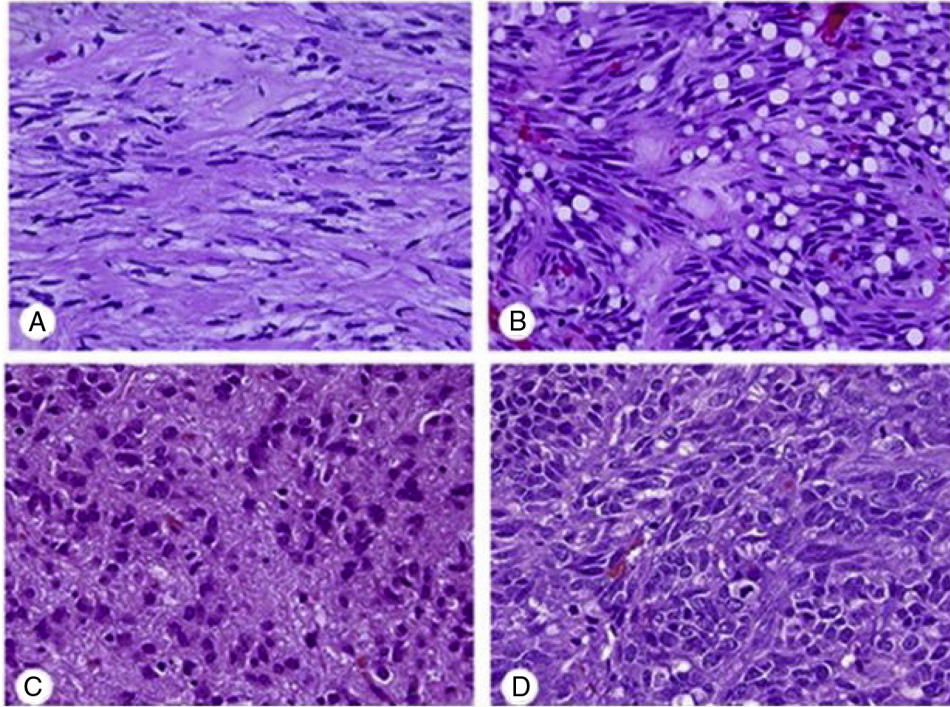
Necrosis was present in 17 (38%) cases. Necrosis was seen in 26% of gastric GISTs, 41% small intestinal, 50% duodenal and 100% retroperitoneal and rectal GISTs. Majority of the GISTs

	Very low	Low	Intermediate	High
No of cases	2	19	8	15
Male	1	11	7	8
Female	1	8	1	7
Site				
Stomach	1	14	1	7
Small intestine	1	4	7	4
Duodenum	0	1	0	1
Rectum	0	0	0	1
Retroperitoneum	0	0	0	2
Cytological features				
Spindle	1	15	7	12
Epithelioid	1	2	0	1
Mixed	0	2	1	2
Necrosis				
Absent	2	19	5	2
Present	0	0	3	13

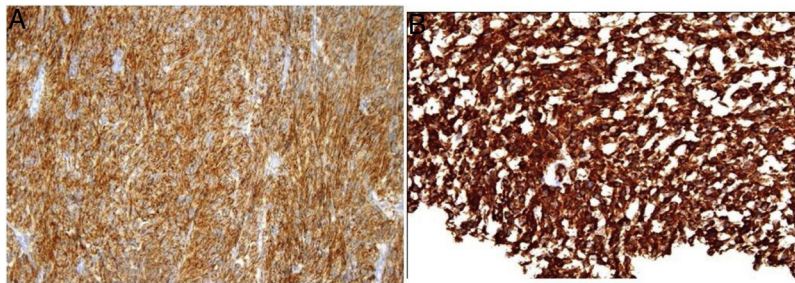
(50%) ranged in size from 5 to 10 cm, 29.5% were less than 5 cm, where as 20.4% of the lesions were more than 10 cm which are categorized definitely malignant with status of high-risk group. Majority of the large sized lesions were found in the stomach whereas majority of the small GISTs were in the small intestine.

**Surgery**

Forty two patients were suggestive of surgery as the primary treatment after presentation. Two were advised neoadjuvant chemotherapy- one was a case of duodenal GIST with liver metastasis and the other one was a case of low rectal GIST which subsequently underwent video assisted transanal excision. Among the 42 patients, 40 patients underwent R0 resection while one patient underwent R1 and one R2 resection and both these patients were having retroperitoneal GISTs. Among the gastric GISTs, 12 patients had laparoscopic sleeve gastrectomy, 7 patients underwent open sleeve gastrectomy due to difficult tumor location and large size. Three patients were subjected to subtotal gastrectomy. One patient had a gastric GIST near the fundus and was subjected to proximal subtotal gastrectomy (Fig. 5A). One case having GIST in first part of duodenum was subjected to laparoscopic sleeve resection. One case was found to have a large jejunal GIST which was infiltrating into the hepatic flexure of colon (Fig. 5B),



**Fig. 3 – The highest incidence of GIST was found in the 6th decade.**

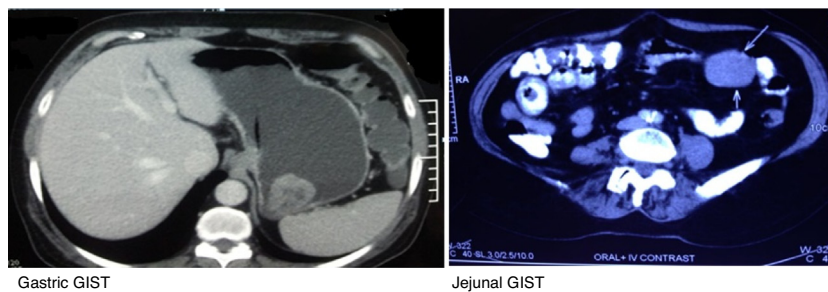


**Fig. 4 – The most common primary site was the stomach in our study.**

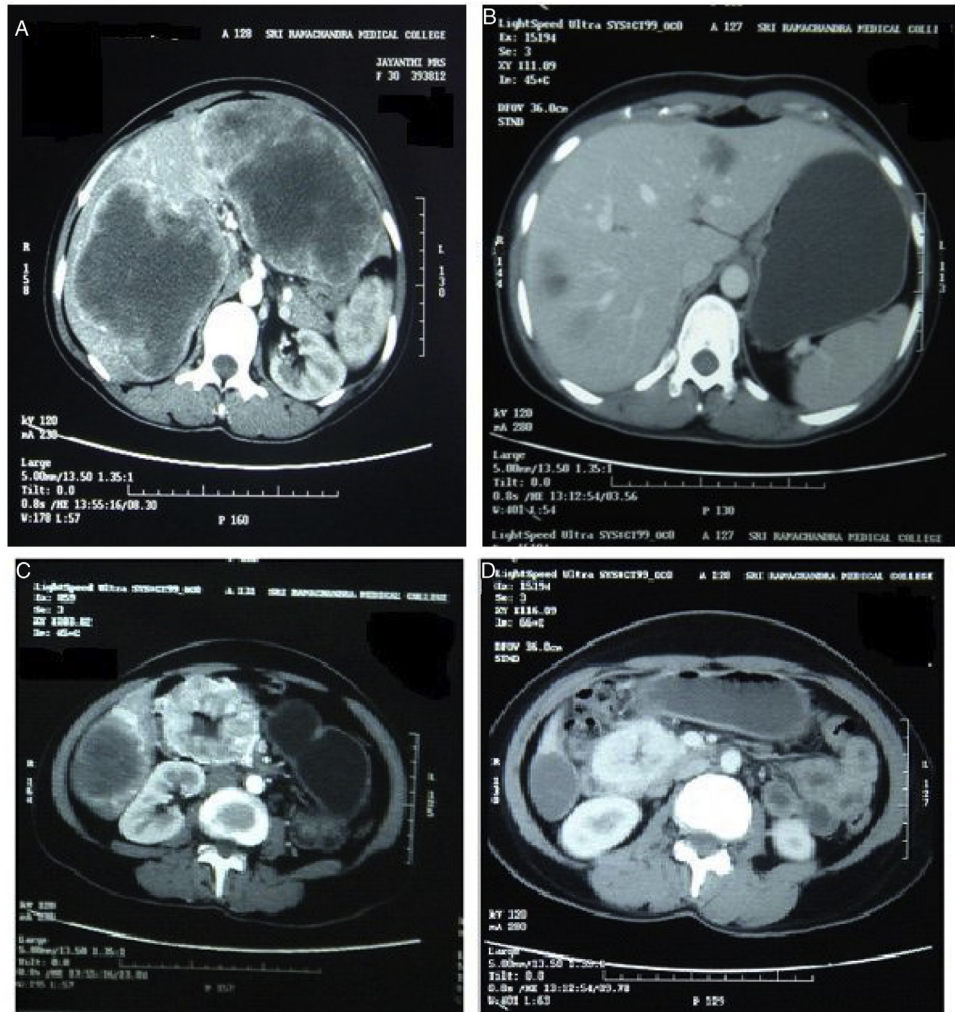
requiring extended right hemicolectomy along with jejunal resection to ensure R0 resection. All the ileal GISTs comfortably underwent R0 resection. One of the cases having retroperitoneal GIST was initially operated at outside hospital with diagnosis of pseudocyst of pancreas and had undergone cysto-jejunostomy.

During exploration it was found to be a GIST and hence the tumor along with the roux limb of the jejunum was excised

with negative margins. Out of the two patients put on neoadjuvant therapy, one patient having duodenal GIST with liver metastasis had a very good response to imatinib therapy leading to a complete resolution of metastatic lesions in the liver and decrease in the size of primary lesion, but the patient was subsequently lost to follow up (Fig. 6). The second patient having low rectal GIST was given neoadjuvant imatinib for three months which resulted in 70% shrinkage in tumor size and



**Fig. 5 – Histological appearance of small intestinal gist. (A) Spindle cell tumor with extracellular collagen globules. (B) Nuclear zones reflecting prominent cell processes.**



**Fig. 6 – (A) CT scan showing liver metastasis. (B) Dramatic response to imatinib mesylate with complete disappearance of liver metastasis. (C and D) CT showing unresponsive primary tumour in the duodenum.**

subsequently he underwent trans anal excision. Twenty three patients, belonging to high risk category and eight belonging to intermediate risk category were put on adjuvant imatinib therapy.

## Discussion

Although GISTs of the gastrointestinal tract are very common non-epithelial neoplasms but their clinical behaviors have remained poorly understood. We analyzed GIST clinical profile based on results with 44 patients and reviewed their oncological aspects and clinicopathologic variants associated with tumor site and pathogenesis. As earlier reports of western literature stated GIST as frequent mesenchymal tumor of the GIT, our study do had similar results.<sup>8</sup> The maximum incidence of GIST was reported from 5th (25%) and 6th decades (36.3%) with mean age of 56 years very similar to published report,<sup>9,10</sup> however it was a decade higher than those reported from Indian sub continent.<sup>11,12</sup> Abdominal pain (65.9%) and gastrointestinal bleeding (40.9%), were comments clinical features in this study supporting the earlier

findings.<sup>9,13-15</sup> Although Endoscopic Ultrasonography (EUS) shows GIST as a hypoechoic and play role in guided biopsy, we suggest that laparoscopic biopsy, preoperative percutaneous should be dejected due to increased risk of hemorrhage, tumor split and peritoneal spillage. The most prevalent site of GIST was stomach following small intestine as other investigators reported previously.<sup>13,16-18</sup>

CD-117 (KIT) expression was positive in 93.18% of our cases, indicting its importance I GIST diagnosis and emphasizing that CD-117 immunochemistry can be used as mandatory test to confirm the judgment of GIST. The negative case for CD-117 expression (6.82%) may be attributed to the presence of activated mutation of Platelet-Derived Growth Factor Receptor $\alpha$  (PDGFRA).<sup>19,20</sup> Most tumors in the study (79.5%) had pure spindle cell morphology; pure epitheloid cell morphology was seen in only four cases (9%). Only 11.3% of the tumors had combined spindle and epitheloid cell cytomorphology, unlike the literature, which documents that combined morphology is present in most GISTs.<sup>11,12</sup>

Study showed that more than half GISTs (54.5%) ranged between 5–10 cm, and only 18.1% of the lesions were  $\geq$ 10 cm

which were categorized as definitely malignant and considered high-risk group. Tumor size considerably proportional to mitotic count; and so larger tumors were usually having higher mitotic counts. According to earlier studies different risk categories was compiled based on primary tumor size and mitotic counts per 50 HPF. Majority of the patients 43% belonged to low risk category, 34% were of the high-risk/malignant category, with (18%) being of the intermediate risk group. Our results were similar to earlier reported frequency in literature.<sup>11,12</sup>

Necrosis was present in 17 cases (38%). Majority of the high risk group (86.66%) and 37.5% of the intermediate risk group had necrosis whereas it was altogether absent in low and very low risk groups. This indicates that presence of necrosis is a sign of increased risk of malignancy. Site specific wise, 26% of the gastric GISTs, 41% small intestinal GISTs and 100% of the GISTs at other sites had necrosis. These findings are in agreement with the fact that extragastric GISTs carry an extra risk of malignant transformation. In a study by V Bertolini et al.<sup>21</sup> on 113 cases of GISTs, necrosis was seen in 17% of the gastric GISTs, 62% of the small intestinal GISTs had necrosis with overall incidence of 32% which is comparable to our study.

Out of 42 patients with GISTs, we were able to perform a complete macroscopic resection which was based on absence of gross disease avoiding tumor split with achieving negative margins. To perform an absolute resection 1-2 cm margin was suggested to be sufficient. Dematteo et al.<sup>22</sup> has stated it is tumor size and not a negative microscopic edge which is required for determining survival. In this study entire macroscopic resection was undertaken in 40 out of 42 patients.

It is now well established that GISTs do express the KIT which postulated the hypothesis that targeting KIT protein via suppression of KIT receptor tyrosine kinase would be much useful in therapy at same time it can be also used as diagnostic and predictive marker for GIST.<sup>19,23</sup> Generally GISTs are resistant to radiation therapy including conventional chemotherapy. Treatment of GIST is now shifted towards use of Kit/PDGFR tyrosine kinase inhibitors like imatinib (Gleevec) and being successful in the treatment of unresectable or recurrent GISTs. A couple of studies have shown use of Imatinib to reduce the size of GIST before resection and as oral therapy it demonstrated good response against metastatic GISTs<sup>23</sup> in the majority of patients. The survival of patients with metastatic and GIST has improved dramatically with use of imatinib mesylate which was supported in our study leading to a complete resolution of metastatic lesions in the liver and decrease in the size of primary lesion. In this study, two patients, one having duodenal GIST with liver metastasis and other one having large rectal GIST received neoadjuvant imatinib. Adjuvant imatinib management after surgical resection is valuable in high-risk tumors and is being characterized in several ongoing clinical trials. A pilot study carried out on cases with high-risk GIST showed that no recurrences occurred within 2 years when patients received adjuvant imatinib for over a one year after complete curative resection when compared with historical controls without imatinib therapy that had 67% recurrence.<sup>22</sup> In our study 23 patients majority with high risk tumors, who received adjuvant imatinib therapy after curative resections showed stable disease, which supports evidence that adjuvant imatinib after curative resections in the high-risk

category decreases incidence of recurrence.<sup>24</sup> Although imatinib has shown potential for reducing the tumor size before resection, long-term success might be limited as there is report of developing imatinib resistance via clonal selection or secondary mutations.<sup>27</sup> Having knowledge of site and type of mutations with the copy numbers of both c-Kit and PDGFRA genes would certainly provide information helpful in predicting if tumors could respond to therapy or might develop resistance.<sup>23</sup> However, KIT mutation studies have not been carried out in this study as it has been revealed that KIT mutation status is a self-regulating prognostic factor in GIST.<sup>23,24</sup>

Larger numbers of patients with high-risk GIST need to be followed-up after adjuvant imatinib therapy for meaningful conclusions to be drawn from our patients. Molecular studies of KIT and PDGFRA gene mutations also need to be correlated with these treatment protocols and outcomes as it has been recently shown that changing patterns of KIT expression and morphological differentiation can occur in GISTs treated with imatinib that develop resistance to therapy.<sup>25,26</sup>

## Conclusion

In this prospective study on 44 patients diagnosed with GIST, majority of the patients were men in the 5-6th decade of life. Abdominal pain was the most common presenting complaint. Majority of the tumors arose from the stomach. The majority of the tumors had pure spindle cell morphology and 93% of the tumors were CD-117 positive. A significant relationship between tumor size, tumor necrosis and mitotic activity with large tumors having necrosis and high mitotic rate having high risk of malignancy, was observed. Surgical resection is considered mainstay of treatment of GIST. Imatinib therapy should be given to patients in moderate to severe risk categories.

## Ethics approval and consent to participate

The study was approved and designed (CSP-Med/14/April/15/109) by Institutional ethical review board, SRIHER, Chennai, India. Patients were enrolled in study after getting their consent in written.

## Conflicts of interest

The authors declare no conflicts of interest.

## Acknowledgments

Authors acknowledge the support and help provided by SRIHER, Chennai India. (CSP-Med/14/April/15/109).

## REFERENCES

- Hirota S, Isozaki K, Moriyama Y, Hashimoto K. Gain-of-function mutations of c-kit in human gastrointestinal stromal tumors. *Science*. 1998;279:577-80.
- Kindblom LG, Remotti HE, Aldenborg F, Meis-Kindblom JM. Gastrointestinal pacemaker cell tumor (GIPACT):

- gastrointestinal stromal tumors show phenotypic characteristics of the interstitial cells of Cajal. *Am J Pathol*. 1998;152:1259–69.
3. Nilsson B, Bümming P, Meis-Kindblom JM, Odén A, Dortok A, Gustavsson B, et al. Gastrointestinal stromal tumors: the incidence, prevalence, clinical course, and prognostication in the preimatinib mesylate era – a population-based study in western Sweden. *Cancer*. 2005;103:821–9.
  4. Tryggvason G, Gíslason HG, Magnússon MK, Jónasson JG. Gastrointestinal stromal tumors in Iceland, 1990–2003: the Icelandic GIST study, a population-based incidence and pathologic risk stratification study. *Int J Cancer*. 2005;117:289–93.
  5. Thomas RM, Sobin LH. Gastrointestinal cancer. *Cancer*. 1995;75 1 Suppl:154–70.
  6. Tran T, Davila JA, El-Serag HB. The epidemiology of malignant gastrointestinal stromal tumors: an analysis of 1,458 cases from 1992 to 2000. *Am J Gastroenterol*. 2005;100:162–8.
  7. Goettsch WG, Bos SD, Breekveldt-Postma N, Casparie M, Herings RM, Hogendoorn PC. Incidence of gastrointestinal stromal tumors is underestimated: results of a nation-wide study. *Eur J Cancer*. 2005;41:2868–72.
  8. Miettinen M, Lasota J, Sobin LH. Gastrointestinal stromal tumors of the stomach in children and young adults: a clinicopathologic, immunohistochemical and molecular genetics study of 44 cases with long-term follow-up and review of the literature. *Am J Surg Pathol*. 2005;29:1373–81.
  9. De Matteo RP, Lewis JL, Leung J. Two-hundred gastrointestinal stromal tumors: recurrence pattern and prognostic factors for survival. *Ann Surg*. 2000;231:51–8.
  10. Bhalgami R, Manish K, Patil P, Mehta S, Mohandas KM. Clinicopathological study of 113 gastrointestinal stromal tumors. *Indian J Gastroenterol*. 2013;32:22–7.
  11. Rajappa S, Muppavarapu KM, Uppin S, Digumarti R. Gastrointestinal stromal tumors: a single institution experience of 50 cases. *Indian J Gastroenterol*. 2007;26:225–9.
  12. Rauf F, Bhurji Y, Pervez S. Gastrointestinal stromal tumors: a demographic, morphologic and immunohistochemical study. *Indian J Gastroenterol*. 2007;2:214–6.
  13. Mucciarini C, Rossi G, Bertolini F, Valli R, Cirilli C, Rashid I, et al. Incidence and clinicopathologic features of gastrointestinal stromal tumors. A population based study. *BMC Cancer*. 2007;7:230.
  14. Rabin I, Chikman B, Lavy R, Sandbank J, Makalkovsky M, Gold-Deutch R, et al. Gastrointestinal stromal tumors: a 19 year experience. *Isr Med Assoc J*. 2009;11:98–102.
  15. Hueman MD, Schulick RD. Management of Gastrointestinal stromal tumors. *Surg Clin North Am*. 2008;88:599–614.
  16. Miettinen M, El-Rifai W, H L Sobin L, Lasota J. Evaluation of malignancy and prognosis of gastrointestinal stromal tumors: a review. *Hum Pathol*. 2002;33:478–83.
  17. Miettinen M, Lasota J. Gastrointestinal stromal tumors: review on morphology, molecular pathology, prognosis, and differential diagnosis. *Arch Pathol Lab Med*. 2006;130:1466–78.
  18. Dematteo RP, Heinrich MC, El-Rifai WM, Demetri G. Clinical management of gastrointestinal stromal tumors: before and after STI-571. *Hum Pathol*. 2002;33:466–77.
  19. Ghanem N, Altehoefer C, Furtwangler A, Winterer J, Schafer O, Springer O, et al. Computed tomography in gastrointestinal stromal tumors. *Eur Radiol*. 2003;13:1669–78.
  20. Medeiros F, Corless CL, Duensing A, Hornick JL, Oliveira AM, Heinrich MC, et al. KIT negative gastrointestinal stromal tumors: proof of concept and therapeutic implications. *Am J Surg Pathol*. 2004;28:889–94.
  21. Bertolini V, Chiaravalli AM, Klersy C, Placidi C, Marchet S, Boni L, et al. Gastrointestinal stromal tumors—frequency, malignancy, and new prognostic factors: the experience of a single institution. *Pathol Res Pract*. 2008;204:219–33.
  22. Dematteo RP, Heinrich MC, El-Rifai WM, Demetri G. Clinical management of gastrointestinal stromal tumors: before and after STI-571. *Hum Pathol*. 2002;33:466–77.
  23. Gold JS, Dematteo RP. Combined surgical and molecular therapy: the gastrointestinal stromal tumor model. *Ann Surg*. 2006;244:176–84.
  24. Nilsson B, Sjolund K, Kindblom LG, Meis-Kindblom JM, Bümming P, Nilsson D, et al. Adjuvant imatinib treatment improves recurrence free survival in patients with high-risk gastrointestinal stromal tumours (GIST). *Br J Cancer*. 2007;96:1656–8.
  25. Mochizuki Y, Kodera Y, Ito S, Yamamura Y, Kanemitsu Y, Shimizu Y, et al. Treatment and risk factors for recurrence after curative resection of gastrointestinal stromal tumors of the stomach. *World J Surg*. 2004;28:870–5.
  26. Pauwels P, Debiec-Rychter M, Stul M, De Wever I, Van Oosteroin AT, Sciot R. Changing phenotype of gastrointestinal stromal tumours under imatinib mesylate treatment: a potential diagnostic pitfall. *Histopathology*. 2005;47:41–7.
  27. Lasota J, Miettinen M. Clinical significance of oncogenic KIT and PDGFRA mutations in gastrointestinal stromal tumors. *Histopathology*. 2008;53:245–66.