




Review Article

Management of inflammatory bowel diseases in urgent and emergency scenario^{*}



Carlos Augusto Gomes ^{a,*}, Mauro Podda^b, Sabrina Carpanez Veiga^c,
Tayenne do Vale Cabral^c, Luiza Verardo Lima^c, Lorena Costa Miron^c,
Vanessa de Lucas Oliveira^c, Gabriel Lunardi Aranha^c

^a Faculdade de Ciências Médicas e da Saúde de Juiz de Fora (SUPREMA), Hospital Universitário Therezinha de Jesus, Departamento de Cirurgia, Juiz de Fora, MG, Brazil

^b Cagliari University Hospital, Department of Surgical Science, Cagliari, Italy

^c Faculdade de Ciências Médicas e da Saúde de Juiz de Fora (SUPREMA), Hospital Universitário Therezinha de Jesus, Juiz de Fora, MG, Brazil

ARTICLE INFO

Article history:

Received 20 June 2019

Accepted 28 October 2019

Available online 24 December 2019

Keywords:

Inflammatory bowel diseases

Emergencies

Complications

ABSTRACT

Objective: To review the main acute complications of inflammatory bowel disease in order to present the state of the art of their respective diagnosis and treatment.

Methods: A bibliographic search was conducted in Medline database using the following keywords: “inflammatory bowel disease”, “Colitis Ulcerative”, “Crohn Disease”, “emergency” among others that had their variation evaluated by the MESH. Articles from the last 10 years conducted with humans, written in Portuguese or English, and published in journals with impact factor greater than 1 were selected.

Results: After carrying out the search phrase and selecting the filters, 20 articles were selected to be included in the research. The most common acute complications were evaluated, focusing on their current propaedeutic and management aspects.

Conclusion: Most emergencies related to inflammatory bowel disease should be treated non-operatively firstly, prioritizing patient hemodynamic state. In selected cases of life-threatening complications emergent operative treatment are mandatory. The timing of procedure is the most important aspect. As general rule, in Crohn’s Disease, operative treatment should be postponed as much as possible and the resection as small as possible. In case of ulcerative rectocolitis, if the hemodynamic state of the patient allows, proctocolectomy should be expedited with curative intention.

© 2019 Sociedade Brasileira de Coloproctologia. Published by Elsevier Editora Ltda. This is an open access article under the CC BY-NC-ND license (<http://creativecommons.org/licenses/by-nc-nd/4.0/>).

^{*} Institution: Faculdade de Ciências Médicas e da Saúde de Juiz de Fora – SUPREMA.

^{*} Corresponding author.

E-mail: carlos.gomes@suprema.edu.br (C.A. Gomes).

<https://doi.org/10.1016/j.jcol.2019.10.012>

2237-9363/© 2019 Sociedade Brasileira de Coloproctologia. Published by Elsevier Editora Ltda. This is an open access article under the CC BY-NC-ND license (<http://creativecommons.org/licenses/by-nc-nd/4.0/>).

Manejo das doenças inflamatórias intestinais na urgência e emergência

R E S U M O

Palavras-chave:

Doença inflamatória intestinal
Emergências
Complicações

Objetivo: Revisar as principais complicações agudas das doenças inflamatórias intestinais, a fim de apresentar o estado da arte de seus respectivos diagnósticos e tratamentos.

Métodos: Foi realizada uma pesquisa bibliográfica no banco de dados Medline, utilizando as seguintes palavras-chave: “doença inflamatória intestinal”, “Colite Ulcerativa”, “Doença de Crohn”, “emergência” entre outras que tiveram sua variação avaliada pelo MESH. Artigos dos últimos 10 anos realizados com seres humanos, escritos em português ou inglês, e publicados em periódicos com fator de impacto maior que um foram selecionados.

Resultados: Após a construção da frase de pesquisa e seleção dos filtros, 20 artigos foram selecionados para inclusão no estudo. As complicações agudas mais comuns foram avaliadas, enfocando seus atuais aspectos propedêuticos.

Conclusão: A maioria das emergências relacionadas à doença inflamatória intestinal deve ser tratada primariamente de forma não cirúrgica, priorizando a hemodinâmica do paciente. Em casos selecionados de complicações potencialmente fatais, tratamento cirúrgico de emergência é mandatório. O momento do procedimento é o aspecto mais importante. Como regra geral, na Doença de Crohn, o tratamento cirúrgico deve ser adiado ao máximo com ressecção menor possível. No caso de retocolite ulcerativa, se o estado hemodinâmico do paciente permitir, a proctocolectomia deve ser realizada com intenção curativa.

© 2019 Sociedade Brasileira de Coloproctologia. Publicado por Elsevier Editora Ltda. Este é um artigo Open Access sob uma licença CC BY-NC-ND (<http://creativecommons.org/licenses/by-nc-nd/4.0/>).

Background

Inflammatory Bowel Diseases (IBDs) comprise chronic inflammatory bowel disorders, having Crohn's Disease (CD) and Ulcerative Rectocolitis (URC) as main representatives, both considered to be related to abnormal immune response. In URC, inflammation is diffuse and restricted to the mucosa, causing its continuous involvement and affecting the rectum, although it can extend to the entire colon. In CD, the lesions are discontinuous, affecting all layers of the intestinal wall (transmural) and located in any segment of the gastrointestinal tract.^{1,2}

The clinical picture of both diseases may resemble. The diagnosis is made through clinical, endoscopic, radiological, and histological data. Among the acute complications that require urgent or emergency care includes: infectious complications such as intra-abdominal abscesses, colitis caused by *Clostridium* and Cytomegalovirus (CMV), anomalies of motor function of intestinal transit progression such as Toxic Megacolon (TM), intestinal hemorrhage and intestinal obstructions and perforations. About 20 % of patients with UC and 80 % of CD will undergo surgical intervention during their lifetime. The surgery offers a good quality of life for UC patients, the same outcome is less noted in patients with CD, whose will go undergone some surgical interventions in the majority of cases. Laparoscopic approach has replaced laparotomy in tertiary centers. Laparoscopic proctocolectomy and restorative IPAA is becoming the standard of care in the treatment of UC and laparoscopic ileo-cecal resection is already the new gold standard in the treatment of stenotic CD of terminal ileum. The timing of surgery is a key issue for proper management of IBD patients. Laparoscopic approach is less studied in the

emergency scenario, but the option increases specially in tertiary centers. The study aimed a narrative and comprehensive reviewed of the main emergencies observed in patients with IBD, in the last 10 years highlighting its temporal changes.³⁻⁷

Method

A bibliographic search was conducted in the MedLine database using the following keywords: “inflammatory bowel disease”[ti] OR “Colitis, Ulcerative”[ti] OR “Crohn Disease”[ti] AND (emergencies OR emergency OR urgency OR peritonitis OR “Secondary Peritonitis” OR “Toxic Megacolon” OR “Intestinal Perforations” OR “Perforation, Intestinal” OR “Perforations, Intestinal” OR “Hemorrhage, Gastrointestinal” OR “Gastrointestinal Hemorrhages” OR hematochezia OR “gastrointestinal bleeding” OR “Intestinal Obstructions” OR “Obstruction, Intestinal” OR “intestinal obstruction”). From a total of 595 citations, studies in non-humans and languages other than English or Portuguese were excluded. Articles from the last 10 years were selected. Of 197 citations obtained, a new filter evaluated the impact factor of the scientific journal, excluding articles in journals with an impact factor lower than one, and adherence to the subject. Twenty articles remained and were included in the research.

Results/Discussion

Toxic megacolon

TM is defined as colonic dilatation greater than 6 cm, in the presence of acute colitis and signs of severe systemic

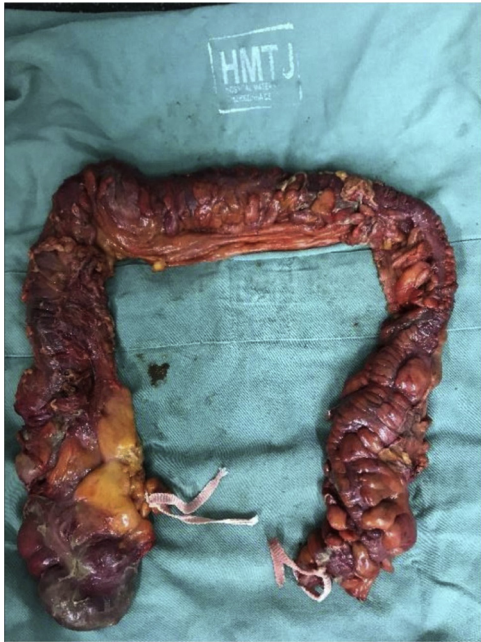

Fig. 1 – Operative specimen of proctocolectomy for toxic megacolon.

Table 1 – Clinical, laboratory and imaging findings in toxic megacolon.

Bloating and abdominal pain on palpation
Bloody diarrhea and tenesmus
Pallor
Fever (axillary temperature > 38.0 °C)
Tachycardia (HR > 100 bpm)
Shock signs (MAP < 70 mmHg)
Decreased peristalsis
Leukocytosis with left shift
Increased evidence of inflammatory activity (RCP)
Hydroelectrolytic disorders (hyponatremia, hypokalemia, hypochloremia, and hypoalbuminemia)
Radiological distension of colonic loops (≥ 6 cm)
The transverse colon is the most affected segment
CRP, C Reaction Protein; HR Heart Rate; MAP, Mean Arterial Pressure.

inflammatory response.⁸ About 10% of patients admitted with ulcerative colitis and 1%–5% of those with CD develop TM.⁶

The exact pathophysiology of TM remains unclear, but many studies postulate that it involves the presence of infection in a colon with previous ulcers, causing relaxation of the colonic smooth muscle and decreased gastrocolic reflex leading to significant dilatation of the affected colonic segment. Infection by CMV, *Shigella*, *Salmonella*, *Entamoeba*, enterohemorrhagic, *Escherichia coli*, and *Clostridium difficile* (C-diff – become more common due to the indiscriminate use of antibiotics) should be investigated (Fig. 1).^{6,8}

The diagnosis of TM is established when we had 3 of the 4 criteria below: 1) Temperature > 38.6 °C, 2) Tachycardia (> 120 bpm), 3) Leukocyte count > 10,500 mm³ with left shift, and 4) Anemia (hemoglobin or hematocrit < 60 % of normal) (Table 1).^{8,9}

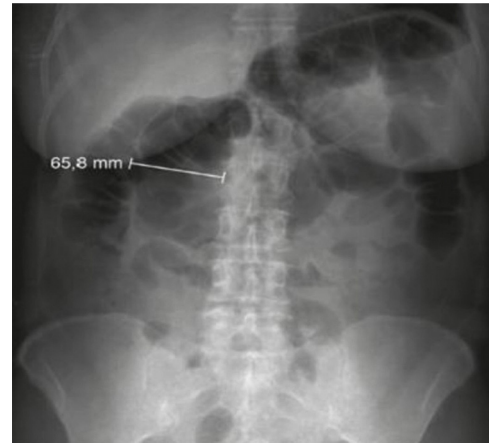

Fig. 2 – Plain abdominal radiography showing dilatation of the transverse colon.

Table 2 – Main aspects of non-operative and operative treatment of toxic megacolon.

Non-operative treatment
Venous hydration
Correction of electrolyte disorders
Fasting
Analgesia
Open NGT passage (decompression)
Change of lying position
Empirical antibiotic therapy
Intravenous hydrocortisone (100 mg, 8/8 h)
Thromboembolism prophylaxis
Operative treatment
Progressive clinical deterioration
Perforation
Fail of non-operative treatment (24–72 h)
NGT, Nasogastric Tube.

Diagnostic imaging examinations include plain abdominal radiography, which reveals colonic distension > 6 cm. Abdominal ultrasound and contrast-enhanced computed tomography are also useful in determining the cause or detecting perforation. Blood cultures are necessary to safely identify the pathogens involved, and empirical therapy should not be postponed (Fig. 2).⁶

TM is a life-threatening complication. The diagnosis and prompt treatment addressing the correction of hypovolemia, electrolyte disorders, abdominal compartment syndrome; administration of antimicrobials and operative treatment, is the priority and should be cautiously evaluated.⁸

Operative treatment should be considered in those cases that do not respond to intensive and antimicrobial care after 48–72 h or when the perforation is diagnosed. The technique of choice yet is total proctocolectomy with closure of the remaining rectum and terminal ileostomy. In elective condition, a second approach could be performed with an ileorectal anastomosis, if the rectum remains preserved or an ileoanal anastomosis with ileal reservoir, if the rectum is compromised (Table 2).^{6,8}

Table 3 – Main aspects in the treatment of massive gastrointestinal hemorrhage in intestinal bowel disease.

Step 1: clinical hemodynamic stabilization

Large-caliber peripheral venous accesses
 Massive blood replacement (crystalloids, 1500–2000 mL initially)
 Monitoring of hemodynamic status
 BP, HR, hemoglobin and hematocrit, indwelling bladder catheter)
 NPO or (nothing by mouth)
 Evaluate blood transfusion
 Step 2: treating the source of bleeding
 Locate the bleeding site (LGB × HGB): evaluate UGE and colonoscopy
 Complementary imaging: enteroscopy, scintigraphy and angiography
 Endoscopic treatment if possible
 Surgical approach (limit bowel resection)

NPO, Nothing Per Oros; LGB, Low Gastrointestinal Bleeding; HGB, High Gastrointestinal Bleeding; UGE, Upper Gastrointestinal Endoscopy.

Gastrointestinal bleeding

Massive gastrointestinal bleeding is one of the most difficult complications of IBD that requires emergency treatment; however, it is not so frequent. In cases of URC, the bleeding is usually diffuse and associated with extensive colitis. On the other hand, in cases of CD, it is more intensive, but its source is localized.¹⁰

Hemodynamic stabilization of the patient is the priority attitude of acute care surgeon. In a stable patient, the site and etiology of hemorrhage should be investigated. However, in unstable hemodynamic patients, despite resuscitative measures, emergency operative treatment is indicated. Once the cause of bleeding is known, specific management and prevention against new bleeding episodes should be immediately implemented (Table 3).^{7,11}

The bleeding should be classified according to the location: a clinical diagnosis of hematemesis and melena supports the hypothesis of High Gastrointestinal Bleeding (HGB), while enterorrhagia is indicative of Low Gastrointestinal Bleeding (LGB). However, massive HGB can manifest with hematochezia, and LGB with slow transit can cause melena. The passage of a nasogastric catheter, followed by gastric lavage, may be useful: the return blood or “coffee-ground” material strongly supports the hypothesis of HGB.^{7,12}

It is worth of note, that LGB is defined as hemorrhage into the gastrointestinal tract distal to the ligament of Treitz. In most cases of CD, the bleeding source is located in the small intestine, and its precise identification is essential to limit bowel resection. This can be achieved with careful exploration of small bowel, looking for a “bleeding tattoo” in the intestinal wall, or by an intra-operative enteroscopy. In addition, in difficult cases, because patient’s clinical status, transcatheter visceral angiography with embolization, may control the bleeding and postponed the operative treatment. This is especially indicated, when a significant bleeding is the first manifestation of the disease, the non-operative treatment failed and patient clinical health status is not good (angiography).¹³

In colonic bleeding, colonoscopy is the method of choice for identifying the source of bleeding, being used for diagnosis and therapy purposes. It is possible to examine the colon, without its previous cleaning, as the blood has a cathartic effect. Thus, when colonoscopy is unable to diagnosis the source or the bleeding is so massive, other diagnostic methods may be indicated. The scintigraphy with marked red blood cells may guide the performance of angiography. It is important take in mind, that contrasting tests (as opaque enema or intestinal transit) are contraindicated.^{4,7,10,13}

Scintigraphy is a sensitive modality, capable of detecting small continuous or intermittent bleeding with hemorrhagic flow from 0.1 mL/min. However, it has the disadvantage of inaccurate localization of source of bleeding. The great value of scintigraphy is to guide the need for arteriography for additional information: if positive, arteriography is indicated; if negative, arteriography is not indicated.^{4,7,13}

Arteriography is a slightly less sensitive examination, as it requires a hemorrhagic flow of 0.5–1.0 mL/min but has the advantage of accurate localization of the bleeding site and enables therapy through vasopressin injection or embolization of the bleeding artery. Therefore, some authors argue that it can be used directly, without the need for prior scintigraphy in cases of massive continuous bleeding.^{4,7,13}

The operative treatment of choice cases of URC, with heavy diffuse bleeding, is the proctocolectomy with primary ileorectal anastomosis, or terminal ileostomy and closure of the rectum or its exteriorization through the mucous fistula. However, if the source of bleeding is the rectum, its resection is necessary. In cases of CD, minimal resections should be performed due to the high risk of recurrence and other complications, attempting primary segment anastomosis whenever the patient’s clinical condition allows.^{10,11}

Intestinal obstruction

Intestinal obstruction is more frequent in CD than in URC. In both cases, it may originate in a benign or malignant process. During the natural course of CD, the patient may have a predominance of the fibrostenosing phenotype, responsible for high intestinal obstructions, usually due to benign annular lesions. Colonic obstruction due to CD is rare and may be associated with the presence of a tumor. Meanwhile, in cases of URC, the presence of obstruction due to stenosis should always raise the possibility of underlying colonic neoplasm as a primary cause of the obstruction.¹⁴

The clinical picture of intestinal obstruction usually begins with progressively worsening abdominal pain occurring in the epigastrium, periumbilical region, or, in distal obstructions, hypogastrium. Upon abdominal auscultation, at the beginning, hydro-aerial noises may be exacerbated, showing the presence of fighting peristalsis that evolves with a decrease or absence of peristaltic sounds. Moreover, the patient may experience nausea and vomiting. Conversely, abdominal distension is more frequent in cases of low intestinal obstruction. Impaired elimination of flatus and stool is also expected, above all complete intestinal obstruction. Rectal touch is an important step and can detect the presence of rectal tumors and assist in differential diagnoses such as fecaloma, foreign body, and uterine or ovarian tumors. During palpatory examination,

Table 4 – Treatment of intestinal obstruction in intestinal inflammatory disease.

Initial clinical treatment in suspected intestinal obstruction
Hospital clinical monitoring
Serial laboratory and radiological examinations
Oral fasting
Open NGT (decompression)
Caliber peripheral venous access
Venous hydration
Treatment of hydroelectrolytic disorders
Symptomatic treatment if necessary (analgesia, antiemetic's)
Empirical antibiotic therapy (immunosuppression, translocation)
Clinical evolution
Evaluate the degree of stenosis and elective surgery
Emergency surgery
Clinical deterioration, lack of response to conservative treatment, and complete obstruction

a palpable mass represents inflammatory plastron or tumors. When the patient develops with loop distress, bacteremia, or peritonitis, it is possible to notice changes in vital signs such as fever, tachycardia, and tachypnea – in most severe cases, septic shock may occur.¹⁴

In cases of obstructive acute abdomen, the first imaging is non-contrast radiology. Changes suggestive of obstruction are loop dilatation and appearance of circular folds in “coin stack” (small intestine obstruction); and three or more hydro-aerial levels at different heights shown in radiography in the antero-posterior view with the patient in orthothastic position; and absence of gas in the colon and rectum (indicate a complete obstruction). The study of intestinal transit with contrast is usually indicated for semi-occlusion or higher recurrent sets. Computed tomography of the abdomen should be used to clarify doubtful cases and diagnose complications.^{2,11,14}

Severe cases with radiological features of complete intestinal obstruction, signs of peritonitis, loop distress, or strangulation should be urgently undergone a operative treatment first, after clinical and hemodynamic stabilization. The benefit of operative treatment should be balanced with the risks associated with surgery, patient's co-morbidities, and presence or absence of strangulation. In cases of partial intestinal obstruction, it is possible opting for non-operative treatment first, while wait the clinical evolution, which should be carefully monitored. However, if the patient does not improve after 48 h, laparotomy should be expedite (Table 4).^{12,15}

The operative treatment of patients with stenosis due to CD, resection of the compromised segment is usually necessary, although recurrence of the disease at the site of resection is common. Wide lumen stapled ileocolic side-to-side [functional end-to-end] anastomosis is the preferred technique. However, patients with multiple stenosis or undergoing extensive resections are at risk of developing short bowel syndrome. In such cases, a therapeutic option is performing stenosis plastic, if bowel disease is up to 68 cm of extension. Nevertheless, the option is inappropriate for patients with acute inflammation of the intestinal bowel. Other alternative treatments are endoscopic procedures such as stenting and balloon dilation, especially if the disease involves the colon. In cases of stenosis due to URC with associated risk of neoplasm, bowel resection

should be performed. In addition, remind that appendectomy of a normal looking appendix, in patients with terminal ileitis has a high risk of intra-abdominal septic complications and fistulas.^{3,12}

Intestinal perforation and peritonitis

This complication is observed in both CD and URC. In CD frequently develops in the terminal ileum; and in URC, it is usually associated with TM.^{1,16} In cases of intestinal perforation blocked by omentum and/or neighboring structures (flegmon and abscess), the first option is image-guided drainage (ultrasound or computed tomography) followed by operative or non-operative treatment. Thus, it is possible to operate the patient electively, decreasing the morbidity and mortality rates.^{11,17}

The presence of diffuse peritonitis implies in immediate operative treatment with cautiously evaluation of the diseased segment. So, the operative technique varies according to the site and cause of the perforation: small intestine – should opt for resection of the smallest possible intestinal loop segment, since the probability of CD recurrence is high – at the same economic approach should be done for colonic perforation in CD cases. If the colon is the etiology of perforation – when caused by a complication of URC, total colectomy associated with ileostomy should be implemented, and the intestinal transit should be reconstructed later.^{11,17,18}

Intra-abdominal abscesses

Intra-abdominal abscesses are most often observed in CD. They may be an initial presentation of the disease or develop at any time of its evolution. Patients may present with oligosymptomatic clinical complaints to severe sepsis. Typically, the clinical set is characterized by fever, sometimes with chills, spontaneous localized abdominal pain rigidity, rebound tenderness sometimes similar to acute appendicitis. The laboratory shows leukocytosis with left shift and increased PCR.^{5,19}

Suspected cases require hospitalization and early empirical antibiotic therapy (ciprofloxacin and metronidazole are a good first-line option, and cephalosporin's may be used in combination with metronidazole and amoxicillin. The imaging investigation by computed tomography or magnetic resonance imaging is option of first choice. Once the abscess is identified, the next step is to choose the best drainage alternative. Available procedures include tomography-guided percutaneous drainage, with catheter maintenance for washing or operative treatment of the viscera. Puncture and analysis of the fluid are important step for identifying the microorganism and guiding therapy.^{5,11,18,19}

Percutaneous drainage should be a temporary approach, because most cases will need operative treatment for removing the compromised intestinal segment responsible for the abscess.^{5,19,20}

Conclusion

Most emergencies related to IBD should be treated non-operatively firstly, prioritizing patient hemodynamic state. In

selected cases of life-threatening complications, refractory to clinical resuscitative measures, persistent hemodynamic instability, more aggressive approaches are mandatory, including emergent operative treatment. As general rule, in case of CD, operative treatment should be postponed as much as possible and the resection as small as possible, i.e., restrict to the area of complication. In the case of URC, in turn, if the hemodynamic status of the patient allows, proctocolectomy should be expedited with curative intention; otherwise, resection and diversion should be implanted

Conflicts of interest

The authors declare no conflicts of interest.

REFERENCES

- Ballou S, Hirsch W, Singh P, Rangan V, Nee J, Iturrino J, et al. Emergency department utilisation for inflammatory bowel disease in the United States from 2006 to 2014. *Aliment Pharmacol Ther.* 2018;47:913-21.
- Yarur AJ, Mandalia AB, Dauer RM, Czul F, Deshpande AR, Kerman DH, et al. Predictive factors for clinically actionable computed tomography findings in inflammatory bowel disease patients seen in the emergency department with acute gastrointestinal symptoms. *J Crohns Colitis.* 2014;8:504-12.
- Bemelman WA, Warusavitarn J, Sampietro GM, Serclova Z, Zmora O, Luglio G, et al. ECCO-ESCP Consensus on Surgery for Crohn's Disease. *J Crohns Colitis.* 2018;12:1-16.
- He B, Yang J, Xiao J, Gu J, Chen F, Wang L, et al. Diagnosis of lower gastrointestinal bleeding by multi-slice CT angiography: a meta-analysis. *Eur J Radiol.* 2017;93:40-5.
- De Groof EJ, Carbonnel F, Buskens CJ, Bemelman WA. Abdominal abscess in Crohn's disease: multidisciplinary management. *Dig Dis.* 2014;32:103-9.
- Frazer C, Hussey L, Bemker M. Gastrointestinal motility problems in critically ill patients. *Crit Care Nurs Clin North Am.* 2018;30:109-21.
- Gralnek IM, Neeman Z, Strate LL. Acute lower gastrointestinal bleeding. *N Engl J Med.* 2017;376:1054-63.
- Woodhouse E. Toxic megacolon: a review for emergency department clinicians. *J Emerg Nurs.* 2016;42:481-6.
- Jalan KN, Sircus W, Card WI, Falconer CW, Bruce CB, Crean GP, et al. An experience with ulcerative colitis: toxic dilation in 55 cases. *Gastroenterology.* 1969;57:68-82.
- Kim KJ, Han BJ, Yang SK, Na SY, Park SK, Boo SJ, et al. Risk factors and outcome of acute severe lower gastrointestinal bleeding in Crohn's disease. *Dig Liver Dis.* 2012;44:723-8.
- Burg MD, Riccoboni ST, Nusbaum J, Gupta N. Management of inflammatory bowel disease flares in the emergency department [digest]. *Emerg Med Pract.* 2017;19:S1-2.
- Burg MD, Riccoboni ST. Management of inflammatory bowel disease flares in the emergency department. *Emerg Med Pract.* 2017;19:1-20.
- Speir EJ, Ermentrout RM, Martin JG. Management of acute lower gastrointestinal bleeding. *Tech Vasc Interv Radiol.* 2017;20:258-62.
- Guo Z, Cao L, Gong J, Li Y, Gu L, Zhu W, et al. Effect of a clinical pathway in patients with Crohn's disease complicated with intestinal obstruction. *Zhonghua Wei Chang Wai Ke Za Zhi.* 2017;20:53-7.
- Hajibandeh S, Hajibandeh S, Panda N, Khan RMA, Bandyopadhyay SK, Dalmia S, et al. Operative versus non-operative management of adhesive small bowel obstruction: a systematic review and meta-analysis. *Int J Surg.* 2017;45:58-66.
- Pant C, Deshpande A, Fraga-Lovejoy C. Emergency department visits related to inflammatory bowel disease: results from nationwide emergency department sample. *J Pediatr Gastroenterol Nutr.* 2015;61:282-4.
- Van Ruler O, Boermeester MA. Surgical treatment of secondary peritonitis: a continuing problem. German version. *Chirurg.* 2016;87:13-9.
- Maseda E, Gimenez MJ, Gilsanz F, Aguilar L. Basis for selecting optimum antibiotic regimens for secondary peritonitis. *Expert Rev Anti Infect Ther.* 2016;14:109-24.
- Clancy C, Boland T, Deasy J, McNamara D, Burke JP. A meta-analysis of percutaneous drainage versus surgery as the initial treatment of Crohn's disease-related intra-abdominal abscess. *J Crohns Colitis.* 2016;10:202-8.
- Roberts BW. CT-guided Intra-abdominal abscess drainage. *Radiol Technol.* 2015;87, 187CT-203CT; quiz 204CT-7.