



## Original Article

# Added value of dynamic magnetic resonance images in pelvic floor dysfunction



Guillermo O. Rosato , Carina Chwat \*, Gustavo Lemme , Flavia Alexandre ,  
Diego Valli , Marcelo Terres , Juan Pablo Perotti 

Hospital Universitario Austral, Colorrectal Unit, General Surgery Department, Buenos Aires, Argentina

### ARTICLE INFO

#### Article history:

Received 24 November 2019

Accepted 8 January 2020

Available online 23 January 2020

#### Keywords:

Pelvic floor dysfunction

Dynamic MRI

Outlet obstruction

### ABSTRACT

**Purpose:** Pelvic floor dysfunction has a high prevalence in the adult population. The Dynamic and Multiplanar Evaluation of the Pelvic Floor (DMRIPP) represents an ideal tool for multidisciplinary management. The purpose of this analysis is to evaluate the added value of the Dynamic and Multiplanar Evaluation of the Pelvic Floor in patients with suspected pelvic floor disorders.

**Methods:** Retrospective analysis of a consecutive series of patients who underwent a DMRIPP due to suspected pelvic floor disorders between April 2005 and July 2019.

**Results:** 359 patients were included. The average number of diagnoses achieved by physical examination was 1.2 vs. 2.5 by the Dynamic and Multiplanar Evaluation of the Pelvic Floor ( $p < 0.001$ ). Physical examination found a single pathology in 80.8 % of cases. Anterior rectocele (AR) was the most frequent isolated diagnosis on physical examination (68 %). On the Dynamic and Multiplanar Evaluation of the Pelvic Floor, anterior rectocele was diagnosed as an isolated condition in 10.9 %. In 231 cases, anterior rectocele was associated with up to 5 other pelvic floor disorders. The number of individuals with associated pathologies of the posterior and anterior compartments tripled. It modified physical examination findings in 17 % of individuals and, in 63.5 %, allowed the identification of additional pelvic floor pathologies that were missed by physical examination. The Dynamic and Multiplanar Evaluation of the Pelvic Floor had greater added value in patients with anterior rectocele (59.6 % vs. 20.9 %;  $p < 0.001$ ). Female gender was also associated with a greater diagnostic yield ( $p < 0.001$ ).

**Conclusion:** The Dynamic and Multiplanar Evaluation of the Pelvic Floor allows the detection of multi-compartment defects that could otherwise go undetected, or even alter the initial clinical diagnosis, representing an ideal tool for multidisciplinary approach of pelvic floor dislocations, allowing a comprehensive therapeutic planning.

© 2020 Sociedade Brasileira de Coloproctologia. Published by Elsevier Editora Ltda. This is an open access article under the CC BY-NC-ND license (<http://creativecommons.org/licenses/by-nc-nd/4.0/>).

\* Corresponding author.

E-mail: [carinachwat@gmail.com](mailto:carinachwat@gmail.com) (C. Chwat).

<https://doi.org/10.1016/j.jcol.2020.01.001>

2237-9363/© 2020 Sociedade Brasileira de Coloproctologia. Published by Elsevier Editora Ltda. This is an open access article under the CC BY-NC-ND license (<http://creativecommons.org/licenses/by-nc-nd/4.0/>).

## Valor agregado das imagens de ressonância magnética dinâmica na disfunção do assoalho pélvico

### R E S U M O

#### Palavras-chave:

Disfunção do assoalho pélvico

RM dinâmica

Obstrução da saída

**Objetivo:** A disfunção do assoalho pélvico tem alta prevalência na população adulta. A avaliação dinâmica e multiplanar do assoalho pélvico (DMRIPF) representa uma ferramenta ideal para o gerenciamento multidisciplinar. O objetivo desta análise é avaliar o valor agregado da avaliação dinâmica e multiplanar do assoalho pélvico em pacientes com suspeita de distúrbios do assoalho pélvico.

**Métodos:** Análise retrospectiva de uma série consecutiva de pacientes submetidos à avaliação dinâmica e multiplanar do assoalho pélvico por suspeita de distúrbios do assoalho pélvico entre Abril de 2005 e Julho de 2019.

**Resultados:** 359 pacientes foram incluídos. O número médio de diagnósticos alcançados pelo exame físico foi de 1,2 vs. 2,5 pela avaliação dinâmica e multiplanar do assoalho pélvico  $p < 0,001$ . O exame físico encontrou uma única patologia em 80,8 % dos casos. A retocele anterior (RA) foi o diagnóstico isolado mais frequente no exame físico (68 %). Na avaliação dinâmica e multiplanar do assoalho pélvico, a retocele anterior foi diagnosticada como uma condição isolada em 10,9 %. Em 231 casos, a retocele anterior foi associada a até 5 outros distúrbios do assoalho pélvico. O número de indivíduos com patologias associadas dos compartimentos posterior e anterior triplicou. Modificou os achados do exame físico em 17 % dos indivíduos e em 63,5 %; permitiu a identificação de outras patologias do assoalho pélvico que foram esquecidas pelo exame físico. A avaliação dinâmica e multiplanar do assoalho pélvico teve maior valor agregado em pacientes com retocele anterior (59,6 % vs. 20,9 %;  $p < 0,001$ ). O sexo feminino também foi associado a um maior rendimento diagnóstico  $p < 0,001$ .

**Conclusão:** A avaliação dinâmica e multiplanar do assoalho pélvico permite a detecção de defeitos multicompartimentários que, de outra forma, poderiam não ser detectados, ou mesmo alterar o diagnóstico clínico inicial, representando uma ferramenta ideal para a abordagem multidisciplinar das luxações do assoalho pélvico, permitindo um planejamento terapêutico abrangente.

© 2020 Sociedade Brasileira de Coloproctologia. Publicado por Elsevier Editora Ltda. Este é um artigo Open Access sob uma licença CC BY-NC-ND (<http://creativecommons.org/licenses/by-nc-nd/4.0/>).

## Background

Pelvic floor dysfunction has a high prevalence in the adult population due to the progressive loss of pelvic floor support, and is seen more frequently in women.<sup>1-3</sup>

Pelvic floor descent is caused by the loss of muscle tone and is frequently associated with multiple simultaneous alterations, such as rectal prolapse, anterior and/or posterior rectocele, rectoanal intussusception, enterocele, cystocele, hysterocele and colpocele.<sup>4,5</sup>

Dynamic Magnetic Resonance Imaging of the Pelvic Floor (DMRIPF) is a complementary diagnostic tool that allows simultaneous evaluation of all pelvic floor compartments (anterior, middle and posterior) in a single study, without exposing the patient to radiation.<sup>6-8</sup> It also offers valuable information not always evident in the physical examination, allowing to define a more effective treatment strategy.<sup>9</sup>

The lack of integrated information for the different medical specialties involved in the management of pelvic floor pathologies, leads to fragmentation in the treatment of pelvic floor disorders.<sup>10</sup> The dynamic and multiplanar evaluation of

the pelvic floor represents an ideal tool for multidisciplinary management.<sup>11</sup>

The purpose of this analysis is to evaluate the added value of the DMRIPF in patients with suspected pelvic floor disorders.

## Materials and methods

A retrospective analysis of a consecutive series of patients who underwent a DMRIPF in our institution due to suspected pelvic floor disorders between April 2005 and July 2019 was undertaken.

This study was exempt from the approval of the Institutional Review Board based on local regulations indicating that this research qualifies as a minimum risk investigation in which the data is purely observational and presented anonymously (Law 11.044, Buenos Aires, Argentina).

All patients were included for analysis, except those who had a post-surgical follow-up with DMRIPF. Parameters recorded included gender, age, indication for DMRIPF, main physical findings on referral data and DMRIPF outcomes

### DMRIPF procedure

With the patient in the left lateral decubitus position, 120–180 mL of ultrasound gel was introduced into the rectum. This provides a good T2 signal and allows the evaluation of the activity of its walls during rest, voluntary contraction and strain.

The patients were then rotated to the supine position, with the legs slightly bent and raised on the imaging table. Magnetic resonance Images were obtained with a high-speed 1.5 T GE® (General Electric Company, Milwaukee, WI, USA). A T2 single shot fast spin-echo with sagittal section (SSFSE) was performed in the middle pelvis, without fat suppression.

Axial images were obtained at rest and during strain to evaluate the pelvic hiatus and symmetry of the puborectalis muscle. Mid-sagittal images with cine effect were captured at rest, pelvic floor contraction, rest, and strain sequence, in order to assess the movement of organs and pelvic muscles.

One or several static images during rest, voluntary contraction of the pelvic floor and straining were selected to draw the standardized lines for the measurement of the anorectal angle and the descent of the pelvic floor, as well as assessment of any pelvic floor pathologies.

A normal pelvic floor at rest should show the upper portion of the urethra and vagina, bladder, uterus, sigmoid colon and small intestine above the H line. In addition, pelvic floor descent should not exceed 2 cm during maximal straining.<sup>12,13</sup>

### Statistical analysis

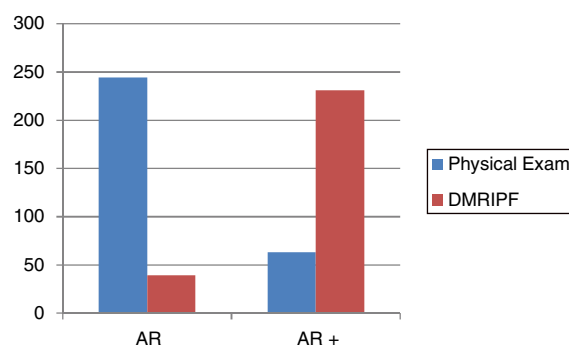
Statistical analysis was performed with STATA 14.2.<sup>14</sup> Continuous variables were described with their mean, range and standard deviation, and the categorical ones with percentages. The t-test was used for the comparison of continuous variables and Chi<sup>2</sup> for categorical variables. A p-value < 0.05 was considered statistically significant. Wilcoxon Rank Sign Test for paired data was used to compare results for physical examination and DMRIPF.

## Results

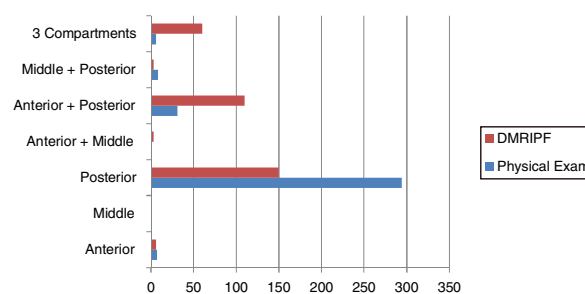
Inclusion criteria were met by 359 individuals, 95 % were women, with a mean age of 54.2 years (range, 18–94; SD = 12.5 years). DMRIPF was indicated in 342 individuals (95.3 %) due to outlet obstruction syndrome. The average number of diagnoses achieved by physical examination was 1.2 vs. 2.5 by DMRIPF ( $p < 0.001$ ).

Physical examination found a single pathology in 80.8 % of cases ( $n = 290$ ). Anterior Rectocele (AR) was the most frequent isolated diagnosis on physical examination ( $n = 244$ ; 68 %) and was associated with other pelvic floor pathologies in 63 patients (17.6 %). Cystocele was the most frequent diagnosis associated with AR, appearing together in 36 patients, representing 57 % of the individuals in this group.

The relationship between the number of patients with isolated AR and AR associated with other pathologies was inverted in the case of the DMRIPF findings, where the number of patients with isolated AR was significantly lower than those with AR associated with other pathologies of the pelvic floor



**Fig. 1 – Differences between physical examination and DMRIPF in the detection of isolated Anterior Rectocele (AR) and anterior rectocele associated with other pelvic floor dysfunctions (AR+).**



**Fig. 2 – Pathologies detected during physical examination and DMRIPF in the different compartments.**

(Fig. 1). On DMRIPF, AR was diagnosed as an isolated condition in 39 patients (10.9 %). In 231 cases (64.4 %), AR was associated with up to 5 other pelvic floor disorders. Cystocele and AR was the most frequent happening 43.5 % ( $n = 156$ ).

According to physical examination findings, 81.9 % of patients were referred due to isolated posterior compartment pathologies. When performing DMRIPF, this was appreciated in only 41.8 %. Likewise, the number of individuals with associated pathologies of the posterior and anterior compartments tripled. The most striking difference between the diagnoses of physical examination and DMRIPF was in the number of patients with simultaneous compromise of all pelvic compartments (Fig. 2).

DMRIPF confirmed the physical examination findings in 70 patients (19.5 %) and modified the diagnosis in 61 (17 %). In 228 individuals (63.5 %) allowed the identification of additional pelvic floor pathologies that were missed by physical examination.

DMRIPF had greater added value compared to physical examination in patients with anterior rectocele (59.6 % vs. 20.9 %;  $p < 0.001$ ). Female gender was also associated with a greater diagnostic yield during DMRIPF ( $p < 0.001$ ). Nevertheless, this gender-related difference could be due to the fact that most of the individuals in this cohort were women.

## Discussion

Pelvic floor dysfunctions are complex, because anatomical and functional disorders of more than one compartment fre-

quently coexist. The presence of the simultaneous dislocation of several viscera, referred to by Pescatori<sup>15</sup> as the “Iceberg syndrome”, requires a multidisciplinary approach, with the intervention of more than one specialist, to ensure an adequate diagnosis and a successful comprehensive therapeutic strategy. These situations may lead to insufficient therapeutic recommendations, unsuccessful repairs and, consequently, to the persistence or recurrence of some type of visceral prolapse and the associated sign-symptomatology.

The findings of this study illustrate the benefit of performing a DMRIPF as part of a multidisciplinary approach to the diagnosis and subsequent treatment of pelvic floor dysfunction. In a study by Kaufman et al.,<sup>16</sup> pelvic MRI findings modified the initial operative plan in 41 %. Another study by Hetzer et al.,<sup>17</sup> surgical approach was influenced in 67 %. Our findings suggest that DMRIPF is able to identify pelvic floor pathology in more than twice than physical examination alone. As noted by Attemberger et al. in 2015,<sup>18</sup> DMRIPF evaluates the interaction between the three pelvic floor compartments and allows diagnosis of subclinical anatomical alterations that may influence changes to the therapeutic strategy. In our study, the displacement of abdominopelvic structures not perceived on physical examination, were diagnosed in 63.5 % of the patients.

In 2004, Cortes et al.<sup>19</sup> evaluated the role of the DMRIPF as a diagnostic tool in the evaluation of vaginal apex prolapse in women with prior hysterectomy. They concluded that there is poor correlation between clinical and DMRIPF when assessing anterior compartment pathologies, similar to that seen in our series. On the contrary, Broekhuis et al.<sup>20</sup> concluded that, due to high agreement between clinical assessment and DMRIPF in the anterior and central compartments, and lower agreement between method in the posterior compartment, DMRIPF would only have advantages over clinical staging in the assessment of posterior compartment prolapses, due to the difficulty for the clinical identification of enterocele and recto-anal intussusception on clinical examination.

In 1999, Kelvin et al.<sup>21</sup> published the correlation between dynamic cystoproctography and physical examination findings. The authors suggested that most radiographically detected rectoceles and cystoceles are found on physical examination, whereas the correlation for enterocele and sigmoidocele is poor.

In our series we detected important differences between diagnostic methods in findings relative to posterior compartment dislocations. Additionally, DMRIPF allowed simultaneous visualization of the anatomical components of the three pelvic compartments and functional inter-compartmental interactions during rest, squeeze and straining, with no radiation exposure and avoidance of bladder contrast.

To our knowledge, this is the largest diagnostic case series in the evaluation of the pelvic floor using DMRIPF.

However, this study has its limitations since it only includes patients from our institution and those referred to it for this diagnostic study, and may not truly represent all individuals with pelvic floor dysfunction. Additionally, the objective of this study was to identify and compare the type and number of pelvic floor dislocations diagnosed by physical examination and DMRIPF. We did not take into account symptom data or investigate if the added value of DMRIPF had any impact

on treatment strategy, surgical results or patient’s satisfaction or quality of life. Finally, economic considerations were not assessed, and comparison with other diagnostic tools was not made. Further prospective multicentre studies are required to assess the effect of DMRIPF on patient outcomes and their economic impact.

---

## Conclusion

DMRIPF allows more accurate simultaneous viewing of the anatomical components of the pelvic floor and inter-compartmental interactions, adding information to physical examination, but not replacing it.

DMRIPF’s value lies in the complete and dynamic evaluation of pelvic organs and musculature, not always accessible to the physical examination. It allows the detection of multi-compartment defects that could otherwise go undetected, or even alter the initial clinical diagnosis, representing an ideal tool for multidisciplinary approach of pelvic floor dislocations, allowing a comprehensive therapeutic planning.

---

## Ethical approval

This article does not contain any studies with animals performed by any of the authors. This study was exempt from the approval of the Institutional Review Board based on local regulations indicating that this research qualifies as a minimum risk investigation in which the data is purely observational and presented anonymously (Law 11.044, Buenos Aires, Argentina).

---

## Data availability

The datasets analysed during the current study are available from the corresponding author on reasonable request.

---

## Financial support

None.

---

## Conflicts of interest

The authors declare no conflicts of interest.

---

## REFERENCES

1. Yang A, Mostwin JL, Rosenheim NB, Zerhouni EA. Pelvic floor descent in women: dynamic evaluation with fast MR Imaging and cinematic display. *Radiology*. 1991;179:25–33.
2. MacLennan AH, Taylor AW, Wilson DH, Wilson D. The prevalence of pelvic floor disorders and their relationship to gender, age, parity and mode of delivery. *BJOG*. 2000;107:1460–70.
3. Sung VW, Hampton BS. Epidemiology of pelvic floor dysfunction. *Obstet Gynecol Clin North Am*. 2009;36:421–43.

4. Maglinte DD, Kelvin FM, Fitzgerald K, Hale DS, Benson JT. Association of compartment defects in pelvic floor dysfunction. *Am J Roentgenol.* 1999;172:439–44.
5. Kelvin FM, Maglinte DD. Dynamic cystoproctography of female pelvic floor defects and their interrelationships. *Am J Roentgenol.* 1997;169:769–74.
6. Gousse AE, Barbaric ZL, Safir MH, et al. Dynamic half Fourier acquisition single shot turbo spin-echo magnetic resonance imaging for evaluating the female pelvis. *J Urol.* 2000;164:1606–13.
7. Comiter CV, Vasavada SP, Barbaric ZL, Madjar S, Marumoto AK, Raz S. Grading pelvic floor prolapse and pelvic floor relaxation using dynamic magnetic resonance imaging. *Urology.* 1999;54:454–7.
8. Lienemann A, Anthuber C, Baron A, Reiser M. Diagnosing enteroceles using dynamic magnetic resonance imaging. *Dis Colon Rectum.* 2000;43:205–13.
9. Rosato G, et al. Surgical Treatment of rectocele: transperineal repair. In: Fleshman J, Wexner S, editors. *Colon and Rectal Surgery: Anorectal Operations.* 2nd ed. Lippincott Williams & Wilkins; 2017. Chapter 30.
10. Hubert J, Bergin D. Imaging the female pelvis: when should MRI be considered? *Appl Radiol.* 2008;37:9–24.
11. Rosato G, Perotti JP, Terres M, Lemme G, Iudica F, Altuna S, et al. El impacto de la resonancia magnetica dinamica en el diagnóstico de las disfunciones del piso pélvico. *Rev Argent Coloproctología.* 2012;23:15–24.
12. Darwish HS, Zaytoun HA, Kamel HA, Qamar SR. Assessment of pelvic floor dysfunctions using dynamic magnetic resonance imaging. *Egypt J Radiol Nucl Med.* 2014;45:225–9.
13. Barbaric ZL, Marumoto AK, Raz S. Magnetic resonance imaging of the perineum and pelvic floor. *Top Magn Reson Imaging.* 2001;12:83–92.
14. StataCorp. *Stata Statistical Software: Release 14.* College Station, TX: StataCorp LP; 2015.
15. Pescatori M, Quondamcarlo C. A new grading of rectal internal mucosal prolapse and its correlation with diagnosis and treatment. *Int J Colorectal Dis.* 1999;14:245–9.
16. Kaufman HS, Buller JL, Thompson JR, Pannu HK, DeMeester SL, Genadry RR, et al. Dynamic pelvic magnetic resonance imaging and cystocolpoproctography alter surgical management of pelvic floor disorders. *Dis Colon Rectum.* 2001;44:1575–83.
17. Hetzer FH, Andreisek G, Tsagari C, Sahrbacher U, Weishaupt D. MR defecography in patients with fecal incontinence: imaging findings and their effect on surgical management. *Radiology.* 2006;240:449–57.
18. Attenberger UI, Morelli JN, Budjan J, Herold A, Kienle P, Kleine W, et al. The value of dynamic magnetic resonance imaging in interdisciplinary treatment of pelvic floor dysfunction. *Abdom Imaging.* 2015;40:2242–7.
19. Cortes E, Reid WM, Singh K, Berger L. Clinical examination and dynamic magnetic resonance imaging in vaginal vault prolapse. *Obstet Gynecol.* 2004;103:41–6.
20. Broekhuis SR, Fütterer JJ, Barentsz JO, Vierhout ME, Kluijvers KB. A systematic review of clinical studies on dynamic magnetic resonance imaging of pelvic organ prolapse: the use of reference lines and anatomical landmarks. *Int Urogynecol J.* 2009;20:721–9.
21. Kelvin FM, Hale DS, Maglinte DD, Patten BJ, Benson JT. Female pelvic organ prolapse: diagnostic contribution of dynamic cystoproctography and comparison with physical examination. *AJR Am J Roentgenol.* 1999;173:31–7.