


Anterior Glenohumeral Instability: Systematic Review of Outcomes Assessment Used in Brazil^{*}

Instabilidade glenoumeral anterior: Revisão sistemática dos desfechos usados no Brasil

Jorge Henrique Assunção¹  Eduardo Angeli Malavolta¹ Fernando José de Souza¹
Mauro Emilio Conforto Gracitelli¹ Arnaldo Amado Ferreira Neto¹

¹ Institute of Orthopedics and Traumatology, Hospital das Clínicas da Faculdade de Medicina da Universidade de São Paulo (HCFMUSP), São Paulo, SP, Brazil

Address for correspondence Jorge Henrique Assunção, PhD, Instituto de Ortopedia e Traumatologia, Hospital das Clínicas da Faculdade de Medicina da Universidade de São Paulo (HCFMUSP), São Paulo, SP 05403-000, Brazil (e-mail: drjorgeassuncao@gmail.com).

Rev Bras Ortop 2019;54:483–490.

Abstract

A review involving the six major international orthopedic journals has been published recently. It described the tools used for the evaluation of outcomes in the surgical treatment of recurrent anterior dislocation of the shoulder. There are no studies that exhibit the main outcome tools for this disease in Brazil. The authors evaluated the outcomes of clinical studies involving anterior glenohumeral instability that were published in the last decade in the two leading Brazilian orthopedic journals, *Revista Brasileira de Ortopedia* and *Acta Ortopédica Brasileira*. A review of the literature was performed, including all clinical papers published between 2007 and 2016 describing at least one outcome measure before and after surgical intervention. The outcomes were range of motion, muscle strength, physical examination testing, patient satisfaction, return to sports, imaging, complications, and functional outcomes scores. Twelve studies evaluating the clinical outcomes of surgical treatment for anterior shoulder instability were published. Ten studies (83%) were case series (level of evidence IV), 1 (8%) was a case-control study (III), and 1 was a retrospective cohort (III). On average, the number of outcomes assessed was 3.7 ± 1.7 . The Rowe score was used in 9 studies (75%), and 7 (58%) papers used the University of California Los Angeles (UCLA) scale. Ten studies (83%) reported complications related to surgical treatment. The complication most frequently reported was recurrent instability, found in 9 studies (75%). The national studies have preferentially used scales considered to be of low reliability, responsiveness, and internal consistency.

Keywords

- ▶ shoulder
- ▶ evaluation of results of therapeutic interventions
- ▶ shoulder dislocation/surgery

^{*} Work developed by the Shoulder and Elbow Group, Instituto de Ortopedia e Traumatologia, Hospital das Clínicas, Faculdade de Medicina, Universidade de São Paulo, São Paulo, SP, Brazil. Originally Published by Elsevier Editora Ltda.

Resumo

Uma revisão que envolveu as seis principais revistas ortopédicas internacionais foi publicada recentemente. A revisão descreveu as ferramentas usadas para a avaliação dos desfechos no tratamento cirúrgico da luxação anterior recidivante do ombro. Não existe um levantamento que mostre as principais formas de avaliação para essa doença no Brasil. Os autores avaliaram os desfechos usados nos estudos clínicos que envolveram a instabilidade glenoumeral anterior e que foram publicados na última década nos dois principais periódicos ortopédicos brasileiros, Revista Brasileira de Ortopedia e Acta Ortopédica Brasileira. Foi feita uma revisão da literatura na qual foram incluídos todos os artigos clínicos publicados entre 2007 e 2016 que descreveram ao menos uma medida de desfecho antes e após intervenção cirúrgica. Os desfechos avaliados foram amplitude de movimento, força muscular, testes de exame físico, satisfação, retorno ao esporte, exames de imagem, complicações, e escalas clínicas. Foram publicados 12 estudos que avaliaram os resultados clínicos do tratamento cirúrgico da instabilidade anterior do ombro. Dez estudos (83%) eram séries de caso (nível de evidência IV), 1 (8%) caso-controle (III), e 1 coorte retrospectiva (III). A média de desfechos avaliados por estudo foi de $3,7 \pm 1,7$. A escala Rowe foi usada em 9 estudos (75%), e 7 publicações (58%) usaram a escala da *University of California Los Angeles* (UCLA). Dez estudos (83%) relataram as complicações relacionadas ao tratamento cirúrgico. A complicação mais frequentemente relatada foi a recidiva da luxação glenoumeral, encontrada em 9 estudos (75%). Os estudos nacionais usaram preferencialmente escalas consideradas de baixa confiabilidade, responsividade, e consistência interna.

Palavras-chave

- ▶ ombro
- ▶ avaliação de resultado de intervenções terapêuticas
- ▶ luxação do ombro/cirurgia

Introduction

The shoulder is the joint most commonly dislocated,¹ and anterior instability is the most frequently encountered condition. It has a higher incidence in young men, and its treatment is preferably surgical.²⁻⁴ We have found numerous studies in the literature evaluating the clinical results of the surgical treatment of anterior shoulder instability. Standardized clinical assessment is essential for determining the success of a treatment and also for comparing the results of different studies, being critical for clinical research.^{5,6} Methods for the evaluation of orthopedic treatment outcomes have been modified in recent years.^{7,8} Measurement was initially based on physical examination, assessing joint mobility and muscle strength. However, questionnaires or clinical scores were developed to improve the evaluation of outcomes.^{9,10} However, measurement tools are widely variable.¹¹ More than 40 scores assessing shoulder function are described,¹² and there is no consensus on the best method for the evaluation of outcomes in patients undergoing surgical treatment for glenohumeral instability.¹³

Lukenchuck et al¹⁴ recently published a review involving the six major international orthopedic journals and described the tools used to assess the outcomes of the surgical treatment of recurrent anterior shoulder dislocation. There is no survey showing the main clinical evaluation tools for this condition in Brazil. A similar survey was performed for rotator cuff tears, and it showed that scales deemed reliable, with high internal consistency and good responsiveness,

were rarely used in our country.¹⁵ We also point out that most assessment instruments were developed and evaluated in the English language.¹² The use of these instruments in Brazil demands translation, cultural adaptation, and tests evaluating their measurement properties, such as internal consistency, reproducibility, validity, and responsiveness.⁷ This study aims to evaluate the outcomes used in clinical studies about the surgical treatment of anterior glenohumeral instability published in the last decade in the two main Brazilian orthopedic journals.

Methods

Design

A literature review was performed in the two main Brazilian orthopedic journals, namely *Revista Brasileira de Ortopedia* (RBO) and *Acta Ortopédica Brasileira*. The period covered was one decade (January 2007–December 2016). This study was approved by the local Ethics Committee under the number 1258.

Search Strategy

Initially, all paper titles were read by one of the authors (J. H. A.) from the journal index. In cases of doubt while reading the title, the abstract was evaluated. Thus, all papers that did not involve the shoulder joint and the treatment of glenohumeral instability were excluded. Then, the abstracts were read by three authors (J. H. A., E. A. M. and F. J. S.) and, if necessary, the full text was analyzed to determine if the paper met the selection criteria. In case of disagreement in

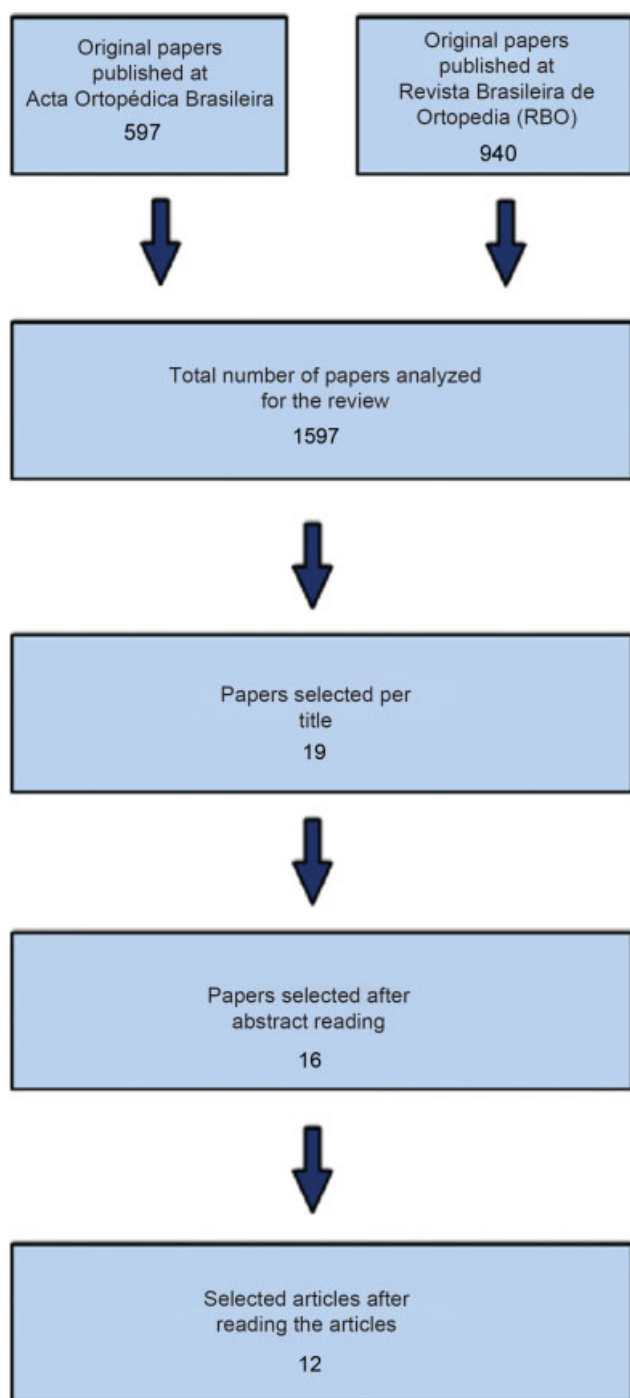


Fig. 1 Research algorithm; 12 papers were selected based on inclusion and exclusion criteria.

the selection of a given paper among the three authors, its inclusion or not was consensually defined (► **Fig. 1**).

Selection Criteria

All original clinical papers (randomized controlled trial, cohort, case-control, and case series) describing at least one outcome measure after the surgical treatment of anterior or glenohumeral instability were included. Case reports, surgical technique descriptions, papers on the accuracy of diagnostic methods, anatomical studies, papers involving

animal or cadaveric studies, basic scientific texts or reviews were not included. Papers including patients with multidirectional or posterior glenohumeral dislocation or those evaluating the outcomes of the clinical treatment for anterior glenohumeral instability were excluded.

Data of the Included Studies

Data regarding the study title, year and volume of publication, number of patients, mean follow-up, minimum follow-up, regular follow-up and level of evidence were tabulated. The following information on surgical treatment was collected:

- A) Open or arthroscopic surgery;
- B) Capsulolabral repair;
- C) Glenoid bone defect filling with bone grafts;
- D) Which bone graft was used, if any;
- E) Treatment of Hill-Sachs injury and technique employed.

Outcomes

The following clinical outcomes were evaluated:

- A) Range of motion

The plane in which the range of motion was assessed, that is, frontal flexion, elevation, abduction, lateral rotation (with the arm at the side of the body or abducted), and medial rotation (with the hand towards the back or with arm abduction) was determined. The measurement in any plan was tabulated, and evaluation in all of them was not required. Data were considered described only if presented quantitatively in the results section. Patient positioning (supine, sitting or standing) and the use of a goniometer were also evaluated.

- B) Muscle strength

The plane in which the strength was evaluated, that is, frontal flexion, elevation, abduction, lateral rotation (with the arm at the side of the body or abducted), and medial rotation (with the hand towards the back or with arm abduction) was determined. The measurement in any plan was tabulated, and evaluation in all of them was not required. Data were considered described only if presented quantitatively in the results section. Patient positioning (supine, sitting or in orthostatic position) and the use of a dynamometer were also evaluated. Manual evaluation data (grading from 0–5) were also computed. Data referring to a clinical score subdomain were reported if presented individually and if the extraction of data related to muscle strength assessment was feasible.

- C) Physical Examination Tests

The outcome of the physical examination was evaluated if it was performed and reported independently of scores and assessment questionnaires. This included shoulder tests specific for anterior instability, such as the apprehension or replacement test. Muscle strength and range of motion assessments were not recorded in this category, but rather in those aforementioned.

- D) Satisfaction

Any data regarding patient satisfaction was surveyed, including questions regarding satisfaction with the treatment or whether the patient would recommend the

procedure to a third party or have surgery again. Data referring to a clinical score subdomain were also reported if presented individually and if the extraction of data related to patient satisfaction was feasible.

E) Return to sport or activity level before injury

Any data regarding return to sport activities or to the activity level prior to injury was researched, including objective questions about this topic or the use of scores measuring such outcome.

F) Scores and evaluation questionnaires

The functional scores and evaluation questionnaires used by the authors were evaluated. Studies using the visual analogue scale (VAS) for pain or function were also reported.

G) Complications

All complications related to the surgical treatment, such as glenohumeral instability recurrence after surgical treatment (apprehension, shoulder subluxation or dislocation), infection, stiffness, neurovascular injury, bruising, osteoarthritis, pseudarthrosis, and implant-related complications, were evaluated.

H) Imaging

The imaging methods used were: contrast-enhanced or non-contrast magnetic resonance imaging, contrast-enhanced or non-contrast-enhanced computed tomography or radiographs. The periodicity and temporality of imaging were reported. We also describe the presence or absence of data related to the acquisition and analysis of imaging exams: apparatus used, evaluators, images obtained. In case of glenoid bone defect filling with bone grafts, data regarding graft and screws positioning, as well as signs of consolidation or pseudarthrosis, graft resorption or fracture, were assessed. For capsulolabral repair surgeries, repair healing was evaluated.

Statistical Analysis

Data were descriptively presented as absolute and percentage numbers, mean values, and standard deviation.

Results

After applying the selection criteria, 12 studies evaluating the clinical results of the surgical treatment of anterior shoulder instability were included. Two (17%) studies were published in the journal *Acta Ortopédica Brasileira* and 10 (83%) in *Revista Brasileira de Ortopedia* (► **Table 1**). In total, 733 shoulders were studied, with a mean value of 61.1 ± 73.2 shoulders per paper. The mean follow-up period, calculated by weighted average, was 35.4 months. No study had a standardized follow-up time, and 5 studies^{16–20} (42%) had a minimum follow-up period of more than 2 years. Ten studies^{17,18,20–27} (83%) were case series (level IV evidence), 1 (8%) was a case-control study¹⁶ (evidence III level), and 1 (8%) was a retrospective cohort study¹⁹ (evidence level III). There were no randomized studies or prospective cohorts.

Four studies^{16,22,24,26} (33%) evaluated the outcomes of the open treatment of anterior glenohumeral instability, 3 (25%) studied the Latarjet-Patte surgery,^{16,22,26} and 1 (8%) studied the labral injury repair.²⁴ Eight publications^{17–21,23,25,27} (66%) employed the arthroscopic repair of anterior labral injuries,

and 1 of them evaluated the outcome of this procedure associated with a Hill-Sachs lesion remplissage.²³ On average, each study assessed 3.7 ± 1.7 outcomes (► **Fig. 2** and ► **Table 2**).

Range of Motion

Among the studies evaluated, 7 (58%) reported the postoperative measurement of the range of motion in any plane.^{16–18,22,23,26,27} Seven papers (58%) presented lateral rotation results, while 6 (50%) evaluated medial rotation^{16–18,22,23,26} and 5,^{18,22,26,27} (42%) studied elevation. Three papers^{16,23,27} (25%) evaluated only 2 range of motion planes and 4^{17,18,22,26} (33%) presented range of motion measures on 3 planes. The methodology applied for range of motion measurement was reported in 3 (25%) papers,^{17,18,26} while the remaining did not report using a goniometer, the measurement technique or patient positioning.

Strength

Muscle strength after anterior glenohumeral instability treatment was determined in 4 studies^{16,20,22,24} (33%). Three papers (25%) used a quantitative measurement of muscle strength aided by a dynamometer and reported the position of the patient (orthostatic or neutral). One study²⁰ (8%) evaluated only the elevation strength of the patients, while the remaining papers (25%) evaluated the strength of medial shoulder rotation. Among the 3 studies evaluating the outcomes of Latarjet-Patte surgery, 2 (66%) assessed the strength of medial shoulder rotation.^{16,22}

Physical Examination Testing

The patients were submitted to physical examination tests after the surgical treatment in only 4 studies^{16,21,22,26} (33%). Among the maneuvers described to assess anterior glenohumeral instability, the most frequently reported test was apprehension, which was included in 4 studies.

Satisfaction and Return to Sports

None of the 12 studies included assessed the satisfaction with treatment or whether the patient would recommend the procedure to a third party or have surgery again; in addition, only 2 (17%) studies reported the number of patients returning to previous sports activities,^{19,26} although none of them used scores to measure such outcome.

Scores and Evaluation Questionnaires

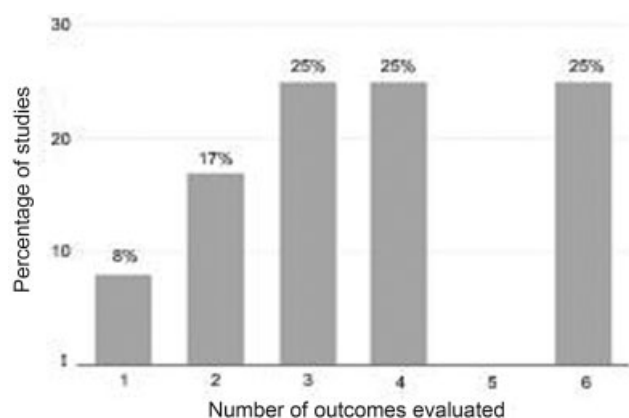
The Rowe score for instability²⁸ was used in 9 studies^{16–19,22–24,26,27} (75%), whereas 7 studies^{17,19,20,22–24,26} (58%) used the University of California, Los Angeles Shoulder Rating Scale (UCLA),²⁹ and 1 paper¹⁶ (8%) evaluated its results with the Walch-Duplay Score (► **Fig. 3**). Seven papers^{16,17,19,22–24,26} (58%) employed 2 evaluation scores, 3 studies^{18,20,27} (25%) presented their results with only 1 questionnaire, and 2²⁵ (17%) papers did not use evaluation scores or questionnaires.

Complications

Ten studies^{16–19,21–23,25–27} (83%) reported surgery-related complications. The most frequently reported complication

Table 1 Publications about the surgical treatment of anterior glenohumeral instability from 2007 to 2016

Author(s)	Title	Journal	Year	Volume (issue)	Pages
dos Santos et al ¹⁶	Evaluation of isometric strength and fatty infiltration of the subscapularis in Latarjet surgery	<i>Acta Ortopédica Brasileira</i>	2015	23 (3)	129–133
Ferreira Neto et al ²¹	Anterior instability of the shoulder. Retrospective study on 159 cases	<i>Acta Ortopédica Brasileira</i>	2011	19 (1)	41–44
Godinho et al ²⁰	Evaluation of functional results from shoulders after arthroscopic repair of complete rotator cuff tears associated with traumatic anterior dislocation	<i>Revista Brasileira de Ortopedia</i>	2016	51 (2)	163–168
Martel et al ²⁵	Evaluation of postoperative results from videoarthroscopic treatment for recurrent shoulder dislocation using metal anchors	<i>Revista Brasileira de Ortopedia</i>	2016	51 (1)	45–52
da Silva et al ²⁶	Evaluation of the results and complications of the Latarjet procedure for recurrent anterior dislocation of the shoulder	<i>Revista Brasileira de Ortopedia</i>	2015	50 (6)	652–659
Godinho et al ¹⁹	Bankart arthroscopic procedure: comparative study on use of double or single-thread anchors after a 2-year follow-up	<i>Revista Brasileira de Ortopedia</i>	2015	50 (1)	94–99
Miyazaki et al ¹⁸	Evaluation of the results from arthroscopic surgical treatment for traumatic anterior shoulder instability using suturing of the lesion at the opened margin of the glenoid cavity	<i>Revista Brasileira de Ortopedia</i>	2012	47 (3)	318–324
Miyazaki et al ¹⁷	Assessment of the results from arthroscopic surgical treatment for traumatic anterior shoulder dislocation: first episode	<i>Revista Brasileira de Ortopedia</i>	2012	47 (2)	222–227
de Almeida Filho et al ²⁷	Functional assessment of arthroscopic repair for recurrent anterior shoulder instability	<i>Revista Brasileira de Ortopedia</i>	2012	47 (2)	214–221
Gracitelli et al ²³	Results from filling “remplissage” arthroscopic technique for recurrent anterior shoulder dislocation	<i>Revista Brasileira de Ortopedia</i>	2011	46 (6)	684–690
Ikemoto et al ²²	Results from Latarjet surgery for treating traumatic anterior shoulder instability associated with bone erosion in the glenoid cavity, after minimum follow-up of one year	<i>Revista Brasileira de Ortopedia</i>	2011	46 (5)	553–560
Lech et al ²⁴	Integrity of the subscapularis tendon after open surgery for the treatment of anterior shoulder instability: a clinical and radiological evaluation	<i>Revista Brasileira de Ortopedia</i>	2009	44 (5)	420–426

**Fig. 2** Percentage distribution of the number of outcomes analyzed per study.

was glenohumeral instability recurrence, found in the 10 studies (83%). Sixty-five out of 680 patients (9.6%) sustained shoulder instability after surgical treatment. In patients undergoing arthroscopic repair of anterior labral injuries, glenohumeral instability recur in 53 of 564 patients (9.3%). In addition, 12 of 116 patients (10.3%) submitted to the Latarjet

Table 2 Evaluated outcomes and their frequency

Outcomes	n (%) of studies
Range of motion	7 (58)
Strength	4 (33)
Physical exam	4 (33)
Satisfaction	0 (0)
Return to sports	2 (17)
Scores	10 (83)
Complications	10 (83)
Imaging	6 (50)

surgery still presented shoulder instability. Among papers reporting this complication, only 5,^{21–23,26} (42%) defined which patients had postoperative apprehension, subluxation, or dislocation episodes. Other reported complications included pain, adhesive capsulitis, prominent anchors, and coracoid process pseudarthrosis.

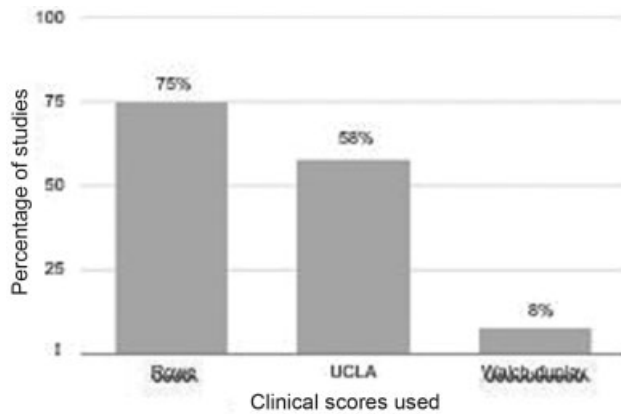


Fig. 3 Percentage of studies using clinical scores.

Imaging

Six studies^{16,22–24,26,27} (50%) performed postoperative imaging tests. The most common test was radiography, performed in 3 studies^{22,26,27} (25%). Two papers^{23,24} (16%) used magnetic resonance imaging and 1 study¹⁶ (8%) performed computed tomography scans. Only 1 paper¹⁶ (8%) reported the equipment used, as well as the imaging acquisition protocol. No paper informed the number of evaluators, and only 2 papers^{16,26} (16%) reported the timing for image acquisition. Two^{22,26} (66%) out of the 3 papers evaluating surgeries with glenoid bone defect filling with bone grafts had data on graft and screws positioning, as well as signs of consolidation or pseudarthrosis, resorption, or graft fracture. No study evaluated the healing of capsulolabral repairs.

Discussion

Relapsing anterior shoulder dislocation corresponds to approximately 8% of the consultations of a shoulder and elbow surgeon,²⁸ and its treatment is preferably surgical.² However, only 12 studies evaluated the clinical results of the surgical treatment of anterior relapsing shoulder dislocation between 2007 and 2016 in the 2 main Brazilian orthopedic journals, an average of 1.2 studies per year. High impact factor journals, such as *Arthroscopy* and the *American Journal of Sports Medicine*, have published an average of 2.4 and 6.6 articles per year, respectively, over the past 5 years.¹⁴

The included studies had an average follow-up period of 35.4 months, and only 42% of the papers^{16–20} presented cases with a minimum follow-up period of 2 years. This number is lower compared to international studies that have an average follow-up period of 59.7 months¹⁴. This data is extremely relevant, as we know that the main complication of the treatment of anterior glenohumeral instability is recurrence, and the follow-up time is very important in assessing this outcome.²⁹ Brazilian studies also have a lower evidence level. There were no prospective randomized studies or prospective cohorts, and 83% of the papers referred to case series (level IV of evidence).^{17,18,20–27}

Each study evaluated an average of 3.7 outcomes, which is a higher average than that of papers regarding the results of

the clinical rotator cuff repair treatment.¹⁵ There was also a great variability between outcomes evaluated at different studies; however, the description and measurement of postoperative complications and use of evaluation scores or questionnaires were observed in 83% of the papers. These numbers are similar to those of international studies, in which complication reports and rating scores were observed in 81% and 88% of the studies, respectively.¹⁴

The outcomes of range of motion, strength, physical examination tests, and imaging were similarly reported, albeit less frequently, compared to international studies.¹⁴ However, the technique employed, number of evaluators, and evaluation timing were commonly not described. There was a great variability regarding the imaging modality used, as well as the parameters for radiographic outcomes evaluation, which may hinder the use of these data in systematic reviews. No study reported the patient satisfaction with treatment, and only 2 papers^{19,26} (17%) described the number of patients who returned to sports, a number lower than that of papers published in foreign journals.

In Brazilian studies, the most commonly used assessment questionnaires were the Rowe score for instability and the University of California Los Angeles (UCLA) shoulder rating scale, found in 75% and 58% of articles, respectively. These assessment tools have already been translated and culturally adapted to Portuguese.^{30,31} However, since these questionnaires have several ambiguities in their assessment items that may hamper patient response, they are not deemed ideal tools for clinical research due to innumerable inconsistencies in their validity, reliability, and responsiveness.¹³

The UCLA score was initially developed for patients undergoing total shoulder arthroplasty.³² Ellman et al³³ were the first authors to apply this tool to assess patients with rotator cuff tears; since then, it has been used in several publications. However, it is not indicated to evaluate patients with glenohumeral dislocation, as it does not assess shoulder stability. In studies published in high-impact orthopedic journals, the Rowe score is commonly used, although at a lower frequency (46%). The second assessment questionnaire most commonly used in these studies was the Western Ontario Shoulder Instability (WOSI) index, found in 31% of the papers. The WOSI is a tool designed solely to evaluate patients with glenohumeral instability.³⁴ It has good responsiveness, reliability, and internal validity.³⁵ This index is also useful for detecting minimal significant differences between treatments and clinical courses.¹³ Although the WOSI questionnaire has already been translated and culturally adapted to Portuguese,³⁶ we have not found studies evaluating its validity and reliability in our population.

Instability recurrence is the most frequently reported postoperative complication, and it has been found in 10 studies (83%). However, its definition in the studies included here, as well as in the orthopedic literature,³⁷ is not very clear, ranging from shoulder apprehension or subluxation to postoperative dislocation episodes. The non-uniformity of this parameter hinders papers comparison, and it undermines the analysis of this outcome in literature reviews. Brazilian studies reported that 9.6% of the shoulders remained unstable after surgical

treatment. This number does not differ from those observed in other reviews, which report rates of glenohumeral instability recurrence ranging from 2 to up to 20%.^{29,38}

Our study has some limitations. We reviewed papers from the last decade and only from two Brazilian journals. Our search strategy may have included studies by foreign authors published in Brazilian journals, but it did not include papers by Brazilian authors published in international journals. In addition, we included all types of clinical studies, so our review has a level IV evidence. However, the greater possibility of bias in lower evidence studies did not influence our results because we evaluated tools used, not the outcomes themselves.

We believe that outcome assessment methods standardization in the treatment of anterior glenohumeral instability must be encouraged. Range of motion and muscle strength assessment could be aligned to international studies, as well as outcomes such as patient satisfaction with the treatment and return to sports. The WOSI scale, already culturally adapted and translated into Portuguese, should be used in Brazilian studies. This questionnaire has greater responsiveness and reliability than the Rowe and UCLA scores. The acquisition method, evaluators and timing of postoperative imaging analysis should be reported by the authors; in addition, imaging modalities for capsulolabral repairs healing³⁹ and bone graft consolidation evaluation⁴⁰ must be standardized.

Conclusion

We found only 12 clinical studies on anterior glenohumeral instability published between 2007 and 2016. The average number of outcomes evaluated per study was 3.7, and we found a great variability among them. The most commonly used scales were the Rowe score for instability and the UCLA shoulder rating scale, which were considered to have low reliability, responsiveness, and internal consistency.

Conflicts of Interest

The authors declare that there is no conflict of interest.

References

- Cutts S, Premph M, Drew S, Steven D. Anterior shoulder dislocation. *Ann R Coll Surg Engl* 2009;91(01):2-7
- Leroux T, Wasserstein D, Veillette C, et al. Epidemiology of primary anterior shoulder dislocation requiring closed reduction in Ontario, Canada. *Am J Sports Med* 2014;42(02):442-450
- Owens BD, Dawson L, Burks R, Cameron KL. Incidence of shoulder dislocation in the United States military: demographic considerations from a high-risk population. *J Bone Joint Surg Am* 2009;91(04):791-796
- Handoll HH, Almayyah MA, Rangan A. Surgical versus non-surgical treatment for acute anterior shoulder dislocation. *Cochrane Database Syst Rev* 2004;(01):CD004325
- Gartsman GM, Brinker MR, Khan M. Early effectiveness of arthroscopic repair for full-thickness tears of the rotator cuff: an outcome analysis. *J Bone Joint Surg Am* 1998;80(01):33-40
- Gartsman GM, Morris BJ, Unger RZ, Laughlin MS, Elkousy HA, Edwards TB. Characteristics of clinical shoulder research over the last decade: a review of shoulder articles in *The Journal of Bone & Joint Surgery* from 2004 to 2014. *J Bone Joint Surg Am* 2015;97(05):e26
- Puga VO, Lopes AD, Costa LO. Avaliação das adaptações transculturais e propriedades de medida de questionários relacionados às disfunções do ombro em língua portuguesa: uma revisão sistemática. *Rev Bras Fisioter.* 2012;16(02):85-93
- Brinker MR, Cuomo JS, Popham GJ, O'Connor DP, Barrack RL. An examination of bias in shoulder scoring instruments among healthy collegiate and recreational athletes. *J Shoulder Elbow Surg* 2002;11(05):463-469
- Garratt A, Schmidt L, Mackintosh A, Fitzpatrick R. Quality of life measurement: bibliographic study of patient assessed health outcome measures. *BMJ* 2002;324(7351):1417
- Higginson IJ, Carr AJ. Measuring quality of life: Using quality of life measures in the clinical setting. *BMJ* 2001;322(7297):1297-1300
- Makhni EC, Steinhaus ME, Morrow ZS, et al. Outcomes assessment in rotator cuff pathology: what are we measuring? *J Shoulder Elbow Surg* 2015;24(12):2008-2015
- Harvie P, Pollard TC, Chennagiri RJ, Carr AJ. The use of outcome scores in surgery of the shoulder. *J Bone Joint Surg Br* 2005;87(02):151-154
- Kirkley A, Griffin S, Dainty K. Scoring systems for the functional assessment of the shoulder. *Arthroscopy* 2003;19(10):1109-1120
- Lukenchuk J, Sims LA, Shin JJ. Variability in outcome reporting for operatively managed anterior glenohumeral instability: a systematic review. *Arthroscopy* 2017;33(02):477-483
- Assunção JH, Malavolta EA, Domingues VR, Gracitelli ME, Ferreira Neto AA. Avaliação dos desfechos no tratamento da rotura do manguito rotador: o que usamos no Brasil? *Rev Bras Ortop.* 2017. Disponível em: <http://www.sciencedirect.com/science/article/pii/S0102361616302764>
- Dos Santos RB, Kauffman FN, de Lima GP, Ferreira AM, Dos Santos SM, Aguiar JL. Evaluation of isometric strength and fatty infiltration of the subscapularis in Latarjet surgery. *Acta Ortop Bras* 2015; 23(03):129-133
- Miyazaki AN, Fregoneze M, Santos PD, et al. Avaliação dos resultados do tratamento cirúrgico artroscópico da luxação traumática anterior de ombro: primeiro episódio. *Rev Bras Ortop* 2012;47(02):222-227
- Miyazaki AN, Fregoneze M, Santos PD, et al. Avaliação dos resultados do tratamento cirúrgico artroscópico da instabilidade anterior traumática do ombro com sutura da lesão na margem cruentizada da cavidade glenoidal. *Rev Bras Ortop* 2012;47(03): 318-324
- Godinho GG, Freitas JM, França FO, Lago e Santos FM, Aragão AA, Barros MK. Procedimento artroscópico de Bankart: estudo comparativo do uso de âncoras com fio duplo ou simples após seguimento de dois anos. *Rev Bras Ortop* 2015;50(01):94-99
- Godinho GG, Freitas JM, de Oliveira França F, Santos FM, de Simoni LF, Godinho PC. Avaliação dos resultados funcionais dos ombros submetidos ao reparo artroscópico de roturas completas do manguito rotador associadas a luxações traumáticas anteriores. *Rev Bras Ortop* 2016;51(02):163-168
- Ferreira Neto AA, Camanho GL, Felix AM, et al. Tratamento cirúrgico artroscópico da instabilidade anterior do ombro. Estudo Retrospectivo de 159 casos. *Acta Ortop Bras* 2011;19(01):41-44
- Ikemoto RY, Murachovskiy J, Nascimento LG, et al. Resultados da cirurgia de Latarjet no tratamento da instabilidade anterior traumática do ombro associada à erosão óssea da cavidade glenoidal - seguimento mínimo de um ano. *Rev Bras Ortop* 2011;46(05):553-560
- Gracitelli ME, Helito CP, Malavolta EA, et al. Resultados do procedimento artroscópico de remplissage na luxação anterior recidivante do ombro. *Rev Bras Ortop* 2011;46(06):684-690
- Lech O, Piluski P, Tambani R, Castro N, Pimentel G. Integridade do músculo subescapular após a cirurgia aberta para tratamento da luxação recidivante glenoumeral: avaliação clínica e radiológica. *Rev Bras Ortop* 2009;44(05):420-426
- Martel EM, Rodrigues A, Dos Santos Neto FJ, Dahmer C, Ranzi A, Dubiela RS. Avaliação de resultados pós-operatórios do

- tratamento videoartroscópico para luxação recidivante de ombro com o uso de âncoras metálicas. *Rev Bras Ortop* 2016;51(01):45–52
- 26 da Silva LA, da Costa Lima AG, Kautsky RM, Santos PD, do Val Sella G, Checchia SL. Avaliação dos resultados e das complicações em pacientes com instabilidade anterior de ombro tratados pela técnica de Latarjet. *Rev Bras Ortop* 2015;50(06):652–659
 - 27 de Almeida Filho IA, de Castro Veado MA, Fim M, da Silva Corrêa LV, de Carvalho AE Junior. Avaliação funcional do reparo artroscópico da instabilidade anterior recidivante do ombro. *Rev Bras Ortop* 2012;47(02):214–221
 - 28 Malavolta EA, Gracitelli MEC, Assunção JH, Pinto GMR, da Silveira AZF, Ferreira AA. Shoulder disorders in an outpatient clinic: an epidemiological study. *Acta Ortop Bras* 2017;25(03):78–80
 - 29 Gasparini G, De Benedetto M, Cundari A, et al. Predictors of functional outcomes and recurrent shoulder instability after arthroscopic anterior stabilization. *Knee Surg Sports Traumatol Arthrosc* 2016;24(02):406–413
 - 30 Marcondes FB, de Vasconcelos RA, Marchetto A, de Andrade ALL, Zoppi A, Etchebehere M. Translation and cross-cultural adaptation of the rowe score for portuguese. *Acta Ortop Bras* 2012;20(06):346–350
 - 31 Oku EC, Andrade AP, Stadiniky SP, Carrera EF, Tellini GG. Tradução e adaptação cultural do Modified-University of California at Los Angeles Shoulder Rating Scale para a língua portuguesa. *Rev Bras Reumatol* 2006;46(04):246–252
 - 32 Amstutz HC, Sew Hoy AL, Clarke IC. UCLA anatomic total shoulder arthroplasty. *Clin Orthop Relat Res* 1981;(155):7–20
 - 33 Ellman H, Hanker G, Bayer M. Repair of the rotator cuff. End-result study of factors influencing reconstruction. *J Bone Joint Surg Am* 1986;68(08):1136–1144
 - 34 Kirkley A, Griffin S, McLintock H, Ng L. The development and evaluation of a disease-specific quality of life measurement tool for shoulder instability. The Western Ontario Shoulder Instability Index (WOSI). *Am J Sports Med* 1998;26(06):764–772
 - 35 Rouleau DM, Faber K, MacDermid JC. Systematic review of patient-administered shoulder functional scores on instability. *J Shoulder Elbow Surg* 2010;19(08):1121–1128
 - 36 Barbosa G, Leme L, Saccol MF, Pocchini A, Ejnisman B, Griffin S. Tradução e adaptação cultural para o português do Brasil do Western Ontario Shoulder Instability Index (WOSI). *Rev Bras Med Esporte* 2012;18(01):35–37
 - 37 Chalmers PN, Mascarenhas R, Leroux T, et al. Do arthroscopic and open stabilization techniques restore equivalent stability to the shoulder in the setting of anterior glenohumeral instability? a systematic review of overlapping meta-analyses. *Arthroscopy* 2015;31(02):355–363
 - 38 Karataglis D, Agathangelidis F. Long term outcomes of arthroscopic shoulder instability surgery. *Open Orthop J* 2017;11:133–139
 - 39 Stein T, Mehling AP, Reck C, et al. MRI assessment of the structural labrum integrity after Bankart repair using knotless bio-anchors. *Knee Surg Sports Traumatol Arthrosc* 2011;19(10):1771–1779
 - 40 Zhu YM, Jiang CY, Lu Y, Li FL, Wu G. Coracoid bone graft resorption after Latarjet procedure is underestimated: a new classification system and a clinical review with computed tomography evaluation. *J Shoulder Elbow Surg* 2015;24(11):1782–1788