

Portal Vein Thrombosis: Diagnosis and Endovascular Management

Pfortaderthrombose: Diagnose und endovaskuläres Management

Authors

Connie Ju¹ , Xin Li², Sameer Gadani³, Baljendra Kapoor³, Sasan Partovi³

Affiliations

- 1 Radiology, University of California Los Angeles Health System, Los Angeles, United States
- 2 Radiology, University of Pennsylvania Health System, Philadelphia, United States
- 3 Interventional Radiology, Cleveland Clinic Foundation, Cleveland, United States

Key words

portal vein thrombosis, thrombolysis, TIPS, interventional procedures

received 08.02.2021

accepted 12.07.2021

published online 14.10.2021

Bibliography

Fortschr Röntgenstr 2022; 194: 169–180

DOI 10.1055/a-1642-0990

ISSN 1438-9029

© 2021, Thieme. All rights reserved.

Georg Thieme Verlag KG, Rüdigerstraße 14,
70469 Stuttgart, Germany

Correspondence

Dr. Connie Ju

Radiology, University of California Los Angeles Health System,
757 Westwood Plaza, Suite 1638, 90095 Los Angeles,
United States

Tel.: 42 43 20 17 97

connieju@mednet.ucla.edu

ZUSAMMENFASSUNG

Hintergrund Die Pfortaderthrombose (PVT) ist eine seltene, aber schwere Erkrankung, die klinisch signifikante Folgeerscheinungen wie eine Verschlechterung der portalen Hypertonie oder eine mesenteriale Ischämie verursachen kann. Fälle, die auf eine medizinische Behandlung nicht ansprechen, können zur endovaskulären Intervention überwiesen werden. In der Literatur sind verschiedene technische Gesichtspunkte beschrieben worden, aber ein umfassender Vergleich dieser verschiedensten Methoden fehlt.

Methoden In diesem Artikel werden die Diagnose und die endovaskuläre Behandlung der PVT besprochen, einschließlich der Bereiche, in denen weitere Forschung erforderlich ist.

Ergebnisse PVT-Fälle lassen sich mit Ultraschall, Computertomografie oder Magnetresonanztomografie leicht diagnosti-

zieren. Die Behandlung beginnt häufig mit einer systemischen Antikoagulation, und in ausgewählten Fällen können endovaskuläre Interventionen eingesetzt werden. Die Bestimmung des optimalen Zugangs zum Pfortadersystem hängt von der Grunderkrankung und der Chronizität des Thrombus sowie vom Grad der Okklusion ab. Sobald der Zugang zum Pfortadersystem hergestellt ist, kann eine Katheter-gesteuerte Therapie durchgeführt werden, um eine Rekanalisierung zu erreichen.

Schlussfolgerung Trotz der Heterogenität der Patienten bei Vorstellung können Fälle von PVT mit verschiedenen bildgebenden Verfahren leicht diagnostiziert werden. Bei der Planung von Interventionen müssen die Grunderkrankung und die Chronizität des Thrombus berücksichtigt werden.

Kernaussagen:

- Diese Übersicht ermöglicht es den interventionell tätigen Ärzten, Rahmenbedingungen für die Behandlung von Pfortaderthrombosen zu schaffen, indem Risikofaktoren für Patienten und Thrombusmerkmale identifiziert werden, die das Patientenmanagement bestimmen.
- Die besonderen Risiken und Vorteile transhepatischer, transsplenischer und transmesenterialer Ansätze zur Etablierung eines portalvenösen Zugangs werden diskutiert.
- Vorteile und Komplikationen der Thrombolysis, der Thrombektomie und der Anlage eines transjugulären intrahepatischen portosystemischen Shunts zur Behandlung von Pfortaderthrombosen werden basierend auf der umfangreichen Erfahrung in unserem Institut im Detail besprochen.

ABSTRACT

Background Portal vein thrombosis (PVT) is a rare but severe entity that can cause clinically significant sequela such as worsening portal hypertension or mesenteric ischemia. Those cases refractory to medical management may be referred for endovascular intervention. Several technical considerations have been described in the literature, but a cohesive comparison of these multiple techniques is lacking.

Methods The purpose of this article is to review the diagnosis and endovascular management of PVT, including areas in which further research is warranted.

Results Cases of PVT can be readily diagnosed using ultrasound, computed tomography, or magnetic resonance imaging. Treatment often begins with systemic anticoagulation and endovascular interventions may be used in selected cases. Determining the optimal approach to accessing the

portal venous system depends on the underlying disease and chronicity of the thrombus and the degree of occlusion. Once access to the portal venous system is established, catheter-directed therapy may be performed to achieve recanalization.

Conclusion Despite the heterogeneity in patient presentation, cases of PVT can be readily diagnosed across several imaging modalities. Strategizing interventional approaches involves evaluation of the underlying disease and the chronicity of the thrombus.

Key Points:

- This review will enable interventionalists to establish a framework for treating portal vein thrombosis by identifying patient risk factors and thrombus characteristics that determine patient management.

- The unique risks and benefits for transhepatic, transsplenic, and transmesenteric approaches for establishing portal venous access will be discussed.
- Advantages and complications of thrombolysis, thrombectomy, and transjugular intrahepatic portosystemic shunt creation for treating portal vein thrombosis will be reviewed in detail based on our extensive institutional experience.

Citation Format

- Ju C, Li X, Gadani S et al. Portal Vein Thrombosis: Diagnosis and Endovascular Management. *Fortschr Röntgenstr* 2022; 194: 169–180

Introduction

Portal vein thrombosis (PVT) is defined as clot formation within the portal venous system that leads to complete or incomplete portal venous obstruction. The underlying mechanism contributing to the development of PVT is a hypercoagulable state, most commonly found in patients with underlying liver cirrhosis, malignancy, acquired prothrombotic disease, or an inflammatory condition. The estimated overall prevalence of PVT is low (approximately 1%), but research has shown that patients with cirrhosis or underlying malignancy are at increased risk, with some studies demonstrating a prevalence of PVT in this population ranging from 10% to 26% [1]. However, because PVT can remain asymptomatic in patients with chronic, gradual thrombus development or limited thrombus extension, epidemiological studies tend to underestimate the true incidence.

Treatment of PVT often begins with anticoagulation and escalates to endovascular interventions if anticoagulation alone fails to reduce thrombus burden. Because PVT can be subdivided into acute and chronic presentations, as well as cirrhotic and noncirrhotic etiologies, evidence supporting the use of anticoagulation and endovascular approaches is not standardized. This heterogeneity within the literature provides limited benefit to interventionalists encountering this disease, and treatment approaches therefore often have to be tailored to the individual. Because of this limitation, the present article does not attempt to present strict guidelines, but rather uses a combination of institutional experience and existing literature to highlight risks and benefits of various treatment approaches.

Pathophysiology and Natural History

The pathophysiology of PVT is related to the disturbance of Virchow's triad, in which increased venous stasis, endothelial damage, and hypercoagulable states predispose patients to thrombus formation. The development of PVT can be further divided into acute and chronic PVT and into cirrhotic and noncirrhotic etiologies.

Cirrhotic and Noncirrhotic Cases

Cirrhotic patients are at an increased risk for PVT due to the presence of coagulopathy, endothelial dysfunction, and venous stasis from portal hypertension. In liver disease, the decreased production of factor VIII, Von Willebrand factor, and antithrombin initiates platelet aggregation and thrombus formation. Hepatic endothelial dysfunction is the sequela of increased oxidative stress and decreased nitric oxide bioavailability due to increased free radical injury and disruption of vascular homeostasis respectively [2]. The pathophysiology of underlying noncirrhotic causes of PVT is similar to that of underlying cirrhotic causes, namely coagulopathy and disturbance of endothelial integrity.

Inherited systemic prothrombotic disorders predispose patients to PVT in the absence of underlying liver disease. For instance, JAK2 mutations are associated with myeloproliferative disorders affecting the production of red blood cells or platelets and are implicated in abnormal clot formation. Three recent European cohort studies testing approximately 432 cases of noncirrhotic PVT demonstrated that 16% of cases had underlying JAK2 mutations and 20% had some inherited prothrombotic mutations [3]. The inherited disorders included factor V Leiden mutations, protein C or S deficiency, and antithrombin deficiencies, which contribute to PVT development through the derangement of mechanisms related to clot breakdown.

Extrinsic factors increasing the risk of noncirrhotic PVT include intra-abdominal inflammation or infection. The pro-inflammatory state generated by immune cell response to pathogens underpins the prothrombotic state in infection. Neutrophils in particular have recently been implicated in this process with the discovery of their role in intrinsic pathway activation and tissue factor delivery by neutrophil extracellular traps. Protease-activated receptors found on both leukocyte and platelet membranes upregulate the expression of endothelial tissue factor, which is involved in clot formation, further highlighting the ongoing communication between the endothelium and inflammatory response [4].

Natural History

The most common sequela of acute PVT is spontaneous recanalization, which occurs in 45 % to 70 % of patients who do not receive treatment [5]. The absence of spontaneous recanalization is not clearly associated with poor clinical outcomes or increased short-term mortality, likely because these outcomes are primarily influenced by the underlying disease process itself and not directly by PVT [5–8]. The natural history of acute PVT also depends on the extent of initial thrombus burden, with some severe cases presenting with splanchnic congestion and bowel necrosis. The true incidence of mesenteric ischemia in cases of acute PVT is unclear, although 30-day mortality rates associated with bowel ischemia in mesenteric venous thrombosis have been reported to approach 32 % [9]. Lastly, unrecognized or persistent acute PVT may progress to chronic PVT, which is characterized by cavernous transformation of the portal vein and symptoms of worsening portal hypertension such as ascites, variceal bleeding, or encephalopathy [8]. Treatment and outcome considerations for acute versus chronic PVT in cirrhotic versus noncirrhotic patients will be elucidated in the following sections.

Diagnosis

The European Association for the Study of the Liver (EASL) guideline states that Doppler imaging is the first-line diagnostic tool in the context of abdominal pain with a suspicion for portal vein pathology. Subsequently, the diagnosis and extent of the clot burden need to be confirmed with contrast-enhanced computed tomography (CT)/magnetic resonance imaging (MRI) [10]. However, ultrasound imaging is operator-dependent. Therefore, the possibility of false-negative reports remains a significant limitation, particularly as the thrombus may not be well-appreciated on grayscale imaging alone. Conjunctive use of Doppler imaging is therefore of utmost importance, as this modality may demonstrate greatly reduced velocities with aphasic waveforms. Such findings are suggestive of portal hypertension and PVT in the setting of intraluminal filling defects.

Cross-sectional imaging techniques such as CT and MRI are also helpful in evaluating PVT, especially for cases in which extension of the thrombus into the superior mesenteric vein or splenic vein is suspected. A new thrombus may appear with increased attenuation on CT and will lack enhancement in the presence of intravenous contrast unless tumor thrombus is present. In cases of chronic PVT, the presence of linear calcification patterns, collaterals, and cavernous transformation can be seen on both CT and MRI [11]. Thus, although liver Doppler ultrasound imaging is the preferred screening modality for PVT, contrast-enhanced cross-sectional imaging allows for more extensive evaluation of collateral vasculature, pathology contributing to the development of PVT, and procedural planning [11].

Cases of acute noncirrhotic and acute-on-chronic cirrhotic PVT also require further workup of local and systemic factors, such as cancer progression, extrinsic compression, intra-abdominal infection, thrombophilia, and systemic hematologic disorders.

Treatment

Practical guidelines support anticoagulation as the first-line treatment for PVT, although such recommendations are largely based on studies enrolling heterogeneous patient populations with varying risk factors, thrombus locations, and thrombotic burdens [10, 12, 13]. Additionally, studies assessing thrombolysis, thrombectomy, or transjugular intrahepatic portosystemic shunt (TIPS) placement for these patients have been mostly limited to case series [1416]. There is a lack of validated randomized prospective controlled trials comparing the outcomes of these interventions, likely because PVT presentations are heterogeneous and symptomatic disease is rare. Retrospective studies have also differed in the categorization of PVT based on chronicity, location, or extension of thrombus into the surrounding vasculature [17]. As such, standardized approaches to treatment beyond anticoagulation have not yet been incorporated into professional society guidelines, and PVT must be managed in a multidisciplinary manner on a patient-by-patient basis.

Anticoagulation

For initial treatment, the EASL guidelines recommend anticoagulation as the first-line therapy for cirrhotic PVT and acute noncirrhotic, non-malignant PVT [10]. Similarly, the American Association for the Study of Liver Diseases recommends anticoagulation therapy for recently occlusive or partially occlusive cirrhotic PVT and acute noncirrhotic PVT without contraindications to anticoagulation, such as central nervous tumor, gastrointestinal bleeding, and recent stroke [12]. However, the evidence cited within these guidelines to support the use of anticoagulant therapy remains limited. One of the larger prospective studies evaluating the effect of anticoagulation on PVT outcomes in 102 patients reported a 38 % recanalization rate for patients receiving early systemic anticoagulation, whereas those who received late or no anticoagulation had decreased rates of recanalization. Within this study, however, only 2 patients did not receive anticoagulant therapy compared with 95 who did [13].

Cirrhotic Patients

To date, three meta-analyses have compared anticoagulation with low-molecular-weight heparin, vitamin K antagonists, and direct oral anticoagulation for PVT treatment in acute or chronic cirrhotic PVT patients (► **Table 1**) [15, 18, 19]. These studies consistently demonstrated higher rates of recanalization in treated patients (42–77 %) than in nontreated patients (26–33 %) [15, 18, 19]. However, the analyses by Qi et al. [15] and Mohan et al. [19] demonstrated significant heterogeneity between the included studies. The reported response rates also did not consistently distinguish between partial and complete recanalization, which limits comparison. Because all three meta-analyses were performed in the cirrhotic patient population, extrapolation of these results to noncirrhotic PVT patients remains to be determined.

► **Table 1** Comparison of recanalization rates in cirrhotic patients with various anticoagulation agents based on 3 meta-analyses [15, 18, 19].

treatment	study	recanalization rate
combined*	Qi et al. [15]	41.5 %
	Loffredo et al. [18]	53 %
	Mohan et al. [19]	66.7 %
low-molecular-weight heparin	Mohan et al. [19]	60.7 %
Vitamin K antagonists	Mohan et al. [19]	66 %
direct oral anticoagulation	Mohan et al. [19]	76.7 %
no treatment	Mohan et al. [19]	26 %
	Loffredo et al. [18]	33 %

* Multiple anticoagulation agents used in treatment.

Noncirrhotic Patients

Similar data for acute noncirrhotic PVT patients are limited, with only one retrospective study showing higher rates of recanalization and lower rates of bleeding events with direct oral anticoagulation than with warfarin [20]. Anticoagulation use does appear to improve overall recanalization rates when compared with non-use of anticoagulation. However, the translation of such findings to patient outcomes remains elusive. Further studies assessing the effects of these anticoagulants on mortality or recurrence rates are warranted.

The risk of adverse bleeding events, particularly in patients with underlying coagulopathy, is also a topic of contention, particularly when treating patients with liver disease who are already prone to bleeding [7, 17]. Limited evidence suggests that any increase in bleeding risk is often clinically insignificant and nonvariceal in nature [21–24]. In cirrhotic patients with PVT, concomitant anticoagulation use does not appear to increase the risk of complications. One purported hypothesis for this is that the gradual resolution of the thrombus during anticoagulation treatment reduces portal pressure and therefore variceal bleeding risk [21].

Anticoagulation is considered to have failed when patients experience persistent thrombosis refractory to treatment after 6 months or mesenteric ischemia requiring escalation of care. Furthermore, even with proper anticoagulation, patients with documented clot resolution may still develop portal hypertension [25]. In such cases, more advanced interventions involving endovascular procedures can be considered.

Endovascular Treatment

There is no established role for endovascular interventions in the management of PVT, and the benefits of endovascular therapy are still under investigation. In our experience, there are a few specific clinical scenarios in which endovascular therapy can play a role.

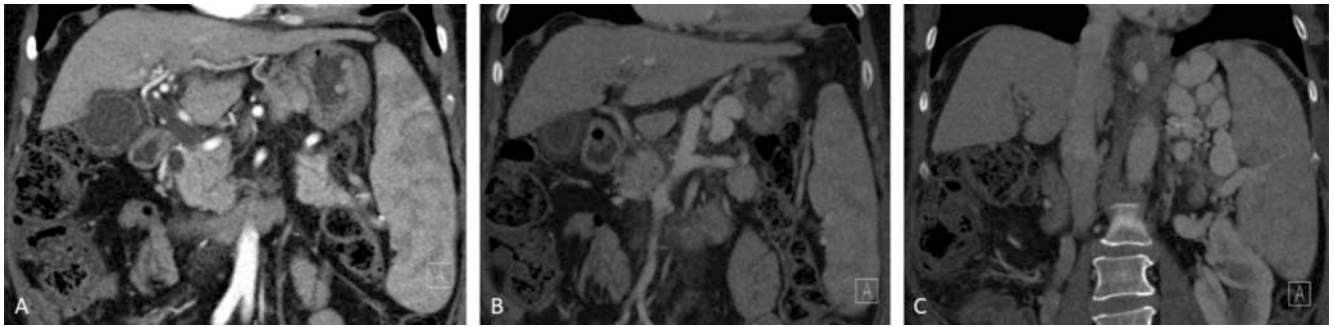
Cirrhotic Patients

In cirrhotic patients with contraindication to or inadequate response to anticoagulation, the benefits of endovascular therapy are two-fold: the therapy can salvage liver transplant candidacy and treat symptomatic portal hypertension, which may include variceal bleeding, refractory ascites, hepatic hydrothorax, among other symptoms. Per the EASL guidelines, it is a level B2 recommendation that liver transplant patients should be referred for TIPS placement if patients present with progressive PVT on anticoagulation (► Fig. 1, 2) [10]. In the subset of acute cirrhotic PVT patients, endovascular therapy should be considered to prevent intestinal ischemia and acute symptomatic portal hypertension, including recurrent or impending variceal bleeding. The risks of impending bowel ischemia can also be estimated with laboratory markers (inflammatory markers), radiologic assessment (bowel wall thickening), and clinical assessment (worsening abdominal pain). It is important to note that the incidence of acute PVT is much lower in the cirrhotic patients versus noncirrhotic patients, due to the presence of collateral circulation [12].

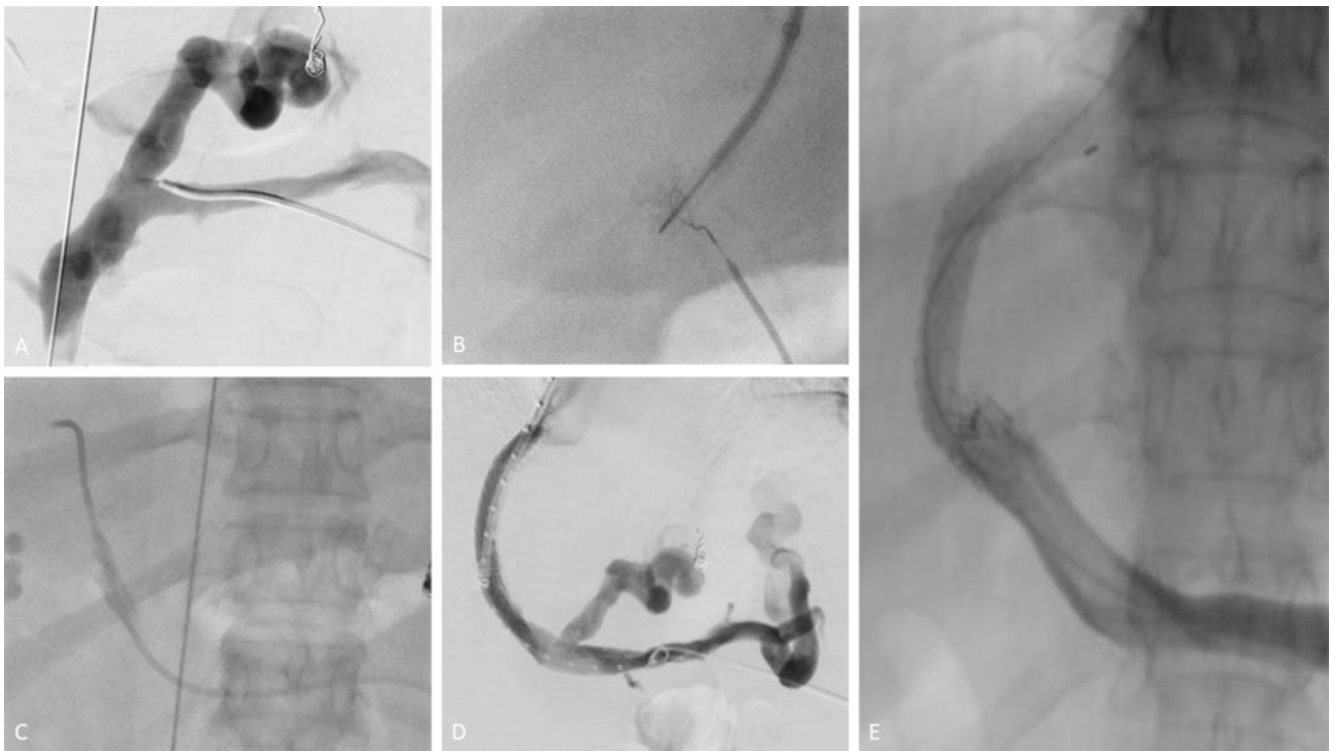
Noncirrhotic Patients

For noncirrhotic, nonmalignant patients with acute thrombus formation, the goal of endovascular therapy is to prevent thrombus extension and its acute and chronic sequelae, including the development of portal hypertension and intestinal ischemia. Therefore, indications for endovascular therapy in noncirrhotic patients may include variceal bleeding, refractory ascites, hepatic hydrothorax, among other symptoms (► Fig. 3–6).

It is important to note that endovascular therapy is associated with risks, and direct comparison studies between endovascular and medical therapies are scarce. Recent studies performed in small retrospective cohorts showed that despite successful recanalization, outcomes may be affected by posttreatment complications such as re-thrombosis, symptom recurrence, or bleeding [26, 27]. Rossle et al. [28] found that complete response rates on imaging were higher for patients treated with both endovascular therapy and anticoagulation than for those treated with anticoag-



► **Fig. 1** A 64-year-old man with nonalcoholic steatohepatic liver cirrhosis presented with episodes of upper gastrointestinal bleeding. During workup for a liver transplant, the patient was diagnosed with portal vein thrombosis with cavernous transformation of the main portal vein. Thrombolysis was indicated to preserve liver transplant candidacy. (A–C) Coronal CT images of the liver demonstrate chronic occlusion of the portal vein with periportal collaterals as well as a large spleno-gastrorenal shunt (A: arterial phase; B and C: portal venous phase).



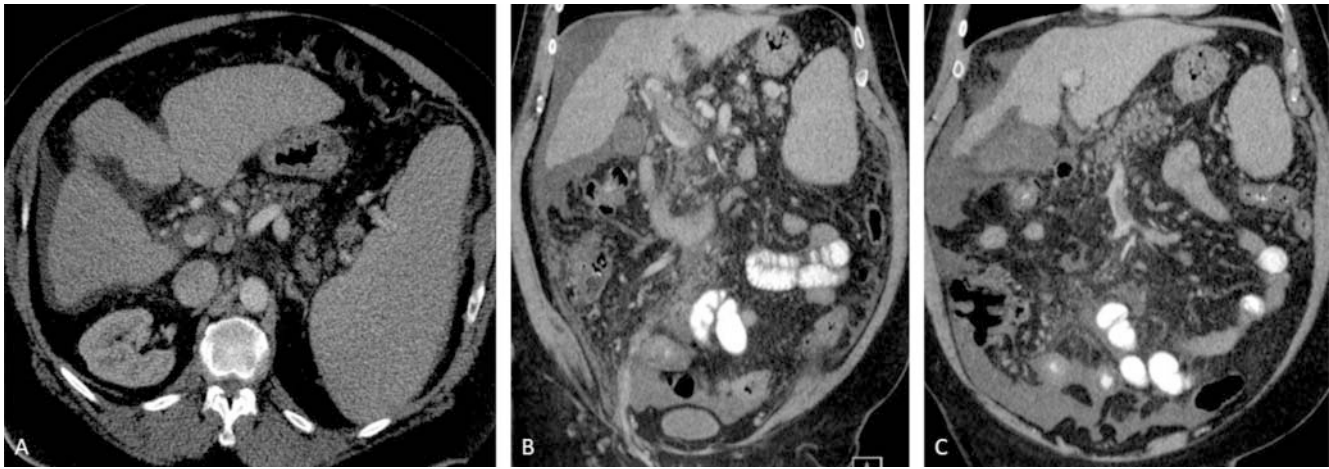
► **Fig. 2** Images from the same patient described in ► **Fig. 1**. A Splenic venogram demonstrates complete occlusion of the portal vein with large left gastric vein leading to gastric varices. B, C Successful recanalization of the chronically occluded portal vein with placement of a snare in the intrahepatic portal vein as the target during puncture from the hepatic venous site. D Image obtained after TIPS placement and balloon venoplasty of the main portal vein. E At the 6-month follow-up, portal venography reveals patency of the main portal vein with resolved left gastric varices.

ulation alone. Based on these data, there is a role for combination therapy involving both anticoagulation and endovascular approaches.

Endovascular Access Approach

When considering endovascular intervention techniques, interventionalists must first decide on the optimal approach to establish access to the portal venous system. This can be performed directly using a transjugular (TIPS) approach or a percutaneous transhepatic approach or indirectly using a transsplenic or transmesenteric route.

The transjugular intrahepatic approach is a popular method to establish portal vein access and may be performed under fluoroscopy with intravascular ultrasound (IVUS) or intracardiac echography (ICE) guidance. In our institution, IVUS is mainly used to assess for thrombus burden in the portal system and ICE is used to guide access into the portal branch. A recent study has shown that IVUS and ICE guidance could decrease the rate of complications [29]. After the thrombus is reached via transjugular retrograde access with placement of a TIPS stent, thrombolysis or thrombectomy can be performed. The advantage of this approach is that it provides the opportunity to perform comple-



► **Fig. 3** A 58-year-old man with alcoholic liver cirrhosis presented to the emergency department with nonspecific right upper and lower quadrant abdominal pain. **A, B** Axial and coronal CT scans of the liver in the portal venous phase demonstrate a nonocclusive thrombus in the main portal vein. **C** Coronal CT scan of the abdomen shows a partially occlusive thrombus in the superior mesenteric vein with thickening of the terminal ileal loops, consistent with acute mesenteric ischemia.

mentary procedures such as variceal embolization and portal system decompression. The percutaneous approach may be necessary, however, when the transjugular approach is too difficult due to extensive thrombotic involvement of the portal venous system. Percutaneous access has also been reported to be less technically challenging [30–32]. However, a disadvantage of the percutaneous approach involves the size of the sheath that can be safely placed, which is typically approximately 8 French based on our institutional experience. This sheath size limits possibilities for endovascular interventions, as larger percutaneous sheaths traversing the liver capsule and parenchyma are associated with an increased bleeding risk.

Other percutaneous approaches include the transsplenic and transmesenteric techniques. These alternative routes may be of benefit when complete occlusion of the portal vein precludes retrograde recanalization using the transhepatic or transjugular approach alone (► **Fig. 3, 4**). The transsplenic approach, which may be used to achieve antegrade access to the portal vein, has demonstrated high technical success rates, with some authors arguing it is safer to perform than a transjugular intrahepatic approach [33, 34]. Additionally, one retrospective review comparing outcomes between transsplenic and transhepatic access in 148 patients found no significant differences between groups in procedural success rates or bleeding complications even though the spleen is highly vascularized [35]. Transmesenteric access to the portal vein has also been described. With this technique, a mini-laparotomy must first be performed to establish access to the mesenteric venous vasculature. This procedure is infrequently performed because of the higher risk of complications with this technique versus alternative approaches [32, 36, 37].

Transjugular Portosystemic Shunt Creation (TIPS Procedure)

TIPS placement remains an important adjunct therapy. It allows for management of symptomatic portal hypertension or salvage of liver transplant candidacy. Additionally, once the TIPS has

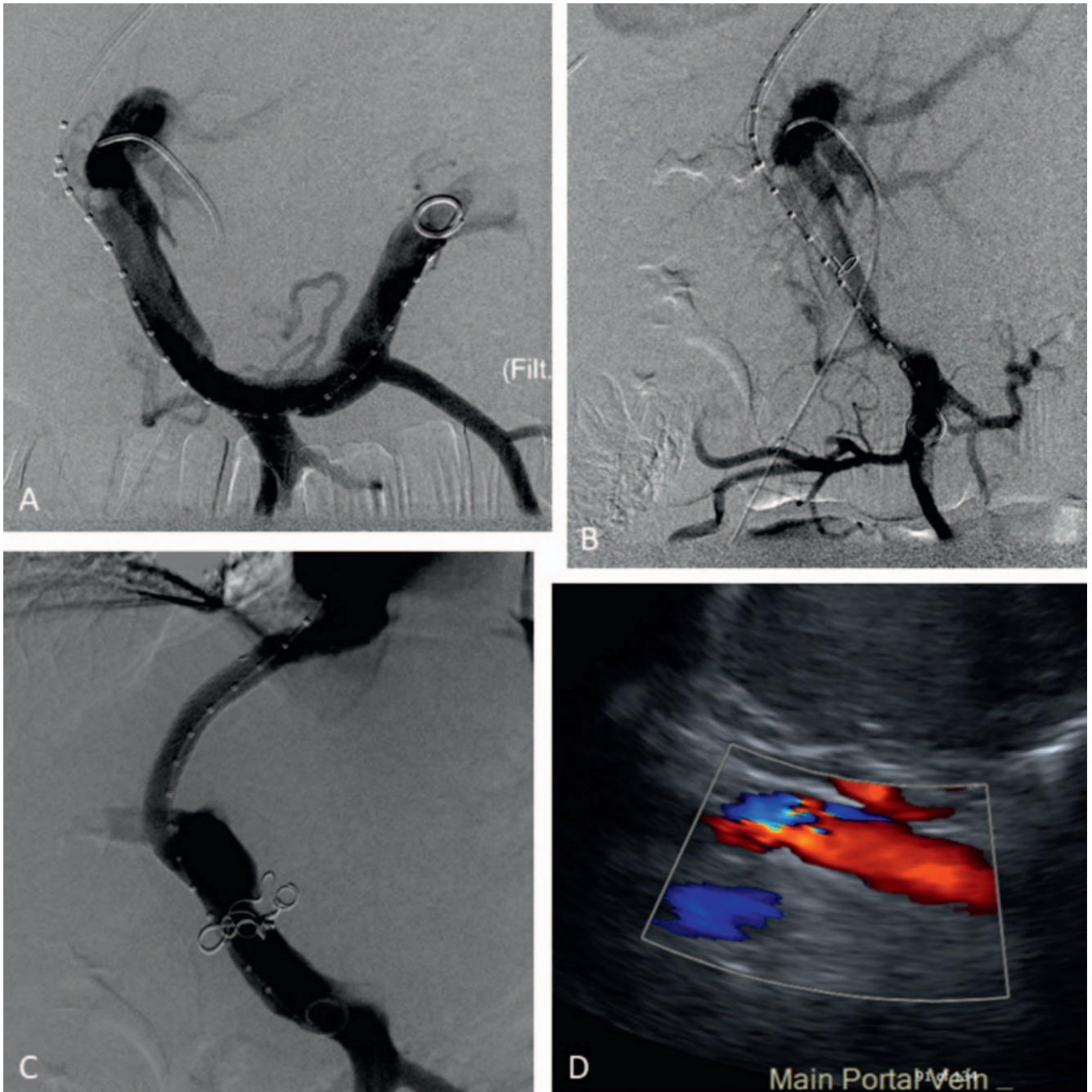
been placed, repeated thrombectomy procedures can be performed through the TIPS approach with relative ease of access into the portal venous system.

TIPS Placement in Cirrhotic Patients

In a study by Habib et al. [38], 11 patients with cirrhosis-induced chronic PVT underwent TIPS placement and portal vein recanalization (PVR). All 11 patients had improved portal flow, ranging from minor improvement to complete resolution (without further need of anticoagulation therapy), and 3 patients went on to undergo successful liver transplant. Similarly, in a study by Thornburg et al. [39], 24 of 61 patients with occlusive PVT went on to undergo successful transplant after PVR plus TIPS placement. In a recent systematic meta-analysis of 13 studies, TIPS placement was technically feasible in 95% of patients, with a pooled recanalization rate of 79% and a TIPS patency rate of 80% to 90% at 12 months [40]. Similarly, Valentin et al. [41] reported a pooled success rate of 86%. However, it is important to note that PVT was not an indication for TIPS placement in the majority of the included cases. Therefore, the success rate may be overestimated due to selection and reporting bias.

TIPS Placement in Noncirrhotic Patients

The use of TIPS placement in patients with PVT but without liver cirrhosis remains controversial. It is mainly reserved for patients with impending bowel ischemia and symptoms of portal hypertension or refractory thrombosis despite multiple interventions. Some studies have reported favorable outcomes in a small number of acute or acute-on-chronic noncirrhotic PVT patients requiring urgent intervention beyond systemic anticoagulation [42, 45]. In a recent study by Sun et al. [44], technical success was achieved in 20 out of 22 chronic noncirrhotic PVT patients. Notably, technical success was negatively affected by thrombus burden and presence of cavernous transformation of the portal vein. Similarly, in a study by Klinger et al. [45], 17 patients with chronic noncirrhotic,

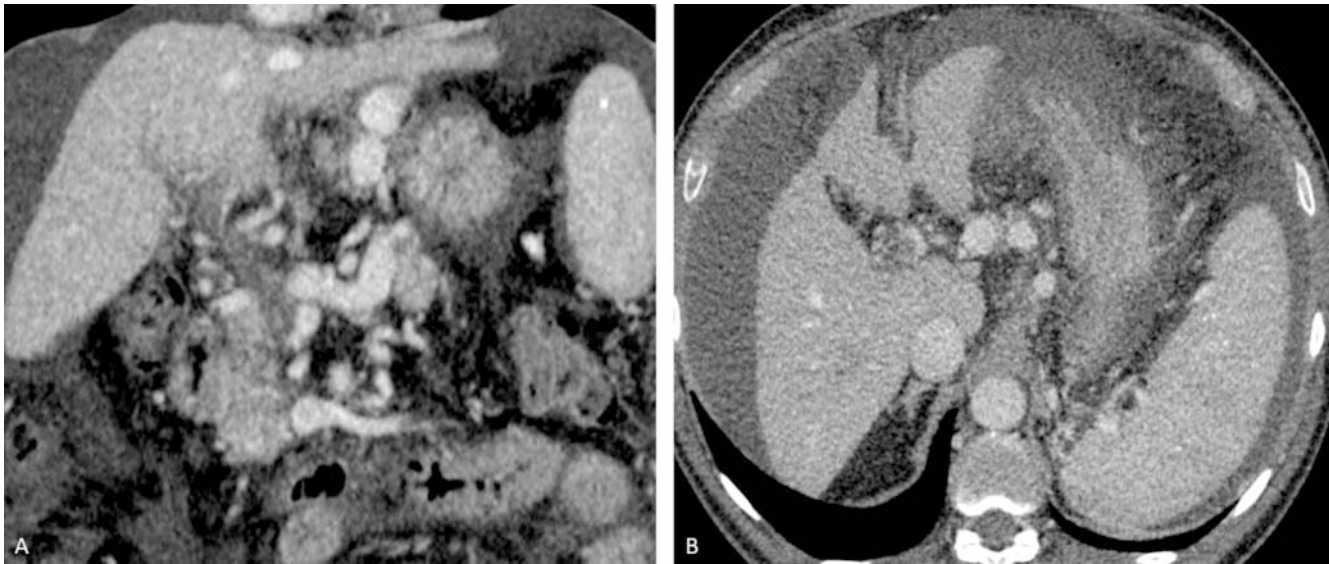


► **Fig. 4** Images from the same patient described in ► **Fig. 3**. **A, B** Splenoportal and portomesenteric venograms via the transjugular approach demonstrate a partially occlusive thrombus in the main portal and superior mesenteric veins and a completely occlusive thrombus in the right portal vein. **C** After mechanical thrombectomy and TIPS stent placement, complete resolution of the main portal vein thrombus can be seen. **D** At the 6-month follow-up, color Doppler ultrasound demonstrates a patent main portal vein without evidence of thrombus.

nonmalignant chronic PVT underwent PVR plus TIPS placement, and 76.5% of these patients had successful portal venous recanalization. At 1 and 2 years, the portal venous and TIPS patency rates were both 69.5%.

Limitations to the TIPS approach include the risk of worsening postprocedural hepatic encephalopathy or right heart failure and technical failure when a completely occluding thrombus is unable

to be traversed and catheterized via the transjugular access [14, 40]. Recently, a case series of 61 patients reported the novel use of a transsplenic approach to TIPS placement, which was found to be less technically challenging [33]. Based on our institutional experience, we use the transsplenic approach for chronic PVT recanalization but prefer the TIPS or percutaneous transhepatic approach for acute PVT cases.



► **Fig. 5** A 65-year-old man with nonalcoholic steatohepatic liver cirrhosis and chronic portal vein thrombosis with cavernous transformation of the portal vein presented to the emergency department with acute upper gastrointestinal bleeding from gastroesophageal varices. **A, B** Portal venous phase CT scans of the abdomen in the coronal and axial planes show a chronically occluded portal vein with cavernous transformation.

Thrombolysis

Endovascular thrombolysis using multihole infusion catheters can be performed when systemic anticoagulation alone is insufficient to restore portal venous flow. Similar to systemic anticoagulation, thrombolysis is contraindicated in patients with brain tumors, recent hemorrhagic stroke, and gastrointestinal bleeding [46]. In particular, when patients exhibit signs of irreversible gut ischemia or infarction and peritonitis, thrombolysis should not be pursued. Instead, surgical resection of the infarcted bowel is indicated in these clinical scenarios.

This procedure can be performed in two ways and is frequently performed in combination with other endovascular therapies, such as TIPS placement and mechanical thrombectomy. The transvenous method involves localized application of fibrinolytics, such as tissue plasminogen activator or heparin, directly into the portal venous thrombus. Thrombolysis can also be performed using ultrasound-accelerated infusion catheters such as the EKOS Infusion Catheter System (Boston Scientific). Acoustic microstreaming from ultrasound allows for transportation of the lytic agent directly to the site of the clot, with ultrasound pulses additionally disrupting the fibrin integrity of the thrombus [30]. Secondly, transarterial thrombolysis can be performed indirectly by catheterizing the superior mesenteric artery and infusing thrombolytic agents through the visceral arteries. In general, sole thrombolysis is not commonly performed for the treatment of PVT due to the low rates of complete resolution of thrombus. Thrombolysis typically achieves partial resolution only [47], and therefore it is beneficial to combine this technique with mechanical thrombectomy.

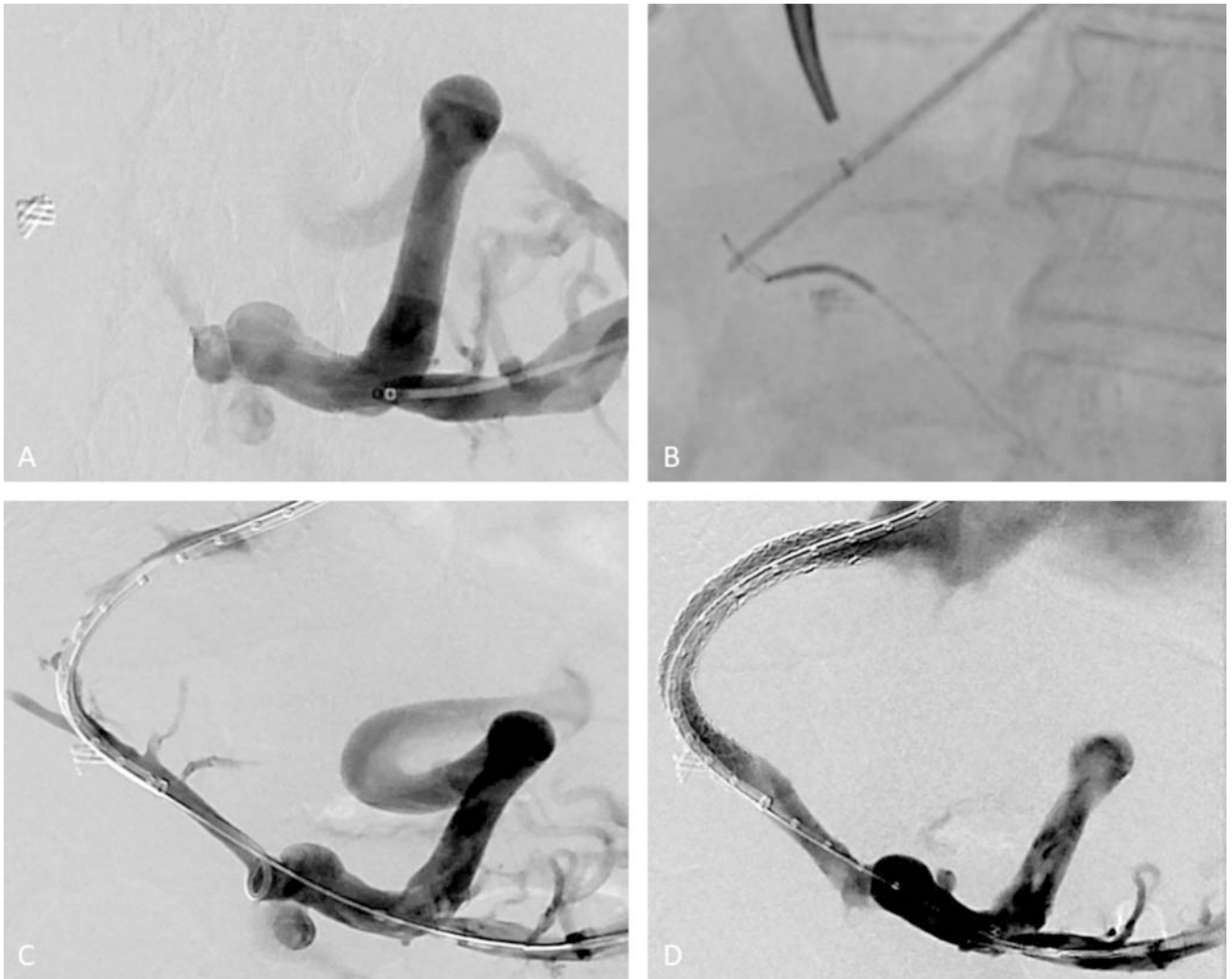
Data are lacking regarding the role of thrombolysis therapy in this setting. A recent meta-analysis by Cheng and Tree [48] demonstrated that the recanalization rate was 84% after thrombolysis with and without other endovascular therapies. The major compli-

cation rate was 7% and the overall complication rate was 25%. Given the small size of the patient sample, no direct comparison between the transvenous and transarterial methods was performed. Similar to other meta-analyses, the study results were negatively affected by heterogeneities in patient selection and treatments.

Mechanical Thrombectomy

Mechanical thrombectomy involves physical disruption of the thrombus and is often used in conjunction with systemic anticoagulation and endovascular thrombolysis when systemic anticoagulation is insufficient. One of the more commonly used devices in the portal venous system is the AngioJet system (Boston Scientific) [26]. This device uses a retrograde saline jet flow to generate a low-pressure system at the catheter tip, thereby creating a vacuum effect to aspirate the clot (Venturi-Bernoulli effect). Saline jets subsequently macerate the clot while delivering low-dose thrombolytics. Similar rheolytic devices include the Hydrolyser device (Cordis) and the Oasis thrombectomy catheter (Boston Scientific). Other devices use rotational components to mechanically fragment the clot without aspiration capabilities or concomitant delivery of local lytics. For instance, the Trellis Peripheral Infusion System (Covidien) uses spinning wires, whereas the Amplatz Thrombectomy Device (Microvena), Arrow-Trerotola PTD (Arrow International), and Cragg Brush (Microtherapeutics) use spinning impellers or brushes.

The efficacy of mechanical thrombectomy alone or in combination with other techniques has not been well-established in the literature. Despite high technical success rates noted in several case series using mechanical thrombectomy, the rates of re-thrombosis and the need for additional interventions remain high [49,51]. This risk of re-thrombosis is likely due to underlying prothrombotic disease processes that are not addressed during



► **Fig. 6** Images from the same patient described in Fig. 5. **A** Image demonstrates near-complete occlusion of the portal vein with a trace amount of contrast passing through. A large left gastric vein leads to the gastroesophageal variceal complex. **B** Image demonstrates successful recanalization of the main portal vein and placement of a snare as the target in the right portal vein for a TIPS procedure. **C** Portal venogram after balloon venoplasty of the main portal vein demonstrates hepatopetal flow. **D** Image demonstrates a patent main portal vein with brisk flow after TIPS placement.

catheter-directed therapy. Another hypothesis suggests that mechanical thrombectomy increases the risk of wall denudation and endothelial damage, further contributing to future thrombus formation [31]. Additionally, a limitation of mechanical thrombectomy is the risk of partial recanalization when the extent of the thrombus involves smaller branched vessels not amenable to access using the mechanical thrombectomy device.

Comparing safety profiles among thrombectomy devices is challenging, but two studies using animal models have attempted such an evaluation. One study compared the Akonya Eliminator Device and the Arrow-Terrotola percutaneous thrombolytic device in porcine models and found the latter device produced greater arterial injury on histology [52]. A second study in canine models found the Casteneda brush caused less arterial wall damage than the Arrow-Terrotola device and Fogarty embolectomy catheter, although all three devices demonstrated vascular wall

lesions extending into the tunica media [53]. Additional benchtop trials to evaluate the performance of these devices in vivo may help optimize future treatment planning. Our institutional experience with mechanical thrombectomy in the portal venous system has shown effective recanalization of the portal veins using the AngioJet system, which can be advanced over a 0.035-inch guide-wire.

Aspiration Thrombectomy

Aspiration thrombectomy is performed using a suction catheter that engages and extracts the portal vein thrombus. To date, no formal studies have reported outcomes of aspiration thrombectomy alone for the treatment of PVT specifically. The existing literature discusses institutional experiences using this approach in treating superior mesenteric vein thrombosis, so any extrapolation of reported success rates to PVT treatment is theoretical at

this point [54, 55]. However, the use of aspiration thrombectomy in conjunction with systemic anticoagulation or other endovascular interventions for the treatment of PVT has been reported [30, 56]. In addition to concerns regarding low recanalization rates with aspiration thrombectomy alone, this procedure is associated with blood volume loss because aspiration catheters are unable to replace the aspirated fluid once activated [57].

How and When to Use Endovascular Therapy

As mentioned previously, there is a paucity of high-quality data to guide a standardized clinical approach. Existing data are often derived from case series and small trials. Systemic reviews and meta-analyses are often plagued by patient and treatment heterogeneity. It is therefore of utmost importance to manage PVT in a multidisciplinary manner.

It is prudent to offer endovascular therapy as a second-line or adjunct therapy to anticoagulation. In cirrhotic patients with symptoms of portal hypertension in whom anticoagulation therapy has failed (defined as persistence or worsening symptoms after six months), TIPS placement combined with other endovascular techniques may serve as valuable adjunct therapies in managing chronic PVT, especially in pretransplant patients. In particular, cirrhotic patients should be considered for TIPS based on the severity of the portal hypertensive symptoms. The exact time of intervention is less clear in the literature but should be guided by local clinical expertise and clinical presentation, such as recurrent bleeding or developing bowel ischemia.

In noncirrhotic patients, endovascular therapy using thrombolysis and thrombectomy with or without TIPS placement may be a viable option to prevent acute and long-term sequelae, namely bowel ischemia and portal hypertensive symptoms. In the literature, impending bowel ischemia, manifested as either radiographic changes or new/worsening abdominal pain, has been listed as an indication for endovascular therapy along with acute variceal bleeding or impending bleed. The exact time point at which endovascular therapy is indicated is less clear but should be guided by local clinical expertise and clinical judgement to prevent impending bowel ischemia or bleed. However, the long-term efficacy of this strategy has not been validated and needs to be weighed against the increased risk of periprocedural bleeding. More studies are warranted to compare endovascular therapy to anticoagulation alone in managing PVT.

Thus far there has been no direct comparison between the different endovascular therapies, likely because of the low number of patients treated and the heterogeneity of underlying disease. Additionally, endovascular therapies are frequently used in various combinations (TIPS placement plus thrombectomy/thrombolysis) in clinical practice, which further complicates direct comparisons. Lastly, there are too few published case series and retrospective studies to provide meaningful comparisons. As the endovascular therapy approach gains in popularity, large patient cohorts should be available for analysis in the near future.

Conclusion

Current guidelines support the use of systemic anticoagulation for the treatment of acute PVT, but recommendations regarding interventional strategies have been vague. Despite several reports of the use of minimally invasive techniques for portal venous recanalization, no standardized approach has been accepted. This is likely related to the heterogeneity of this patient population. Although no formal recommendations can be made based on the limited evidence, it is clear that all interventions must be preceded by careful imaging evaluation of the degree of occlusion and the location, extension, and chronicity of the thrombus. These factors aid in determining whether a transjugular intrahepatic, percutaneous transhepatic, transsplenic, or transmesenteric approach is the most appropriate access into the portal venous system for endovascular interventions. Based on our institutional experience with acute PVT, a pharmacomechanical thrombectomy approach via TIPS placement is preferred whenever feasible. To date, there remains a paucity of literature comparing patient outcomes using these different techniques, and the optimal sequence of interventions has yet to be validated. Further investigation comparing outcomes such as in vivo recanalization rates, length of hospital stay, mortality, and thrombus recurrence rates is warranted to improve the delivery of care in this patient population.

Conflict of Interest

The authors declare that they have no conflict of interest.

Acknowledgement

We would like to thank Megan Griffiths for her contribution to the editing of the manuscript.

References

- [1] Ögren M, Bergqvist D, Björck M et al. Portal vein thrombosis: Prevalence, patient characteristics and lifetime risk: A population study based on 23796 consecutive autopsies. *World J Gastroenterol* 2006; 12: 2115–2119
- [2] Vairappan B. Endothelial dysfunction in cirrhosis: Role of inflammation and oxidative stress. *World J Hepatol* 2015; 7: 443–459
- [3] Hernandez-Gea V, De Gottardi A, Leebeek FWG et al. Current knowledge in pathophysiology and management of Budd-Chiari syndrome and non-cirrhotic non-tumoral splanchnic vein thrombosis. *J Hepatol* 2019; 71: 175–199
- [4] Iba T, Levy JH. Inflammation and thrombosis: roles of neutrophils, platelets and endothelial cells and their interactions in thrombus formation during sepsis. *J Thromb Haemost* 2018; 16: 231–241
- [5] Luca A, Caruso S, Milazzo M et al. Natural course of extrahepatic non-malignant partial portal vein thrombosis in patients with cirrhosis. *Radiology* 2012; 265: 124–132
- [6] Sogaard KK, Darvalics B, Horváth-Puhó E et al. Survival after splanchnic vein thrombosis: A 20-year nationwide cohort study. *Thromb Res* 2016; 141: 1–7
- [7] Hall TC, Garcea G, Metcalfe M et al. Management of acute non-cirrhotic and non-malignant portal vein thrombosis: A systematic review. *World J Surg* 2011; 35: 2510–2520

- [8] Harding DJ, Perera MT, Chen F et al. Portal vein thrombosis in cirrhosis: Controversies and latest developments. *World J Gastroenterol* 2015; 21: 6769–6784
- [9] Russell CE, Wadhwa RK, Piazza G. Mesenteric venous thrombosis. *Circulation* 2015; 131: 1599–1603
- [10] European Association for the Study of the Liver. EASL Clinical Practice Guidelines: Vascular diseases of the liver. *J Hepatol* 2016; 64: 179–202
- [11] Jha RC, Khera SS, Kalaria AD. Portal vein thrombosis: Imaging the spectrum of disease with an emphasis on MRI features. *Am J Roentgenol* 2018; 211: 14–24
- [12] Northup PG, Garcia-Pagan JC, Garcia-Tsao G et al. Vascular Liver Disorders, Portal Vein Thrombosis, and Procedural Bleeding in Patients With Liver Disease: 2020 Practice Guidance by the American Association for the Study of Liver Diseases. *Hepatology* 2021; 73: 366–413
- [13] Plessier A, Darwish-Murad S, Hernandez-Guerra M et al. Acute portal vein thrombosis unrelated to cirrhosis: A prospective multicenter follow-up study. *Hepatology* 2010; 51: 210–218
- [14] Chawla YK, Bodh V. Portal vein thrombosis. *J Clin Exp Hepatol* 2015; 5: 22–40
- [15] Qi X, De Stefano V, Li H et al. Anticoagulation for the treatment of portal vein thrombosis in liver cirrhosis: A systematic review and meta-analysis of observational studies. *Eur J Intern Med* 2015; 26: 23–29
- [16] DeLeve LD, Valla DC, Garcia-Tsao G. Vascular disorders of the liver. *Hepatology* 2009; 49: 1729–1764
- [17] Faccia M, Ainora ME, Ponziani FR et al. Portal vein thrombosis in cirrhosis: Why a well-known complication is still matter of debate. *World J Gastroenterol* 2019; 25: 4437–4451
- [18] Loffredo L, Pastori D, Farcomeni A et al. Effects of Anticoagulants in Patients With Cirrhosis and Portal Vein Thrombosis: A Systematic Review and Meta-analysis. *Gastroenterology* 2017; 153: 480–487.e1
- [19] Mohan BP, Aravamudan VM, Khan SR et al. Treatment responses and bleeding events associated with anticoagulant therapy of portal vein thrombosis in cirrhotic patients: systematic review and meta analysis. *Ann Gastroenterol* 2020; 35: 521–527
- [20] Naymagon L, Tremblay D, Zubizarreta N et al. The efficacy and safety of direct oral anticoagulants in noncirrhotic portal vein thrombosis. *Blood Adv* 2020; 4: 655–666
- [21] Senzolo M, Riva N, Dentali F et al. Long-Term Outcome of Splanchnic Vein Thrombosis in Cirrhosis. *Clin Transl Gastroenterol* 2018; 9: 176
- [22] Villa E, Cammà C, Marietta M et al. Enoxaparin prevents portal vein thrombosis and liver decompensation in patients with advanced cirrhosis. *Gastroenterology* 2012; 143: 1253–1260.e4
- [23] Cui SB, Shu RH, Yan SP et al. Efficacy and safety of anticoagulation therapy with different doses of enoxaparin for portal vein thrombosis in cirrhotic patients with hepatitis B. *Eur J Gastroenterol Hepatol* 2015; 27: 914–919
- [24] Delgado MG, Seijo S, Yepes I et al. Efficacy and safety of anticoagulation on patients with cirrhosis and portal vein thrombosis. *Clin Gastroenterol Hepatol* 2012; 10: 776–783
- [25] Maldonado TS, Blumberg SN, Sheth SU et al. Mesenteric vein thrombosis can be safely treated with anticoagulation but is associated with significant sequelae of portal hypertension. *J Vasc Surg Venous Lymphat Disord* 2016; 4: 400–406
- [26] Wolter K, Decker G, Kuetting D et al. Interventional Treatment of Acute Portal Vein Thrombosis. *Rofo* 2018; 190: 740–746
- [27] Gerwing M, Wilms C, Heinzow H et al. Escalating interventional recanalization therapy in non-cirrhotic, non-malignant acute portal vein thrombosis. *Eur J Gastroenterol Hepatol* 2019; 31: 1584–1591
- [28] Rossle M, Bettinger D, Trebicka J et al. A prospective, multicentre study in acute non-cirrhotic, non-malignant portal vein thrombosis: comparison of medical and interventional treatment. *Aliment Pharmacol Ther* 2020; 52: 329–339
- [29] Ramaswamy RS, Charalel R, Guevara CJ et al. Propensity-matched comparison of transjugular intrahepatic portosystemic shunt placement techniques: Intracardiac echocardiography (ICE) versus fluoroscopic guidance. *Clin Imaging* 2019; 57: 40–44
- [30] Abdel-Aal AK, Ezzeldin IB, Hamed MF et al. Endovascular treatment of acute portal vein thrombosis using ultrasound-accelerated catheter-directed thrombolysis. *Vasc Endovascular Surg* 2014; 48: 460–465
- [31] Uflacker R. Applications of percutaneous mechanical thrombectomy in transjugular intrahepatic portosystemic shunt and portal vein thrombosis. *Tech Vasc Interv Radiol* 2003; 6: 59–69
- [32] Qi X, Han G. Transjugular intrahepatic portosystemic shunt in the treatment of portal vein thrombosis: A critical review of literature. *Hepatol Int* 2012; 6: 576–590
- [33] Thornburg B, Desai K, Hickey R et al. Portal Vein Recanalization and Transjugular Intrahepatic Portosystemic Shunt Creation for Chronic Portal Vein Thrombosis: Technical Considerations. *Tech Vasc Interv Radiol* 2016; 19: 52–60
- [34] Tuite DJ, Rehman J, Davies MH et al. Percutaneous transsplenic access in the management of bleeding varices from chronic portal vein thrombosis. *J Vasc Interv Radiol* 2007; 18: 1571–1575
- [35] Haddad MM, Fleming CJ, Thompson SM et al. Comparison of Bleeding Complications between Transsplenic versus Transhepatic Access of the Portal Venous System. *J Vasc Interv Radiol* 2018; 29: 1383–1391
- [36] Farsad K, Zaman A. Percutaneous Transmesenteric Portal Vein Recanalization and Transjugular Direct Intrahepatic Portosystemic Shunt Creation for Chronic Portal Vein Occlusion. *J Vasc Interv Radiol* 2019; 30: 892–893
- [37] Matsui O, Yoshikawa J, Kadoya M et al. Transjugular intrahepatic portosystemic shunt after previous recanalization of a chronically thrombosed portal vein via a transmesenteric approach. *Cardiovasc Intervent Radiol* 1996; 19: 352–355
- [38] Habib A, Desai K, Hickey R et al. Portal vein recanalization–transjugular intrahepatic portosystemic shunt using the transsplenic approach to achieve transplant candidacy in patients with chronic portal vein thrombosis. *J Vasc Interv Radiol* 2015; 26: 499–506
- [39] Thornburg B, Desai K, Hickey R et al. Pretransplantation portal vein recanalization and transjugular intrahepatic portosystemic shunt creation for chronic portal vein thrombosis: final analysis of a 61-patient cohort. *J Vasc Interv Radiol* 2017; 28: 1714–1721.e2
- [40] Rodrigues SG, Sixt S, Abalde JG et al. Systematic review with meta-analysis: portal vein recanalisation and transjugular intrahepatic portosystemic shunt for portal vein thrombosis. *Aliment Pharmacol Ther* 2019; 49: 20–30
- [41] Valentin N, Korrapati P, Constantino J et al. The role of transjugular intrahepatic portosystemic shunt in the management of portal vein thrombosis: a systematic review and meta-analysis. *Eur J Gastroenterol Hepatol* 2018; 30: 1187–1193
- [42] Klinger C, Riecken B, Schmidt A et al. Transjugular local thrombolysis with/without TIPS in patients with acute non-cirrhotic, non-malignant portal vein thrombosis. *Dig Liver Dis* 2017; 49: 1345–1352
- [43] Bilbao JJ, Elorz M, Vivas I et al. Transjugular intrahepatic portosystemic shunt (TIPS) in the treatment of venous symptomatic chronic portal thrombosis in non-cirrhotic patients. *Cardiovasc Intervent Radiol* 2004; 27: 474–480
- [44] Sun XY, Wang GC, Wang J et al. Transjugular intrahepatic portosystemic shunt is effective in patients with chronic portal vein thrombosis and variceal bleeding. *Hepatobiliary Pancreat Dis Int* 2021; 20: 128–136
- [45] Klinger C, Riecken B, Schmidt A et al. Transjugular portal vein recanalization with creation of intrahepatic portosystemic shunt (PVR-TIPS) in patients with chronic non-cirrhotic, non-malignant portal vein thrombosis. *Z Gastroenterol* 2018; 56: 221–237
- [46] Tilsed JVT, Casamassima A, Kurihara H et al. ESTES guidelines: acute mesenteric ischaemia. *Eur J Trauma Emerg Surg* 2016; 42: 253–270

- [47] Hollingshead M, Burke CT, Mauro MA et al. Transcatheter thrombolytic therapy for acute mesenteric and portal vein thrombosis. *J Vasc Interv Radiol* 2005; 16: 651–661
- [48] Cheng Q, Tree K. Systematic Review of Thrombolysis Therapy in the Management of Non-Cirrhosis-Related Portal Vein Thrombosis. *J Gastrointest Surg* 2021. doi:10.1007/s11605-020-04624-4
- [49] Benmassaoud A, AlRubaiy L, Yu D et al. A stepwise thrombolysis regimen in the management of acute portal vein thrombosis in patients with evidence of intestinal ischaemia. *Aliment Pharmacol Ther* 2019; 50: 1049–1058
- [50] Jun KW, Kim MH, Park KM et al. Mechanical thrombectomy-assisted thrombolysis for acute symptomatic portal and superior mesenteric venous thrombosis. *Ann Surg Treat Res* 2014; 86: 334–341
- [51] Rosenqvist K, Barbier CE, Rorsman F et al. Treatment of acute portomesenteric venous thrombosis with thrombectomy through a transjugular intrahepatic portosystemic shunt: a single-center experience. *Acta Radiol* 2018; 59: 953–958
- [52] Kónya A, Choi BG, Van Pelt CS et al. Vascular injury caused by mechanical thrombectomy in porcine arteries: AKónya eliminator device versus Arrow-Treerotola percutaneous thrombolytic device. *J Vasc Interv Radiol* 2006; 17: 121–134
- [53] Castañeda F, Li R, Patel J et al. Comparison of three mechanical thrombus removal devices in thrombosed canine iliac arteries. *Radiology* 2001; 219: 153–156
- [54] Ferro C, Rossi UG, Bovio G et al. Transjugular intrahepatic portosystemic shunt, mechanical aspiration thrombectomy, and direct thrombolysis in the treatment of acute portal and superior mesenteric vein thrombosis. *Cardiovasc Intervent Radiol* 2007; 30: 1070–1074
- [55] Yang S, Liu B, Ding W et al. Acute superior mesenteric venous thrombosis: transcatheter thrombolysis and aspiration thrombectomy therapy by combined route of superior mesenteric vein and artery in eight patients. *Cardiovasc Intervent Radiol* 2015; 38: 88–99
- [56] Kennoki N, Saguchi T, Sano T et al. Successful recanalization of acute extensive portal vein thrombosis by aspiration thrombectomy and thrombolysis via an operatively placed mesenteric catheter: a case report. *BJR Case Rep* 2018; 4: 20180024
- [57] Zangan S, Funaki B. Thrombectomy devices. In: Mauro M, Murphy K, Thomson K, et al. eds. *Image-Guided Interventions*. 2nd ed. Philadelphia: Saunders; 2014: 58–66