

Endobronchial Ultrasound in Suspected Non-Malignant Mediastinal Lymphadenopathy

Endobronchialer Ultraschall bei nicht maligner mediastinaler Lymphadenopathie

Authors

L. Eickhoff¹, H. Golpon^{1,4}, P. Zardo², H. Suhling¹, T. Welte^{1,4}, D. Jonigk^{3,4}, J. Gottlieb^{1,4}, T. Fuehner^{1,4}

Institutions

- 1 Department of Respiratory Medicine, Medical School Hannover, Germany
- 2 Department of Cardiothoracic, Transplant and Vascular Surgery, Medical School Hannover, Germany
- 3 Institute of Pathology, Hannover Medical School, Germany
- 4 Biomedical Research in Endstage and Obstructive Lung Disease Hannover (BREATH), Member of the German Center for Lung Research (DZL), Hannover Medical School, Germany

received 23.12.2017

accepted after revision 27.2.2018

Bibliography

DOI <https://doi.org/10.1055/a-0583-0265>

Published online: 22.5.2018 | *Pneumologie* 2018; 72: 559–567

© Georg Thieme Verlag KG Stuttgart · New York
ISSN 0934-8387

Corresponding author

Linn Eickhoff, Dept. of Respiratory Medicine, Hannover Medical School, 30623 Hannover, Germany
linn.eickhoff@stud.mh-hannover.de

ABSTRACT

Background Endobronchial ultrasound (EBUS) bronchoscopy with transbronchial needle aspiration (TBNA) is a well-established tool in mediastinal staging in lung cancer and gains importance in exploration of non-malignant lymphadenopathy. The aim of this study was to evaluate the role of EBUS-TBNA in suspected non-malignant diseases.

Methods A retrospective, single-center, observation analysis of endobronchial ultrasound bronchoscopy procedures was performed in a university medical center between March 2013 and July 2015. All patients with suspected non-malignant mediastinal lymphadenopathy were includ-

ed. Cytopathological and microbiological results of EBUS were compared to clinical diagnosis 6 months after procedure and performance of EBUS was contrasted to malignant indications.

Results During study period, 333 EBUS bronchoscopies in 315 patients with mediastinal lymphadenopathy were performed. 111 out of 315 (35%) patients had neither primary signs nor history of a malignant disease, categorised as patients with suspected non-malignant disease. 245 lymph nodes were sampled (median size 15 mm [IQR10–19]). Preferred station for TBNA was lymph node station 7 (38%). Cytopathological findings revealed non-specific inflammation (n=81; 70%), carcinoma (n=7; 6%), epithelioid cell granulomas (n=20; 17%). 7 samples (6%) were non-representative. Microbiologic testing of lymph nodes identified 3 infections (Mycobacteria tuberculosis [n=2] and Nocardia nova [n=1]) relevant to antibiotic therapy. Minor adverse events were observed in 9 out of 115 (8%) patients. Sensitivity of EBUS-TBNA intervention in suspected non-malignant disease was 76% and specificity 96%.

Conclusions EBUS-TBNA revealed a specific cause for suspected non-malignant lymphadenopathy in one-third of cases and was associated with excellent specificity. Predominant specific causes were granuloma, besides from tumor. In 3 patients pathogen could be isolated by TBNA.

ZUSAMMENFASSUNG

Einführung Die endobronchiale ultraschallgestützte transbronchiale Nadelaspiration (EBUS-TBNA) ist eine gängige Methode zum mediastinalen Lymphknotenstaging bei Patienten mit Lungenkarzinom und gewinnt an Stellenwert in der Untersuchung von gutartigen Lungenerkrankungen. Das Ziel der Studie war es, den Stellenwert der EBUS-TBNA bei nicht maligner mediastinaler Lymphadenopathie zu prüfen.

Methodik Wir führten eine retrospektive, monozentrische Beobachtungsanalyse von EBUS-TBNA-Prozeduren in einem Universitätsklinikum zwischen März 2013 und Juli 2015 durch. Alle Patienten mit vermeintlich nicht maligner mediastinaler Lymphadenopathie wurden eingeschlossen.

Zytopathologische und mikrobiologische Ergebnisse der EBUS-TBNA Proben wurden 6 Monate nach der Untersuchung mit der klinischen Diagnose und malignen Indikationen verglichen.

Ergebnisse Während des Untersuchungszeitraumes wurden 333 EBUS-Bronchoskopien an 315 Patienten mit mediastinaler Lymphadenopathie durchgeführt. 111 von 315 (35%) Patienten hatten weder primäre Zeichen noch eine Anamnese für eine Tumorerkrankung. Die Patienten wurden kategorisiert als Patienten mit vermeintlich nicht maligner Erkrankung. 245 Lymphknoten wurden punktiert (mediane Größe 15 mm [IQR 10–19]). Die bevorzugte Position für TBNA war Lymphknotenstation 7 (38%). Zytopathologische Befunde ergaben unspezifische Entzündung (n=

81; 70%), Karzinom (n=7; 6%), epitheloidzellige Granulome (n=20; 17%). 7 Proben (6%) waren nicht repräsentativ. Die mikrobiologische Untersuchung der Lymphknotenpunkate wiesen 3 behandelbare Infektionen (*Mycobacterium tuberculosis* [n=2] und *Nocardia nova* [n=1]) nach. Leichtgradige Komplikationen wurden bei 9 von 115 (8%) Patienten beobachtet. Die Sensitivität der EBUS-TBNA Untersuchung bei vermeintlich nicht maligner Lymphadenopathie lag bei 76%, bei einer Spezifität bei 96%.

Zusammenfassung In einem Drittel der Fälle ergab die EBUS-TBNA spezifische Ursachen für vermeintlich nicht maligne Lymphadenopathie. Häufigster Nachweis waren Granulome, gefolgt von Tumorerkrankung. Bei 3 Patienten konnten Erreger aus dem TBNA-Material isoliert werden.

Introduction

Endobronchial ultrasound is a minimally invasive technique to obtain tissue via ultrasonic bronchoscope to visualise and perform a real-time transbronchial needle aspiration under direct endobronchial ultrasonographic guidance [1, 2].

Endobronchial ultrasonography with transbronchial needle aspiration is an established tool in mediastinal staging [3–5]. Apart from diagnosis of lung cancer, EBUS is appealing to physicians interested in diagnosis of other pathologies in the mediastinum, including malignancies despite lung cancer or non-malignant diseases like lymph node tuberculosis or sarcoidosis [6–9].

Compared to invasive surgical techniques such as mediastinoscopy, EBUS-TBNA appears to be safer and less expensive, with high specificity for identifying mediastinal lung cancer [10].

Solitary use of imaging methods in cancer patients, like conventional contrast enhanced computed tomography (CT) or positron emission tomography (PET) lacks accuracy and histopathological proof [11]. Originally, EBUS-TBNA was performed with a 22 gauge (22G) needle. The benefit from larger units such as the 21G needle or forceps has been discussed [12]. The impact of EBUS-TBNA as an integrated tool in the observation of non-malignant lymphadenopathies is rising, but less apparent than in diagnosis of malignant diseases.

In stage I/II sarcoidosis, EBUS-TBNA was associated with a sensitivity and accuracy of approximately 80% [13].

EBUS-TBNA demonstrated high specificity of 100% and accuracy of 91% and was recommended as a safe and well tolerated procedure in tuberculosis [9].

In lymphoma patients, EBUS-TBNA may differentiate lymphoma relapse in the mediastinum from alternative pathologies and may therefore prevent surgical biopsies in most such patients [14].

As a further diagnostic advantage besides the cytopathological evaluation of the obtained specimens by EBUS-TBNA, additional microbiological testing was implemented in specific cases in this study. In previous studies, a modification of sampling techniques was recommended and more sensitive detec-

tion methods may be required for routine microbiological tests on EBUS-TBNA to gain a sufficient level of sensitivity and to rule out infectious causes of lymphadenopathy [15].

The aim of this study was to ascertain the diagnostic yield of EBUS-TBNA with cytopathological and microbiological testing in the diagnosis of non-malignant lymphadenopathy. Secondary endpoints included quality and safety of the procedure.

Material and Methods

Study design

A retrospective, single-centre, observation analysis of all endoscopic ultrasound bronchoscopy procedures was performed in a university medical centre between 12/03/2013 and 29/07/2015. Primary endpoint was the sensitivity of EBUS diagnosis on the basis of the final diagnosis 6 months after the procedure. Secondary endpoints included risk factors related to the development of complications.

The study adhered to ethical guidelines of the 1975 Declaration of Helsinki and was performed with the approval of the Ethics Committee of Hannover Medical School (Number: 2565–2015).

Patients

All patients referred to the bronchoscopy unit of the Department of Respiratory Medicine for EBUS-TBNA between 12/03/2013–29/07/2015 were included.

All patients underwent computed tomography (some of them as PET fusion CT) generally a maximum of 3 months prior to EBUS-TBNA.

Non-malignant indications for EBUS-TBNA were retrospectively divided from suspected malignant disease by the EBUS performing pulmonologists.

Suspected non-malignant mediastinal lymphadenopathy was defined by lack of a known or suspected malignancy. Patients were categorized in the non-malignancy group when they had exclusively mediastinal lymphadenopathy over 5 mm in diameter or PET-positive lymph nodes. Presence of lung parenchymal mass, primary tumour signs or history of or current

malignant disease were exclusion criteria. Malignancy was suspected if patients with mediastinal lymphadenopathy and PET-positive lymph nodes had any history of malignancies or tumour signs on pulmonary imaging based on the Fleischner guidelines for solid and subsolid nodules [16, 17].

Procedure

Every EBUS procedure was performed in conscious sedation via the nasal or oral route by experienced pulmonologists. One bronchoscopist performed the procedure, while another performed needle puncture and specimen preparation.

During the study period, four pulmonologists performed EBUS-TBNA (TF, JG, MG, HS). The EBUS procedure was performed using a convex probe ultrasound bronchoscope, designed for lymph node staging with a 2.2mm instrumental channel (Olympus® BF-UC180F). All lymph node needle aspirations were performed with single use 22G needle (NA-201SX-4022, Olympus®).

Prior to procedure, lidocaine was administered for anaesthesia of upper airway and minimizing cough. Midazolam and propofol were given intravenously for adequate sedation. Pulse, blood pressure, respiratory rate and pulse oxymetric saturation were monitored.

A flexible videoscope (Olympus, Tokyo, Japan; Type P180, Q180, T180) was inserted and topical lidocaine was administered to trachea and bronchus. Areas with suspicious mucosal changes were biopsied on conventional bronchoscopy and material sent to pathology. Lower respiratory tract samples were collected and sent to microbiology and/or cytopathology.

After initial exploration of the bronchial tree by conventional video bronchoscopy, EBUS was performed to visualise suspicious lymph nodes/pulmonary mass previously identified in computed tomographic or positron emission tomographic images. Lymph node stations were described by region, the lymph nodes were classified by size and appearance and documented [18]. All lymph node stations accessible by EBUS were screened (anterior and superior mediastinum: stations 1, 2, 3, 4, and station 7; intrapulmonary: stations 10, 11, and 12) [19].

After identification of suspicious lymph nodes/pulmonary mass (short axis diameter >5mm positive on thoracic CT scan or PET) on endobronchial ultrasound pictures, the transbronchial needle was inserted under direct EBUS guidance. On average, we performed 3 needle passages per lymph node/mass with 15–20 needle excursions according to recent recommendations [20]. Sampling was performed using the dry suction technique, applying negative pressure suction on the proximal end of the needle after the stylet is removed with a pre-vacuum syringe. The aspirate was collected and smeared onto glass. The smear was alcohol-fixed and underwent Papanheim staining and, depending on medical questions, also other stains (Periodic-acid-Schiff (PAS), Ziehl-Neelsen etc). No rapid-onsite cytology evaluation (ROSE) was performed.

Residual materials were preserved for subsequent cell block preparation, using the Gauting protocol [21]. Additional material was collected in normal saline for microbiological testing where clinically indicated.

Definition of diagnosis

Based on cytopathological findings of EBUS-TBNA aspirates, clinical diagnoses on hospital discharge (including results of bronchoalveolar lavage (BAL) and biopsy on conventional bronchoscopy) and six months after the procedure, the following diagnoses were made: bronchial carcinoma (tumour cells with pulmonary origin, with or without other signs of malignancy, such as necrosis and inflammation), other malignant disease (detected tumour cells with origin other than pulmonary, with or without other signs of malignancy, such as necrosis and inflammation), sarcoidosis (epithelioid non-caseating granulomas without necrosis) and mycobacterial infection (evidence of acid-fast bacterial infection and epithelioid granulomas, with or without necrosis or solely detected necrosis). Results were considered as reactive lymphadenopathy when inflammatory cells, such as lymphocytes or granulocytes, were detected, without presence of malignant cells or granulomas.

Absence of lymphocytes defines an inadequate sample.

Material was considered adequate if lymphocytes were detected or if definite diagnosis was achieved.

Statistical Analysis

Statistical analysis was performed using IBM SPSS Statistics version 22. Data were presented as medians (with 25th and 75th percentiles). Differences between groups were compared univariately using the Mann-Whitney U test, Fisher's exact test or Pearson's Chi-square test as appropriate. Pathological and microbiological results were reviewed and compared to final diagnosis based on clinical/radiological follow-up. A positive cytological result was usually accepted as evidence, and the patients were treated accordingly. The sensitivity, specificity, and accuracy were calculated using the standard definitions. Statistically significant differences were determined using Chi² for categorical variables and the t-test for independent samples for metric variables. A p-value of <0.05 or less was considered as significant.

Results

Patient characteristics

Within the study period, 315 patients underwent 333 endobronchial ultrasound-guided fine-needle aspirations (191 men, 124 women; median age 63 years, IQR (interquartile range) 54–71, range 10 to 84 years). (► **Table 1**). EBUS-TBNA was performed in 111 patients with suspected non-malignant outcome, and in 204 patients with malignant diseases (152 with suspected lung cancer and in 52 with suspected malignant disease other than lung cancer). Malignant results were included to preserve comparability and quality assurance.

In the suspected non-malignant group, a lower percentage (19%, n=21) of patients were current smokers and, in contrast to patients with suspected malignant disease, generally younger. Frequent comorbidities are shown in ► **Table 1**, in case of sarcoidosis as comorbidity EBUS-TBNA was performed for conformational purposes, when previous diagnosis was based on other methods or for exclusion of another disease.

► **Table 1** Patient characteristics.

Indication	total	“non-malignant disease”	“malignant disease”	p-value
	315 (100)	111 (100)	204 (100)	
Gender, n (%)				
Male	191 (61)	57 (51)	134 (66)	0.013
Age, median (IQR)	63 (54–71)	56 (45–65)	66 (56–72)	0.04
Smoking, n (%)	99 (31)	21 (19)	78 (38)	<0.001
Long-term oxygen therapy, n (%)	7 (2)	2 (2)	5 (2)	0.709
Comorbidities, n (%)				
COPD	74 (23)	17 (14)	57 (29)	0.003
Congestive heart failure	18 (6)	8 (7)	10 (5)	0.4
Lung transplantation	15 (5)	13 (12)	2 (1)	<0.001
Sarcoidosis	3 (1)	3 (3)	0 (0)	0.018
Pulmonary hypertension (PAPm ≥ 25 mmHg)	15 (5)	11 (10)	4 (2)	0.002
Interstitial lung disease	3 (1)	3 (3)	0 (0)	0.018

Data are shown as no. (%) or median (interquartile range).

Details of procedure and lymph nodes are shown in ► **Table 2** and ► **Fig. 1**. Preferred lymph node stations of a total of 245 lymph node biopsies in 111 patients were station 7, n = 93 (38%), 11 L (left), n = 55 (22%) and 4 R (right), n = 32 (13%).

Adverse events

Significant bleeding (≥ 50 ml) (n = 4, 3%) and oxygen desaturation (< 90%) (n = 5, 4%) were reported as adverse events (AE). All AEs could be managed in the bronchoscopy suite.

Microbiological results

Microbiological testing was performed when occurred infection was considered possible (signs of inflammation, increased inflammatory values in the blood) and was conducted on 73 lymph nodes, resulting in 52 positive cultures. The most common pathogens found were *Streptococcus* species (sp.) and *Staphylococcus* sp. (n = 56), followed by *Veillonella* sp. (n = 9).

Relevant infections (*Mycobacteria tuberculosis*, *Nocardia nova*), as defined by according treatment following the procedure, were found in three cases. Other organisms and non-respiratory pathogens were considered as contaminants.

Microbiological testing of bronchoalveolar lavage and collected bronchial secretions was performed in 97 patients and revealed positive bacterial colonisation in 52 cases. In 9 out of 52 cases, lower respiratory tract samples and lymph node samples revealed an identical pathogen.

Diagnostic yield

The clinical diagnosis on hospital discharge and the final diagnosis after 6 months of follow-up are shown in ► **Table 3**.

The calculated sensitivity, specificity, accuracy, positive predictive value (PPV) and negative predictive value (NPV) after EBUS examination in the “non-malignant” group (n = 115) were 76%, 96%, 87%, 95% and 83%.

18 cases had sarcoidosis, ten cases had malignant diagnosis, and five had mycobacterial infection. In addition, there was one cyst formation and one case of *Nocardia* infection. (► **Fig. 1**)

In our study, sensitivity of sarcoidosis was 72% in the “non-malignant” group and accuracy 93%.

In our study, unfortunately, in 7 patients with a later diagnosis of sarcoidosis during follow-up, the EBUS-TBNA result was considered as reactive lymph nodal enlargement (cytopathological testing showed lymphocytes). 3 of the patients received additional (definite) diagnosis by surgical lymph node sampling or CT-guided lymph node sampling. In the other 4 cases, diagnosis of sarcoidosis was made by other methods.

In five out of seven patients with tuberculosis, diagnosis could be made by EBUS-TBNA (sensitivity = 71%, accuracy = 98%). In 3 patients cytopathological testing was positive for mycobacterium (epithelioid granulomatous reaction and caseous necrosis), microbiological testing of lymph node was negative. In two out of three cytopathological-positive patients microbiological testing of BAL showed positive results for *Mycobacterium tuberculosis*. In the remaining cytopathological-positive patient tuberculosis infection had previously been reported. 2 cases were diagnosed by microbiological detection of acid-fast *Mycobacterium tuberculosis* in the lymph nodes. In 2 cases, EBUS-TBNA was inconclusive and failed to make the final diagnosis of tuberculosis.

► **Table 2** Intervention, lymph node characteristics and safety.

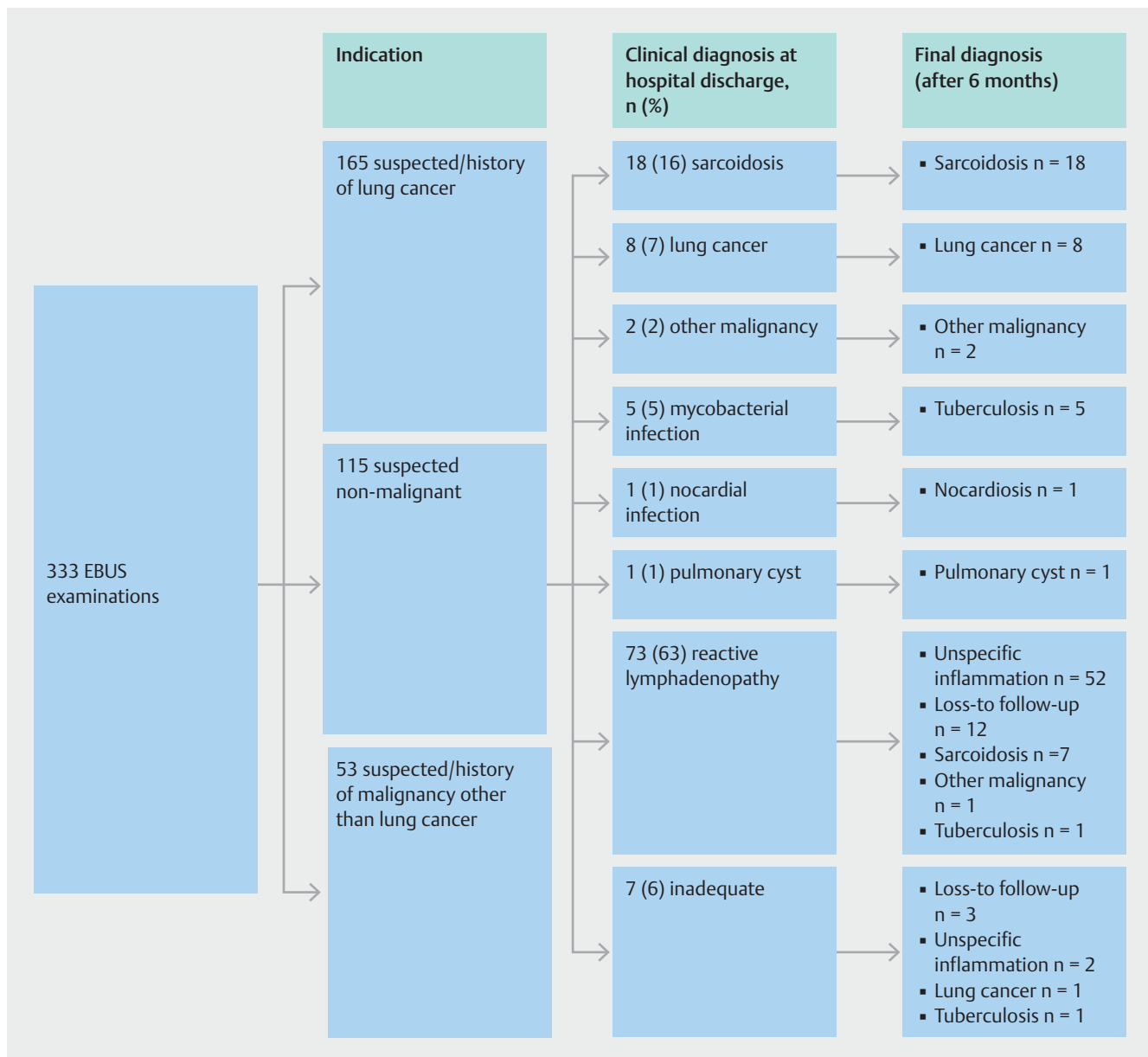
Variables	total	“non-malignant”	“malignant”	P-value
	(333)	(115)	(218)	
Bronchoscopy duration (min), median (IQR)	30 (25–38)	28 (21–36)	32 (26–39)	0.556
Sedation				
Midazolam alone, n (%)	32 (10)	16 (14)	16 (7)	0.055
Propofol, n (%)	295 (89)	96 (83)	199 (91)	0.018
Mean Midazolam dose, i. v. (mg)	3 (3–4)	3 (3–4)	3 (3–4)	0.029
Mean Propofol dose, i. v. (mg)	180 (120–250)	180 (135–255)	170 (120–243)	0.998
Diameter of largest LN (mm), median (IQR)	15 (10–20)	15 (10–19)	15 (11–20)	0.07
Number of examined LN per patient, median (IQR)	2 (1–2)	2 (1–2)	2 (1–2)	0.809
Number of LN-biopsies per patient, median (IQR)	5 (4–7)	5 (4–6)	5 (4–7)	0.108
Number of LN-biopsies per LN, median (IQR)	3 (2–4)	3 (2–4)	3 (2–3)	0.281
Adverse events, n (%)	36 (11)	9 (8)	27 (12)	0.297
Significant bleeding (≥50 ml)	22 (7)	4 (3)	18 (8)	0.095
Oxygen desaturation <90 %	13 (4)	5 (4)	8 (4)	0.761
Cardiac arrhythmia	1 (0)	0 (0)	1 (0)	0.467

Data are shown as No. (%) or median (interquartile range). LN: lymph node

► **Table 3** Results.

Indication	total	“no malignancy”	“malignancy”
Clinical diagnosis on hospital discharge	333	115 (35)	218 (65)
Lung cancer	124 (37)	8 (7)	116 (53)
Other malignant disease	22 (7)	2 (2)	20 (9)
Sarcoidosis	23 (7)	18 (16)	5 (2)
Mycobacteria	8 (2)	5 (4)	3 (1)
Pulmonary cyst	3 (1)	1 (1)	2 (1)
Nocardia nova	1 (0)	1 (1)	0 (0)
Reactive Lymphadenopathy	134 (40)	73 (63)	61 (28)
Inadequate sample	18 (5)	7 (6)	11 (5)
Final diagnosis follow-up 6 months			
Lung cancer	141 (42)	9 (8)	132 (61)
Other malignant disease	35 (11)	3 (3)	32 (15)
Sarcoidosis	30 (9)	25 (22)	5 (2)
Mycobacteria	13 (4)	7 (6)	6 (3)
Benign/pulmonary cyst	3 (1)	1 (1)	2 (1)
Nocardiosis	1 (0)	1 (1)	0 (0)
Non-specific inflammation	85 (26)	54 (47)	31 (14)
Loss to follow-up	25 (8)	15 (13)	10 (5)

Data are shown as no. (%).



► **Fig. 1** Clinical diagnosis on hospital discharge and final diagnosis after 6-month follow-up. Data shown as no. (%).

The single case in our study with a positive microbiological result of *Nocardia nova* in the lymph node examination had pulmonary infiltrates and inflammatory signs in the cytopathological diagnosis of lymph nodes. BAL was performed, but culture remained negative. The patient was suffering from iatrogenic Cushing's syndrome, which resulted in steroid-induced diabetes mellitus. Both conditions could be predisposing factors for *Nocardia* infection [22].

There was one cyst formation finally diagnosed by thoracotomy, in which cytopathological examination of the EBUS-TBNA aspirate showed lack of lymphocytes with suspicion of a cyst and inflammatory cells (lymphocytes, granulocytes and alveolar macrophages).

Sensitivity of malignancy in the "non-malignant" group was 83%; in two out of twelve cases, EBUS-TBNA did not result in the diagnosis of cancer.

Discussion

EBUS-TBNA is a useful tool in the diagnostic work-up of lymphadenopathy in general and besides suspicion of cancer disease. Apart from histopathological analysis of specimens, additional microbiological testing of EBUS-TBNA should be performed in the work-up of suspected non-malignant diseases.

With a sensitivity of 76% and specificity of 96% in patients with suspected non-malignant conditions and no severe adverse events present, EBUS-TBNA appears to be a safe and accu-

rate method for the evaluation of cytopathological changes in lymph nodes and the identification of lymph node microbiological infection.

Non-diagnostic results should be controlled by follow-up.

In the diagnosis and staging of lung cancer, EBUS-TBNA is a well-established tool in contrast to its value in non-malignant diseases [23]. Recent publications with a focus on diagnostics of malignancy reported a similar sensitivity but higher specificity (sensitivity and specificity ranging from 80–95% and specificities 98–100%) compared to our results [24–27]. For quality assurance reasons, data from suspected malignant disease was included in our study. The “malignant” group’s sensitivity was 82% and specificity 97%, showing a higher sensitivity and specificity compared to the “non-malignant” group. Another recent study describes higher sensitivity in the diagnosis of malignant diseases than benign diseases (92.6% vs. 89.7%) [4].

In sarcoidosis, EBUS-TBNA in mediastinal lymphadenopathy is established and studies recommend EBUS-TBNA in combination with standard bronchoscopy as a first-line examination [28,29]. In our study, sensitivity of sarcoidosis was 72% in “non-malignant” group and accuracy 93%. 17/25 patients were diagnosed by EBUS-TBNA alone (sensitivity of 68%), there was one additional case of sarcoidosis detected by endobronchial biopsy (EBB). A meta-analysis by Agarwal et al. showed a pooled sensitivity of 78% [30]. A similar result is seen in a granuloma trial, which confirmed EBUS-TBNA with a sensitivity of 74% to be preferred over conventional biopsies in the diagnosis of granulomas [31].

Caglayan et al. stated that sensitivity depends on the experience of the operator, stage of sarcoidosis (higher in Stage II than in Stage I) and the number of lymph nodes examined (single lymph node station: 72.7% for single lymph node station to 85.3% for examination of more than one lymph node). This study describes a higher overall sensitivity for granulomatous mediastinal lymphadenopathy (81%) [32].

For tuberculosis, in our study sensitivity revealed 71%, with an accuracy of 98%.

In the diagnosis of tuberculosis, EBUS-TBNA is considered to be the method of choice, as a safe procedure with a high diagnostic yield [33]. Previous studies describe a composite microbiological and clinicopathological diagnosis of 69% to 86% in TB-endemic countries [7,34].

There was one *Nocardia nova* infection, which was solely detected in lymph node aspirate and not in BAL/secretion. To the best of our knowledge, this is the first study describing *Nocardia nova* infection in lymph nodes in an immunocompromised patient. *Nocardia* infections are usually found as an opportunistic infection in immunocompromised patients, but in one third it can occur in immunocompetent patients. When isolated from the respiratory tract, it should not be regarded as a contaminant. Occasionally it may be identified from the respiratory tract without apparent pulmonary infection [35].

Relevance of *Nocardia nova* isolated in mediastinal lymph nodes remains unspecified.

Recent publications described the utilisation of EBUS-TBNA as a safe and accurate tool even in immunocompromised conditions for the identification of associated diseases such as pul-

monary mycoses/*Cryptococcus*, as well as *Nocardia* infection (*N. asteroides*, *N. beijingensis* and *N. arthritidis*) [36–38].

One case of mediastinal cyst formation, already suspected by EBUS-TBNA and confirmed by thoracotomy, was present in the “non-malignant” group. Mostly cysts are asymptomatic, but they can also be infectious and show symptoms.

For exclusion of malignancy, surgical methods are often recommended in the treatment of mediastinal cyst formation, although related with higher complication risks. However, via EBUS, it is possible to drain the cysts more safely, to explore the diagnosis of mediastinal structure [39]. Other publications state that drainage of cysts by EBUS-TBNA is related to a higher risk of infectious mediastinitis compared to the aspiration of lymph nodes [40–41].

In the case of microbiological testing, our findings showed relevant pathogens solely in the lymph nodes in two out of three cases, not being detected in patient’s secretions (gathered by bronchial lavage), may point to the importance of routine microbiological testing.

Despite this fact, due to frequent bacterial contamination and inadequate sensitivity, other publications suggest that routine microbiological testing is being reserved for populations with higher probability for *Mycobacterium tuberculosis*, *Mycobacterium avium* infection or endemic fungal infections [15].

In the “malignant” group, microbiological evaluation of biopsies and lower respiratory tract samples showed acid-fast bacilli in three cases. Two cases of non-tuberculous infections (*M. Kansaii*, *M. avium*) were detected, in addition to one *Mycobacterium tuberculosis* infection.

Limitations

Several limitations of our study should be noted.

This is a retrospective, single institution, non-randomised study, with a previous selection of patients into two groups (malignant vs non-malignant). The group-classification of each patient was made by the EBUS team of four experienced pulmonologists retrospectively. With this subjective assigning selection biases are possible to arise.

The decision to undertake EBUS-TBNA was at the discretion of the referring physician; the referral may vary or be related to patient preferences introducing selection biases as well.

There was no pre-selection of suitable cases, and examinations were conducted in routine practice.

The study size was not formally calculated, but is greater than other comparable studies [42,43].

All patients referred consecutively for investigation of mediastinal lymphadenopathy were included in the study and only 6% of examinations were not representative. Depending on examination conditions, the operator’s experience and artefactual changes (for example due to transport time), the quality of examination result differs [44,45].

The follow-up period was defined to be 6 months after procedure and based on clinical/radiological diagnosis. In our retrospective study we count 25 cases in total which are lost during follow-up, most cases (n=15) in the “non-malignant” group, which could be explained by non-necessity of Re-EBUS-

TBNA or other diagnostic method in the case of negative EBUS-TBNA results.

Persistence of diagnosis during this period of time is not always ensured due to the fact that benign lymphadenopathy shows progression at times. For example, can a sarcoidosis become inactive, reactive lymphadenopathy can be a precursor of a developing disease or disappear without treatment. Significant differences between clinical diagnosis on hospital discharge and follow-up were seen in the diagnosis of sarcoidosis and tuberculosis. Due to the histopathological heterogeneity of non-malignant diseases, compared to typical malignant pathological findings, often further diagnosis is needed to make the final diagnosis.

Outlook

As a minimally invasive technique, only a small sample size can be collected by EBUS-TBNA. In our study, preparation of cell blocks was performed to improve the quality of diagnostic material of remaining cytology. It showed a slightly larger number of representative results (86% compared to 85% of smear results).

Collection of larger tissue samples might be relevant to overcome low sample adequacy. Studies have reported a better diagnostic yield by using mini-forceps rather than a 21G needle, and no difference in adequacy between 21G and 22G needles [46, 47]. Statistical superiority of mini-forceps compared to conventional TBNA by 22G needle have also been reported by Herth et al. in diagnosis of lymphoma and sarcoidosis [48].

A study of Shiu et al. stated a higher diagnostic yield of a 19G needle compared to a 22G needle, at least in the examination of lymph nodes in non-cancer patients [49].

These results highlight the relevance of larger tissue size in order to improve diagnostic outcome in non-malignant diseases.

CONCLUSIONS

This study demonstrates actual diagnosis in a population in which malignancy is not previously expected and against expectations it shows a significant number of malignant results in the end. This assumes EBUS-TBNA to be a useful tool in diagnosing lymphadenopathy other than from suspected underlying cancer disease. The calculated low NPV shows that patients with EBUS-negative lymphadenopathy need careful follow-up. Particularly in the case of sarcoidosis and tuberculosis, confirmation by other methods might be indicated. Its role in diagnosing infections has to be further evaluated.

Conflict of interest

No conflict of interest has been declared by the authors.

References

- [1] Ye T, Hu H, Luo X et al. The role of endobronchial ultrasound guided transbronchial needle aspiration (EBUS-TBNA) for qualitative diagnosis of mediastinal and hilar lymphadenopathy: a prospective analysis. *BMC Cancer* 2011; 11: doi:10.1186/1471-2407-11-100
- [2] Tournoy KG, Govaerts E, Malfait T et al. Endobronchial ultrasound-guided transbronchial needle biopsy for M1 staging of extrathoracic malignancies. *Ann Oncol* 2011; 22: 127–131
- [3] Sun J, Bao L, Teng J et al. Endobronchial Ultrasound-guided Transbronchial Needle Aspiration in the Diagnosis of Intrathoracic Metastasis from Extrapulmonary Malignancy. *Zhongguo Fei Ai Za Zhi* 2015; 18: 295–300
- [4] Ortakoylu MG, Iliaz S, Bahadir A et al. Diagnostic value of endobronchial ultrasound-guided transbronchial needle aspiration in various lung diseases. *J Bras Pneumol* 2015; 41: 410–414
- [5] Caglayan B, Salepci B, Dogusoy I et al. The role of convex probe endobronchial ultrasound guided transbronchial needle aspiration in the diagnosis of malignant mediastinal and hilar lymph nodes. *Iran J Radiol* 2012; 9: 183–189
- [6] Ribeiro C, Oliveira A, Neves S et al. Diagnosis of sarcoidosis in the endobronchial ultrasound-guided transbronchial needle aspiration era. *Rev Port Pneumol* 2014; 20: 237–241
- [7] Low SY, Koh MS, Ong TH et al. Use of endobronchial ultrasound-guided transbronchial needle aspiration (EBUS-TBNA) in the diagnosis of granulomatous mediastinal lymphadenopathy. *Ann Acad Med Singapore* 2014; 43: 250–254
- [8] Kiral N, Caglayan B, Salepci B et al. Endobronchial ultrasound-guided transbronchial needle aspiration in diagnosing intrathoracic tuberculous lymphadenitis. *Med Ultrason* 2015; 17: 333–338
- [9] Geake J, Hammerschlag G, Nguyen P et al. Utility of EBUS-TBNA for diagnosis of mediastinal tuberculous lymphadenitis: a multicentre Australian experience. *J Thorac Dis* 2015; 7: 439–448
- [10] Alsharif M, Andrade RS, Groth SS et al. Endobronchial ultrasound-guided transbronchial fine-needle aspiration: the University of Minnesota experience, with emphasis on usefulness, adequacy assessment, and diagnostic difficulties. *Am J Clin Pathol* 2008; 130: 434–443
- [11] Kuo CH, Chen HC, Chung FT et al. Diagnostic Value of EBUS-TBNA for Lung Cancer with Non-Enlarged Lymph Nodes: A Study in a Tuberculosis-Endemic Country. *PLoS One* 2011; 6: doi:10.1371/journal.pone.0016877
- [12] Yarmus LB, Akulian J, Lechtzin N et al. Comparison of 21-gauge and 22-gauge aspiration needle in endobronchial ultrasound-guided transbronchial needle aspiration: results of the American College of Chest Physicians Quality Improvement Registry, Education, and Evaluation Registry. *Chest* 2013; 143: 1036–1043
- [13] Gnass M, Szlubowski A, Soja J et al. Comparison of conventional and ultrasound-guided needle biopsy techniques in the diagnosis of sarcoidosis: a randomized trial. *Pol Arch Med Wewn* 2015; 125: 321–328
- [14] Moonim MT, Breen R, Fields PA et al. Diagnosis and Subtyping of De Novo and Relapsed Mediastinal Lymphomas by Endobronchial Ultrasound Needle Aspiration. *Am J Respir Crit Care Med* 2013; 188: 1216–1223
- [15] Harris RM, Arnaout R, Koziel H et al. Utility of microbiological testing of thoracic lymph nodes sampled by endobronchial ultrasound-guided transbronchial needle aspiration (EBUS-TBNA) in patients with mediastinal lymphadenopathy. *Diagn Microbiol Infect Dis* 2016; 84: 170–174
- [16] Naidich DP, Bankier AA, MacMahon H et al. Recommendations for the management of subsolid pulmonary nodules detected at CT: a statement from the Fleischner Society. *Radiology* 2013; 266: 304–317

- [17] MacMahon H. Compliance with Fleischner Society guidelines for management of lung nodules: lessons and opportunities. *Radiology* 2010; 255: 14–15
- [18] Bhora FY, Chen DJ, Detterbeck FC et al. The ITMIG/IASLC Thymic Epithelial Tumors Staging Project: A Proposed Lymph Node Map for Thymic Epithelial Tumors in the Forthcoming 8th Edition of the TNM Classification of Malignant Tumors. *J Thorac Oncol* 2014; 9: (Suppl. 02): S88–96
- [19] Bechade D, Chomy F. Role of endoscopic ultrasound (EUS) and endobronchial ultrasound (EBUS) for the evaluation of mediastinal adenopathy. *Bull Cancer* 2012; 99: 761–770
- [20] VanderLaan PA, Wang HH, Majid A et al. Endobronchial ultrasound-guided transbronchial needle aspiration (EBUS-TBNA): an overview and update for the cytopathologist. *Cancer Cytopathol* 2014; 122: 561–576
- [21] Kossakowski CA, Morresi-Hauf A, Schnabel PA et al. Preparation of cell blocks for lung cancer diagnosis and prediction: protocol and experience of a high-volume center. *Respiration* 2014; 87: 432–438
- [22] Martinez TomasR, Menendez VillanuevaR, Reyes CalzadaS et al. Pulmonary nocardiosis: risk factors and outcomes. *Respirology* 2007; 12: 394–400
- [23] Yasufuku K, Pierre A, Darling G et al. A prospective controlled trial of endobronchial ultrasound-guided transbronchial needle aspiration compared with mediastinoscopy for mediastinal lymph node staging of lung cancer. *J Thorac Cardiovasc Surg* 2011; 142: 1393–400.e1
- [24] Jhun BW, Park HY, Jeon K et al. Nodal stations and diagnostic performances of endobronchial ultrasound-guided transbronchial needle aspiration in patients with non-small cell lung cancer. *J Korean Med Sci* 2012; 27: 46–51
- [25] Fernandez-Bussy S, Labarca G, Canals S et al. Diagnostic yield of endobronchial ultrasound-guided transbronchial needle aspiration for mediastinal staging in lung cancer. *J Bras Pneumol* 2015; 41: 219–224
- [26] Parmaksiz ET, Caglayan B, Salepci B et al. The utility of endobronchial ultrasound-guided transbronchial needle aspiration in mediastinal or hilar lymph node evaluation in extrathoracic malignancy: Benign or malignant? *Ann Thorac Med* 2012; 7: 210–214
- [27] Karunamurthy A, Cai G, Dacic S et al. Evaluation of endobronchial ultrasound-guided fine-needle aspirations (EBUS-FNA): correlation with adequacy and histologic follow-up. *Cancer Cytopathol* 2014; 122: 23–32
- [28] Dzedzic DA, Peryt A, Orlowski T. The role of EBUS-TBNA and standard bronchoscopic modalities in the diagnosis of sarcoidosis. *Clin Respir J* 2017; 11: 56–63
- [29] Nakajima T, Yasufuku K, Kurosu K et al. The role of EBUS-TBNA for the diagnosis of sarcoidosis—comparisons with other bronchoscopic diagnostic modalities. *Respir Med* 2009; 103: 1796–1800
- [30] Agarwal R, Srinivasan A, Aggarwal AN et al. Efficacy and safety of convex probe EBUS-TBNA in sarcoidosis: a systematic review and meta-analysis. *Respir Med* 2012; 106: 883–892
- [31] von Bartheld MB, Dekkers OM, Szlubowski A et al. Endosonography vs conventional bronchoscopy for the diagnosis of sarcoidosis: the GRANULOMA randomized clinical trial. *JAMA* 2013; 309: 2457–2464
- [32] Caglayan B, Salepci B, Fidan A et al. Sensitivity of convex probe endobronchial sonographically guided transbronchial needle aspiration in the diagnosis of granulomatous mediastinal lymphadenitis. *J Ultrasound Med* 2011; 30: 1683–1689
- [33] Navani N, Molyneaux PL, Breen RA et al. Utility of endobronchial ultrasound-guided transbronchial needle aspiration in patients with tuberculous intrathoracic lymphadenopathy: a multicentre study. *Thorax* 2011; 66: 889–893
- [34] Sun J, Teng J, Yang H et al. Endobronchial ultrasound-guided transbronchial needle aspiration in diagnosing intrathoracic tuberculosis. *Ann Thorac Surg* 2013; 96: 2021–2027
- [35] Wilson JW. Nocardiosis: updates and clinical overview. *Mayo Clin Proc* 2012; 87: 403–407
- [36] Fujikura Y, Kouzaki Y, Ohta S et al. A case of *Nocardia asteroides* infection in a patient with HIV/AIDS diagnosed by endobronchial ultrasound-guided transbronchial needle aspiration (EBUS-TBNA). *Intern Med* 2012; 51: 1413–1417
- [37] Aragaki-Nakahodo A, Benzaquen S, Kirschner M. Coinfection by *Nocardia beijingensis* and *Nocardia arthritis* in an immunocompromised patient diagnosed by endobronchial ultrasound guided transbronchial needle aspiration (EBUS-TBNA). *Respir Med Case Rep* 2014; 12: 22–23
- [38] Dabrowska M, Durlik M, Maskey-Warzechowska M et al. Endobronchial Ultrasound-Guided Transbronchial Needle Aspiration as a New Diagnostic Tool for Invasive Pulmonary Mycoses. *Exp Clin Transplant* 2016: doi:10.6002/ect.2015.0366
- [39] Nakajima T, Yasufuku K, Shibuya K et al. Endobronchial ultrasound-guided transbronchial needle aspiration for the treatment of central airway stenosis caused by a mediastinal cyst. *Eur J Cardiothorac Surg* 2007; 32: 538–540
- [40] Onuki T, Kuramochi M, Inagaki M. Mediastinitis of bronchogenic cyst caused by endobronchial ultrasound-guided transbronchial needle aspiration. *Respir Case Rep* 2014; 2: 73–75
- [41] Hong G, Song J, Lee KJ et al. Bronchogenic cyst rupture and pneumonia after endobronchial ultrasound-guided transbronchial needle aspiration: a case report. *Tuberc Respir Dis (Seoul)* 2013; 74: 177–180
- [42] Gilbert S, Wilson DO, Christie NA et al. Endobronchial ultrasound as a diagnostic tool in patients with mediastinal lymphadenopathy. *Ann Thorac Surg* 2009; 88: 896–900; discussion 901–2
- [43] Lange TJ, Kunzendorf F, Pfeifer M et al. Endobronchial ultrasound-guided transbronchial needle aspiration in routine care – plenty of benign results and follow-up tests. *Int J Clin Pract* 2012; 66: 438–445
- [44] Haponik EF, Shure D. Underutilization of transbronchial needle aspiration: experiences of current pulmonary fellows. *Chest* 1997; 112: 251–253
- [45] Mallya V, Kumar SP, Meganathan P et al. The utility of ROSE (rapid on-site evaluation) in endobronchial ultrasound (EBUS)-guided transbronchial needle aspiration (TBNA): Is the picture rosy? *J Cytol* 2015; 32: 230–233
- [46] Wahidi MM, Herth F, Yasufuku K et al. Technical Aspects of Endobronchial Ultrasound-Guided Transbronchial Needle Aspiration: CHEST Guideline and Expert Panel Report. *Chest* 2016; 149: 816–835
- [47] Kang HJ, Hwangbo B. Technical aspects of endobronchial ultrasound-guided transbronchial needle aspiration. *Tuberc Respir Dis (Seoul)* 2013; 75: 135–139
- [48] Herth FJ, Morgan RK, Eberhardt R et al. Endobronchial ultrasound-guided miniforceps biopsy in the biopsy of subcarinal masses in patients with low likelihood of non-small cell lung cancer. *Ann Thorac Surg* 2008; 85: 1874–1878
- [49] Shiu KK, Eberhardt R, Herth FJ. Comparison of 22-gauge and 19-gauge needles in endobronchial ultrasound (ebus) transbronchial needle aspiration (tbna) in mediastinum lymph node assessment. *Chest* 2007; 132: 465b–465