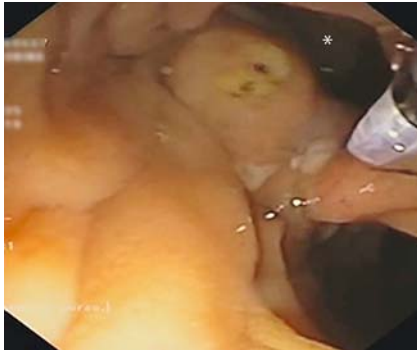
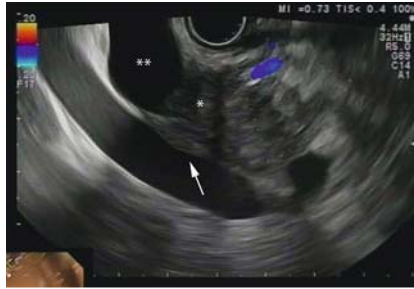
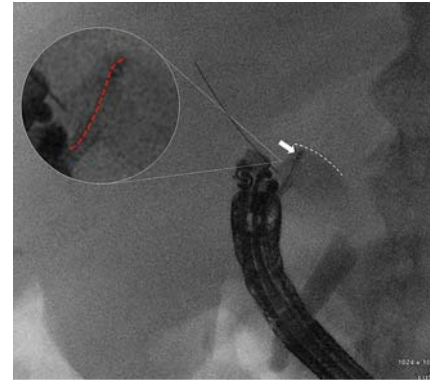
Salvage procedure following lumen-apposing metal stent maldeployment during endoscopic ultrasound-guided biliary drainage



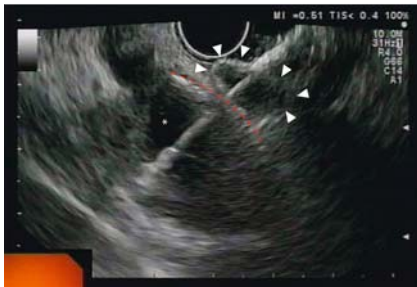► **Fig. 1** Endoscopic view of the major papilla located on the inferior margin of the diverticulum (*). The common bile duct could not be cannulated with the guide-wire because of marked tortuosity of the distal part.



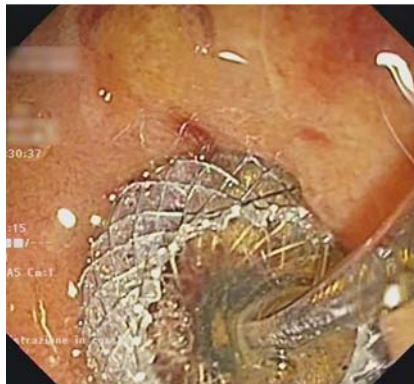
► **Fig. 2** Endoscopic ultrasound view of a 40-mm solid inhomogeneous hypoechoic lesion with irregular borders (*) in the head of the pancreas, infiltrating the portal vein (arrow) and the intrapancreatic common bile duct, and dilated up to 18 mm at the upper/middle third (**).



► **Fig. 3** Fluoroscopic view of the mal-deployed distal flange of the stent inside the common bile duct (CBD). The tip of the releasing catheter (arrow) of the stent is closely facing the distal wall of the CBD (dashed white line), resulting in a slight kinking of the catheter axis (dashed red line). A 0.035-inch guidewire was inserted through the stent catheter to secure the access to the CBD.



► **Fig. 4** Endoscopic ultrasound view of the distal flange of the stent (arrowheads) fully released outside of the common bile duct (CBD; *). The wall of the CBD is highlighted by the red dashed line.



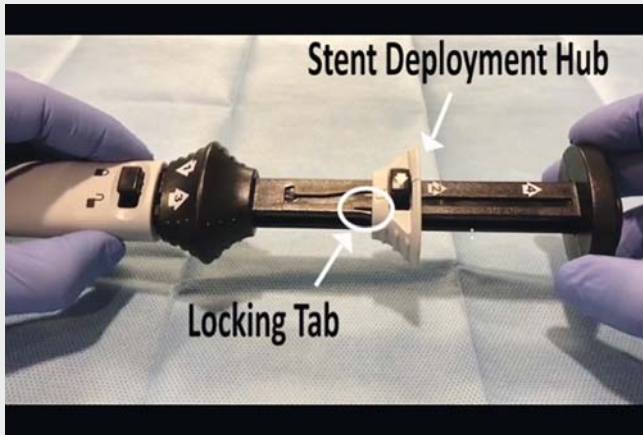
► **Fig. 5** Endoscopic view of choledocho-duodenostomy showing proximal flange of the stent released and correctly in place in the duodenal bulb.

A jaundiced 82-year-old-woman was diagnosed with a cephalopancreatic, locally advanced adenocarcinoma. Endoscopic retrograde cholangiopancreatography was planned, but biliary cannulation was not achieved because of a large periampullary diverticulum (► **Fig. 1**). We therefore decided to perform endoscopic ultrasound (EUS)-guided biliary drainage using an 8-mm electrocautery-tipped lumen-apposing metal stent (LAMS; AXIOS-EC, Boston Scientific, Marlborough, Massachusetts, USA). The dilated common bile duct (CBD) (► **Fig. 2**) was accessed from the bulb

under EUS guidance with the electrocautery-tipped delivery system in a “free-hand” fashion [1]. The distal flange did not fully expand because the tip of the catheter was too close to the facing wall of the CBD in an oblique direction, leaving insufficient room for the stent to fully open (► **Fig. 3**). To secure the access to the CBD, a guidewire was inserted through the catheter into the biliary tree (► **Fig. 3**). To allow the distal flange to fully open, the catheter was slightly withdrawn; however, the stent slid out of the

CBD, with the fully released flange, into the abdominal cavity (► **Fig. 4**). The catheter was then retrieved, and the open flange was re-sheathed by repositioning the stent deployment hub to the original position (► **Video 1**). The delivery system was reinserted over the wire, under endoscopic view, into the CBD without any further device energizing. The distal flange was then deployed under EUS view, and the proximal flange under endoscopic view (► **Fig. 5**). Cholangiography confirmed that the stent was in place. The post-procedural course was uneventful.

Stent maldeployment during EUS-guided biliary drainage is a severe adverse event. In cases where the CBD is not well dilated, with the potential for subsequent difficulty in stent deployment, the preventive placement of a through-the-stent guidewire is advisable. The described salvage procedure avoids the need for a second access to the CBD, maintaining the same route with a guidewire, and reintroducing the re-sheathed stent. This avoids the



Video 1 Salvage procedure following maldeployment of a lumen-apposing metal stent during endoscopic ultrasound-guided biliary drainage.

need for any emergency surgery, and also allows reuse of the same stent, thus saving on cost.

Endoscopy_UCTN_Code_TTT_1AS_2AD

Competing interests

None

The authors

Dario Ligresti, Michele Amata, Antonino Granata, Fabio Cipolletta, Luca Barresi, Mario Traina, Ilaria Tarantino

Endoscopy Service, Department of Diagnostic and Therapeutic Services, IRCCS-ISMETT (Istituto Mediterraneo per i Trapianti e Terapie ad alta specializzazione), Palermo, Italy

Corresponding author

Dario Ligresti, MD

Endoscopy Service, Department of Diagnostic and Therapeutic Services, IRCCS ISMETT – UPMC, Via E. Tricomi 5, 90127 Palermo, Italy
Fax: +39-091-2192400
dligresti@ismett.edu

Reference

- [1] Krishnan K, Raza A. EUS-guided choledochoduodenostomy with use of a lumen-apposing metal stent: the freehand technique. *VideoGIE* 2018; 3: 2

Bibliography

DOI <https://doi.org/10.1055/a-0605-3198>
Published online: 12.6.2018
Endoscopy 2018; 50: E190–E191
© Georg Thieme Verlag KG
Stuttgart · New York
ISSN 0013-726X

ENDOSCOPY E-VIDEOS

<https://eref.thieme.de/e-videos>



Endoscopy E-Videos is a free access online section, reporting on interesting cases and new techniques in gastroenterological endoscopy. All papers include a high quality video and all contributions are freely accessible online.

This section has its own submission website at <https://mc.manuscriptcentral.com/e-videos>