

Validation of treatment algorithm based on the Japan narrow-band imaging expert team classification for sub-centimeter colorectal polyps



Authors

Motohiko Kato¹, Keiichiro Abe¹, Yoko Kubosawa¹, Yukie Sunata¹, Yuichiro Hirai¹, Tetsu Hirata¹, Yoshiaki Takada¹, Michiko Wada¹, Yusaku Takatori¹, Shigeo Banno¹, Satoshi Kinoshita¹, Hideki Mori¹, Kaoru Takabayashi¹, Masahiro Kikuchi¹, Junichi Shiraishi², Toshio Uraoka¹

Institutions

- 1 Department of Gastroenterology, National Hospital Organization Tokyo Medical Center, Tokyo, Japan
- 2 Department of Pathology, National Hospital Organization Tokyo Medical Center, Tokyo, Japan

submitted 18.12.2017

accepted after revision 9.4.2018

Bibliography

DOI <https://doi.org/10.1055/a-0621-4445> |
Endoscopy International Open 2018; 06: E934–E940
© Georg Thieme Verlag KG Stuttgart · New York
ISSN 2364-3722

Corresponding author

Motohiko Kato, MD, PhD, Department of Gastroenterology, National Hospital Organization Tokyo Medical Center, 2-5-1 Higashigaoka, Meguro-ku, Tokyo, 152-8902, Japan
Fax: +81-3-3412-9811
moto28hiko@icloud.com

ABSTRACT

Background and study aims Although cold polypectomy (CP) is widely used for colorectal polyps <10 mm, appropriateness of indications for CP or endoscopic mucosal resection (EMR) are still unclear. The aim of this study was to va-

litate the endoscopic treatment algorithm based on the Japan NBI Expert Team (JNET) classification.

Patients and methods Consecutive patients with at least one colorectal non-pedunculated polyp <10 mm between July 2014 and October 2016 were included in this retrospective study. During the period, EMR was performed for JNET ≥2B lesions and CP for JNET <2A. Among a total of 3966 lesions, 3368 lesions with JNET ≤2A were resected by CP in compliance with the treatment algorithm but 565 resections for JNET ≤2A were not compliant (by EMR), while all 24 JNET >2B lesions were removed by EMR in compliance with the algorithm. Polypectomy outcomes were compared between the compliant and non-compliant groups. Histological outcomes were analyzed in accordance with JNET classification.

Results Post-polypectomy bleeding rate in the compliant group (0%) was lower than that in the non-compliant group (0.53%, $P < 0.01$). Proportion of lesions diagnosed as cancer (38% vs 0.36%, $P < 0.01$) or submucosal cancer (4.2% vs 0.03%, $P = 0.012$), and the lesion with free resection margin (91% vs 64%, $P < 0.01$) was higher in the JNET ≥2B than JNET ≤2A.

Conclusion This study indicated our algorithm would be valid: CP is suitable for most polyps <10 mm as incidence of post-polypectomy bleeding is low, whereas EMR is recommended for JNET ≥2B lesions for histological complete removal.

Introduction

Colorectal cancer is the third most common cancer in the world, contributing to 9.7% (1.4 million) of the total number of new cases diagnosed in 2012 [1]. Colorectal polyps are considered to be precursors to colorectal cancer because cancer arises from adenomas by accumulation of mutations of cancer suppressor genes in a process known as the adenoma-carcinoma sequence [2].

Both polypectomy using an electrocautery snare (hot snare polypectomy: HSP) and endoscopic mucosal resection (EMR) combined with submucosal injection [3,4] were first reported in 1973. These endoscopic polypectomy methods have been widely used, and it has been reported that endoscopic polypectomy significantly reduces incidence and mortality of colorectal cancer [5,6]. However, as the opportunity for endoscopic treatment has increased, complications have also increased, including delayed bleeding, perforation and post-polypectomy coag-

ulation syndrome, [7] which are caused by excessive energization.

Cold polypectomy (CP) is a type of polypectomy in which polyps are physically cut without electric current. This technique was reported by Woods in 1989 as a method of eradicating diminutive polyps using biopsy forceps, [8] and Draganov reported that higher rates of complete resection were achieved using jumbo biopsy forceps [9]. This CP procedure using forceps is called cold forceps polypectomy (CFP). Moreover, Tapero first reported CP using a snare (called cold snare polypectomy: CSP) in 1992 [10].

Given its safety and convenience, use of CP has spread and it has been accepted as a treatment method for all subcentimeter lesions [9, 11–14]. However, conventional HSP and EMR still have a role because they have a potential advantage in eradicating neoplastic lesions using electrocautery. Therefore, if patients are appropriately chosen for CP and EMR appropriately, outcomes of polypectomy could be improved. Magnified endoscopy with narrow band imaging (NBI-ME) has been reported to be useful for differentiating between adenoma and non-neoplastic lesions by estimating the depth of invasion of cancer [15–19]. In 2014, a universal consensus was made on NBI-ME diagnosis, and the Japan NBI Expert Team (JNET) classification was established in which the findings of NBI-ME are categorized into four subgroups and JNET 2B and 3 are findings indicative of cancer [20]. We have established a treatment algorithm in which CP is applied to lesions with JNET 1 or 2A, and EMR/ HSP is used for lesions with JNET 2B. Therefore, the aim of this study was to validate the appropriateness of our algorithm and to clarify the appropriate treatment strategy for polyps less than 10 mm.

Patients and methods

Study design

This was a retrospective study in a tertiary hospital. Consecutive patients who underwent a colonoscopy in whom at least one colorectal polyp was detected in our department from July 2014 to October 2016 were included in this study. A total of 4668 lesions were endoscopically resected in our department during the study period. Of these, 607 lesions were excluded because their size exceeded 10 mm and 95 lesions were excluded because of pedunculated morphology. As a result, 3966 lesions were included in the data analysis. The analysis was performed on a per-lesion basis, since the outcomes of polypectomy is strongly associated with the properties of a lesion rather than those of a patient. Written informed consent was obtained from each patient included in the study. The study protocol conformed to the ethical guidelines of the 1975 Declaration of Helsinki as reflected in a prior approval by the institution's human research committee and approved by Tokyo medical center institutional review board on September 27th 2016.

Colonoscopy procedure

All endoscopists participated in an intensive, 1-hour, interactive training program on endoscopic diagnosis of colorectal polyp including diagnosis of NBI with magnification by an expert

endoscopist (T.U.) before performing CP. Patients underwent bowel preparation consisting of sodium picosulfate the day before colonoscopy and 2 to 3 L of polyethylene glycol solution the morning before the procedure. Colonoscopies were exclusively performed using a colonoscope with magnification capability and water irrigation function (PCF-Q260AZI or PCF-H290AZI, Olympus Co., Tokyo, Japan). After cecal intubation, all detected polyps were photographed, and their characteristics, including size, location, macroscopic type and findings of magnified endoscopy with NBI-ME, were documented. Lesion size was estimated according to comparison to endoscopic devices. Cessation of antithrombotic drugs was done in accordance with guidelines for gastroenterological endoscopy in patients undergoing antithrombotic treatment published by the Japan Gastroenterological Endoscopy Society in 2014 [21]. Procedures were performed by three experts who had performed more than 5000 colonoscopies, four gastroenterologists who had performed 1000 to 4999 colonoscopies and six trainees who had performed fewer than 1000 colonoscopies.

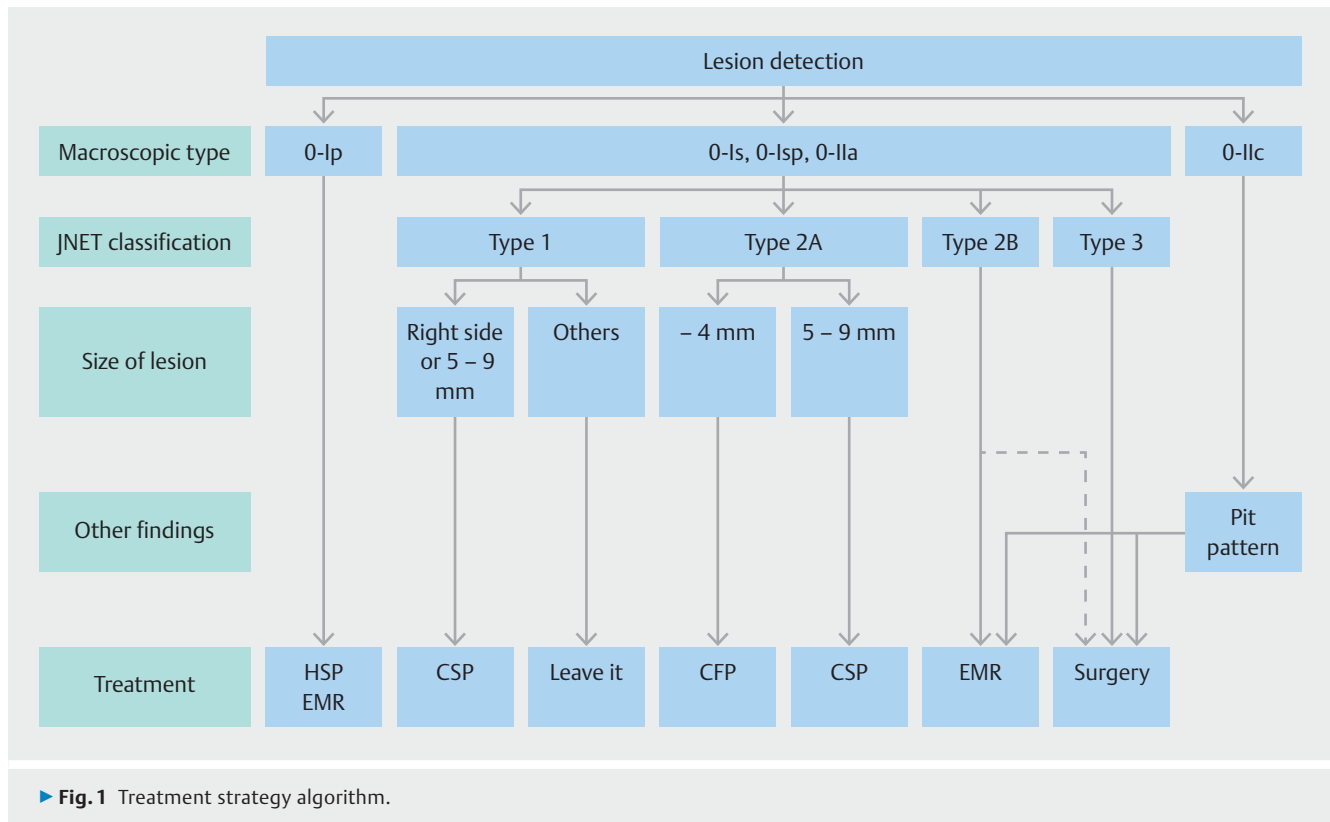
Endoscopic diagnosis

According to macroscopic findings, lesions were classified as pedunculated (0-Ip), sessile (0-Is, Isp), flat (0-IIa) or depressed (0-IIc, 0-IIa+IIc, 0-Is+IIc) according to the Paris classification [22]. Differentiation among non-neoplastic lesions, adenoma or cancer by macroscopic findings was made based on lesion shape and color. Hyperplastic polyps usually presented as whitish, flat, elevated lesions; adenoma exhibited a reddish color and irregular shape, and obvious depression and remarkable redness were findings suggestive of cancer. Following conventional white light imaging (WLI), we applied NBI-ME. The NBI-ME diagnosis was made according to the JNET classification, which is a universal diagnostic classification consisting of both microstructural and micro-vessel findings that was proposed in June 2014 [20].

Treatment strategy based on endoscopic diagnosis

If any lesion was found during colonoscopy, each endoscopist immediately decided whether to remove it based on real-time diagnosis including NBI-ME. All lesions suspected as neoplasms were resected. Each endoscopist chose the type of procedure for polypectomy according to macroscopic features or endoscopic diagnosis. The algorithm for the treatment strategy is shown in ► Fig. 1.

Pedunculated polyps (Paris type 0-Ip) were resected by HSP or EMR, and CP was not attempted due to the possibility of immediate or post-procedure bleeding. The treatment choice for other polypoid lesions (Paris type 0-Is or 0-Isp) and flat, elevated polyps (Paris type 0-IIa) was determined according to NBI-ME findings. For JNET Type I polyps, those larger than 5 mm located on the right side of the colon were resected by CP because those findings suggested sessile serrated adenomas/polyps. JNET Type 2A polyps were considered low-grade adenomas and they were treated with CP. We chose CSP or CFP according to polyp size; CSP was applied to small (6–9 mm) polyps, and CFP was applied to diminutive (1–5 mm) polyps. As JNET Type 2B polyps were likely to be high-grade adenoma



or intramucosal cancer, they were treated with EMR unless there was an obvious finding of massive submucosal invasion. JNET Type 3 polyps were surgically resected because they are likely to be invasive cancers. Depressed lesions were resected by EMR as long as invasive signs were not present on pit pattern diagnosis using crystal violet staining.

Cold polypectomy procedure

In CSP, a polyp with a rim of surrounding normal mucosa was ensnared with a snare (Captivator II 10 mm, Boston Scientific, Marlborough, Massachusetts, United States) and then removed by forced transection without use of electrocautery. In CFP, the polyp was removed with jumbo biopsy forceps (Radial Jaw 4 Jumbo Biopsy Forceps; Boston Scientific). After polypectomy, we created submucosal tamponade with forced water irrigation and confirmed that no residual tumor was present in post-polypectomy defects using NBI with magnification. Hemoclips were placed only in cases of continuous arterial bleeding immediately after CP.

Outcome measurements

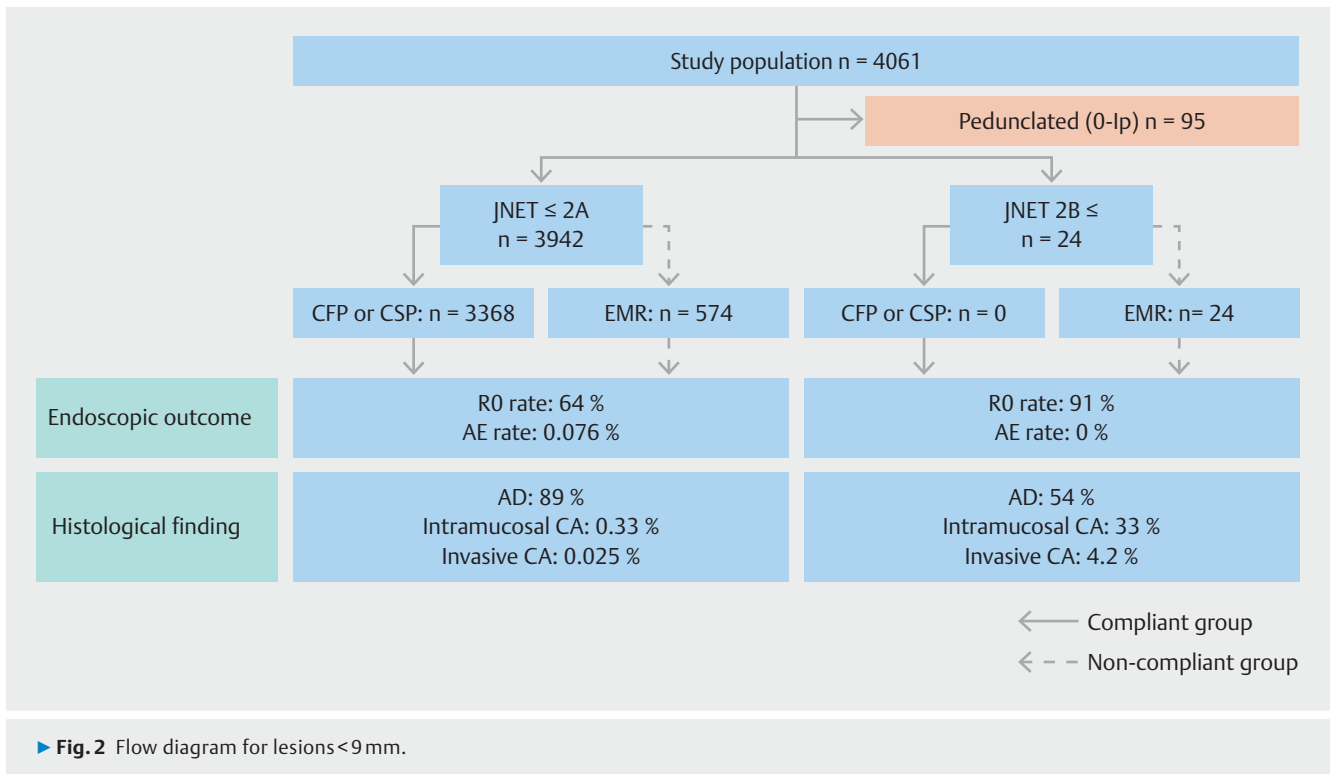
To validate our algorithm of treatment strategy for colorectal polyps, we divided all lesions into two groups, compliant and non-compliant, according to whether they were resected in compliance with the algorithm from the viewpoint of the choice of either HSP/EMR or CP. A lesion was categorized as compliant if it was Paris type 0-Ip or with JNET 2B/3 and resected by HSP/EMR or if it was another type of lesion and was resected with CP. In this study, we didn't distinguish compliance

based on the choice of either CFP or CSP. We compared clinical characteristics, outcomes of polypectomy and pathological findings between the compliant and non-compliant group. In addition, we compared pathological findings between the JNET 1, 2A (JNET \leq 2A) group and JNET 2B, 3 (JNET \geq 2B) group.

Location, macroscopic type, size, endoscopic diagnosis of WLI and NBI-ME diagnosis were noted as clinical characteristics. Macroscopic type was classified as polypoid (0-Is, 0-Isp or 0-Ip of the Paris classification) or flat (0-IIa or 0-IIc of the Paris classification) [22]. A single endoscopist (K. A.) who was blinded to the pathological diagnosis reviewed the macroscopic type, WLI diagnosis and NBI-ME diagnosis using the recorded images. Location and size of lesions were referenced in the endoscopic record.

For polypectomy outcomes, we collected data concerning the proportion resected in a single piece, perforation and post-procedure bleeding. Bleeding was defined as an episode of obvious hematochezia with active bleeding or adherent clots on the post-polypectomy site confirmed by colonoscopy.

Pathological diagnosis was made based on the Vienna classification [23]. We assessed the cancer-bearing rate, proportion of submucosal cancer and proportion of negative margins as pathological findings. The cancer-bearing rate was defined as the proportion of lesions pathologically diagnosed as cancer to all resected lesions. A negative resected margin was limited to only lesions that were resected in a single piece with a tumor-free margin, and the outcome was treated as a non-negative margin when the lesion was lost or fragmented during retrieval.



The protocol compliance rate was defined as the proportion of polyps subjected to a polypectomy method prescribed by the protocol relative to all polyps. Moreover, the protocol compliance rate was analyzed by dividing the polypectomy method into HSP/EMR and CP groups.

Statistical analysis

Wilcoxon's rank sum test and Fisher's exact test were used to compare continuous and categorized factors. Outcomes of polypectomy are presented as percentages with 95% confidence intervals. Statistical significance was defined as $P < 0.05$. Data analysis was performed using JMP software (ver. 11.1.1, SAS Institute Inc., Cary, North Carolina, United States).

Results

Clinical characteristics

A flow diagram of included lesions is shown in ► **Fig. 2**. The compliant group included 3401 lesions and the non-compliant group included 565 lesions. The proportion of lesions resected in compliance with the algorithm was 85.8%. The most common reason for violation was application of EMR/HSP for lesions with JNET ≤ 2A (99.7%). The clinical characteristics of the examined lesions are described in ► **Table 1**. Approximately 60% of lesions were located in the right colon. Over 90% of the lesions had polypoid morphology. Mean polyp size was 4.6 ± 1.7 mm. Approximately 99% of lesions were classified as JNET 2A. When the study population was divided into the compliant and non-compliant groups, significantly more lesions were located on the right side and lesion size was significantly smaller in the compliant group. The main reason for violating the algorithm

► **Table 1** Clinical characteristic of the lesions (n = 3966).

Location	Cecum	7%
	Ascending colon	24%
	Transverse colon	26%
	Descending colon	9%
	Sigmoid colon	24%
	Rectum	10%
Macroscopic type	Sessile	93%
	Flat	6%
	Depressed	1%
Size	Mean ± SD	4.6 ± 1.7 mm
Japan NBI Expert classification	1	1.7%
	2A	97.7%
	2B	0.6%
	3	0.03%

was application of EMR/HSP for JNET ≤ 2A and the majority of the non-compliant group was resected with EMR/HSP (► **Table 2**).

Outcomes of polypectomy in compliant and non-compliant group

Outcomes of endoscopic treatment in both the compliant and non-compliant groups are described in ► **Table 3**. Resection in a single piece was achieved in more than 97% of lesions in both groups. Perforation did not occur in either group. Delayed bleeding occurred only in the non-compliant group, and there was a significant difference in the proportion of lesions with delayed bleeding.

► **Table 2** Characteristics of lesions in compliant and non-compliant groups.

Factors		Compliant (N = 3401)	Non-compliant (N = 565)	P value
Location	Right side	60 %	47 %	<0.01 *
Macroscopic type	Polypoid	93 %	93 %	0.98
Size	Median [range]	4 [2–9] mm	7 [2–9] mm	<0.01 *
WLI diagnosis	Adenoma	98 %	95 %	<0.01 *
JNET classification	≤2A ≥2B	99.3 % 0.68 %	99.8 % 0.18 %	0.24
Endoscopic treatment	CP EMR/HSP	99.0 % 1.0 %	0.35 % 99.6 %	<0.01 *

WLI, white light imaging; JNET, Japan NBI Expert Team

* statistically significant

► **Table 3** Outcomes of endoscopic treatment in compliant and non-compliant groups.

Factors	Compliant (N = 3401)	Non-compliant (N = 565)	P value
Resection in a single piece [95 % CI]	98.2 % [97.7–98.6 %]	97.0 % [95.2–98.1 %]	0.068
Perforation [95 % CI]	0 % [0–0.11 %]	0 % [0–0.68 %]	
Bleeding [95 % CI]	0 % [0–0.11 %]	0.53 % [0.18–1.5 %]	<0.01 *

* statistically significant

► **Table 4** Pathological findings of lesions ≤JNET 2A and ≥JNET 2B.

Factors	≤JNET 2A	≥JNET 2B	P value
Cancer-bearing rate [95 % CI]	0.36 % [0.21–0.60 %]	38 % [21–57 %]	<0.01 *
Proportion of Submucosal cancer [95 % CI]	0.03 % [0.00–0.14 %]	4.2 % [0.7–20 %]	0.012 *
Negative margin [95 % CI]	64 % [62–65 %]	91 % [72–97 %]	<0.01 *

* statistically significant

Comparison of pathological findings between JNET ≤2A and ≥2B group

Pathological findings of the resected specimens according to NBI-ME findings are shown in ► **Table 4**. There were many more lesions diagnosed as cancer pathologically in the JNET ≥2B group (38 %) than in the JNET ≤2A group (0.36 %). Similarly, the proportion of submucosal cancer was much higher in the JNET ≥2B group (4.2 % vs 0.03 %). With regard to the incidence of negative resection margins, it was significantly higher in the compliant group (91 % vs 64 %).

Comparison of outcomes between CP and EMR/HSP

Resection in a single piece was achieved in approximately 98 % of lesions in both groups. Perforation did not occur in either group. Delayed bleeding occurred in three lesions (0.50 %, 95 % CI 0.17–1.5 %) resected by EMR/HSP, whereas no lesion treated with CP was associated with delayed bleeding. The cancer-bearing rate was approximately 10-fold higher for EMR/HSP than for CP (2.5 % vs 0.24 %, $P < 0.01$). Submucosal cancer was found only in the EMR group. The incidence of negative resection margins was significantly higher in the EMR group (86 % vs 60 %, $P < 0.01$).

Discussion

In this retrospective study, we analyzed 4061 endoscopically resected consecutive polyps. Post-polypectomy bleeding did not occur at all in 3401 polyps resected with CP, and the proportion of post-polypectomy bleeding of CP was significantly lower than that for HSP/EMR. However, the negative margin rate for CP was 60%, which was significantly lower than that for HSP/EMR. According to our treatment strategy algorithm, the cancer-bearing rate for HSP/EMR was 10-fold higher than that for CP.

Previous studies have reported that CP prevented post-polypectomy bleeding [8–10]. Recently, Horiuchi reported that CSP did not cause post-polypectomy bleeding in patients receiving anticoagulant treatment, and a significant difference was observed between CSP and EMR [13]. These results suggest that CP would reduce post-polypectomy bleeding as well as perforation or post-polypectomy electrocoagulation syndrome, although electrocoagulation is believed to prevent bleeding immediately after polypectomy. The results of our study showed that post-polypectomy bleeding was not found in more than 3000 consecutive polyps resected by CP, which provides evidence of the safety of CP.

Despite its safety, some concerns exist regarding CP. One concern is the inferiority of the curability of polyps removed using CP. The negative margin rate for CP was only 60%, which was significantly lower than that for HSP/EMR (approximately 85% in our study). Not using an electric current leads to fewer complications but increases the risk of local residue due to absence of a burning effect. Furthermore, maintaining sufficient margins is difficult in CP because a polyp cannot be physically removed, as opposed to EMR, if excess surrounding mucosa is captured. Another concern is the difficulty of pathological diagnosis of specimens resected by CP. Tutticci reported that resection depth with CSP was relatively shallow, with a shallow layer of submucosa and occasionally muscularis mucosa [24]. Specimens were thin and fragile and were therefore easily fragmented during retrieval by suctioning through the working channel of the colonoscope. It is also difficult to diagnose invasive cancer when a sufficient depth of the submucosal layer is not resected. Therefore, EMR/HSP is much better than CP in terms of clearness of margin resection and precise histological diagnosis.

According to previous reports, the proportion of invasive cancer in polyps smaller than 10 mm ranges from 0.2 to 0.9% [25,26]. The proportion of invasive cancer in our study was 0.27%, which was consistent with previous studies. These proportions were low; however, they were not negligible when considering the disadvantage of CP mentioned above. Using macroscopic findings and the JNET classification, we established an algorithm for choosing the type of endoscopic treatment for small colorectal polyps. In this retrospective study, we analyzed 3966 endoscopically resected consecutive polyps to validate our algorithm for treatment strategy for small colorectal polyps. Post-polypectomy bleeding did not occur at all in 3401 polyps resected in compliance with our algorithm, and the proportion of post-polypectomy bleeding with CP was sig-

nificantly lower than that in the non-compliant group. Moreover, both the cancer-bearing rate and proportion of submucosal cancer, and proportion of the lesion with pathological tumor-free margin were much higher in the JNET $\geq 2B$ group. These results show our algorithm effectively picked up high-risk lesions and EMR/HSP (which is better in terms of clearness margin resection) or CP (which is better in terms of less complications) was appropriately chosen with significant decrease in complications.

The current study has several limitations due its single-center retrospective design. First, we analyzed only lesions that were endoscopically resected; therefore, we cannot eliminate a certain degree of selection bias. For example, small lesions surgically resected due to a suspicion of deep invasion were excluded from data analysis. Second, the compliance rate for treatment choices in this study was less than 50%. However, concerning the choice between CP and EMR, the compliance rate was approximately 85%. Although the results of our study should be interpreted carefully due to these limitations, our results, based on over 4000 polyps, indicate that CP should be considered as a treatment option.

Conclusion

In conclusion, this large-scale retrospective study demonstrated that our algorithm for treatment of small polyps based on endoscopic diagnosis, including NBI-ME, would be valid. Although CP is suitable for a large proportion of small polyps due to its safety, EMR should still be used for an accurate pathological diagnosis when polyps are suspected as cancer by NBI-ME.

Competing interests

None

References

- [1] WHO. World Cancer Research Fund International. 2012
- [2] Cho KR, Vogelstein B. Suppressor gene alterations in the colorectal adenoma-carcinoma sequence. *Journal of cellular biochemistry Supplement* 1992; 16G: 137–141
- [3] Deyhle P. A method for endoscopic electroresection of sessile colonoc polyps. *Endoscopy* 1973; 5: 38–40
- [4] Wolff WJ, Shinya H. Polypectomy via the fiberoptic colonoscope. Removal of neoplasms beyond reach of the sigmoidoscope. *N Engl J Med* 1973; 288: 329–332
- [5] Zauber AG, Winawer SJ, O'Brien MJ et al. Colonoscopic polypectomy and long-term prevention of colorectal-cancer deaths. *N Engl J Med* 2012; 366: 687–696
- [6] Atkin WS, Edwards R, Kralj-Hans I et al. Once-only flexible sigmoidoscopy screening in prevention of colorectal cancer: a multicentre randomised controlled trial. *Lancet (London, England)* 2010; 375: 1624–1633
- [7] Fisher DA, Maple JT, Committee ASOP. et al. Complications of colonoscopy. *Gastrointest Endosc* 2011; 74: 745–752

- [8] Woods A, Sanowski RA, Wadas DD et al. Eradication of diminutive polyps: a prospective evaluation of bipolar coagulation versus conventional biopsy removal. *Gastrointest Endosc* 1989; 35: 536–540
- [9] Draganov PV, Chang MN, Alkhasawneh A et al. Randomized, controlled trial of standard, large-capacity versus jumbo biopsy forceps for polypectomy of small, sessile, colorectal polyps. *Gastrointestinal Endoscopy* 2012; 75: 118–126
- [10] Tappero G, Gaia E, De Giuli P et al. Cold snare excision of small colorectal polyps. *Gastrointest Endosc* 1992; 38: 310–313
- [11] Raad D, Tripathi P, Cooper G et al. Role of the cold biopsy technique in diminutive and small colonic polyp removal: a systematic review and meta-analysis. *Gastrointest Endosc* 2016; 83: 508–515
- [12] Uraoka T, Ramberan H, Matsuda T et al. Cold polypectomy techniques for diminutive polyps in the colorectum. *Dig Endosc* 2014; 26: (Suppl. 02): 98–103
- [13] Horiuchi A, Nakayama Y, Kajiyama M et al. Removal of small colorectal polyps in anticoagulated patients: a prospective randomized comparison of cold snare and conventional polypectomy. *Gastrointest Endosc* 2014; 79: 417–423
- [14] Repici A, Hassan C, Vitetta E et al. Safety of cold polypectomy for < 10 mm polyps at colonoscopy: a prospective multicenter study. *Endoscopy* 2011; 44: 27–31
- [15] Kanao H, Tanaka S, Oka S et al. Narrow-band imaging magnification predicts the histology and invasion depth of colorectal tumors. *Gastrointest Endosc* 2009; 69: 631–636
- [16] Sano Y, Ikematsu H, Fu KI et al. Meshed capillary vessels by use of narrow-band imaging for differential diagnosis of small colorectal polyps. *Gastrointest Endosc* 2009; 69: 278–283
- [17] Wada Y, Kudo SE, Kashida H et al. Diagnosis of colorectal lesions with the magnifying narrow-band imaging system. *Gastrointest Endosc* 2009; 70: 522–531
- [18] Higashi R, Uraoka T, Kato J et al. Diagnostic accuracy of narrow-band imaging and pit pattern analysis significantly improved for less-experienced endoscopists after an expanded training program. *Gastrointest Endosc* 2010; 72: 127–135
- [19] Ikematsu H, Matsuda T, Emura F et al. Efficacy of capillary pattern type IIIA/IIIB by magnifying narrow band imaging for estimating depth of invasion of early colorectal neoplasms. *BMC gastroenterology* 2010; 10: 33
- [20] Sano Y, Tanaka S, Kudo SE et al. Narrow-band imaging (NBI) magnifying endoscopic classification of colorectal tumors proposed by the Japan NBI Expert Team. *Dig Endosc* 2016; 28: 526–533
- [21] Fujimoto K, Fujishiro M, Kato M et al. Guidelines for gastroenterological endoscopy in patients undergoing antithrombotic treatment. *Dig Endosc* 2014; 26: 1–14
- [22] [Anonymous] Update on the paris classification of superficial neoplastic lesions in the digestive tract. *Endoscopy* 2005; 37: 570–578
- [23] Stolte M. The new Vienna classification of epithelial neoplasia of the gastrointestinal tract: advantages and disadvantages. *Virchows Arch* 2003; 442: 99–106
- [24] Tutticci N, Burgess NG, Pellise M et al. Characterization and significance of protrusions in the mucosal defect after cold snare polypectomy. *Gastrointest Endosc* 2015; 82: 523–528
- [25] Gschwantler M, Kriwanek S, Langner E et al. High-grade dysplasia and invasive carcinoma in colorectal adenomas: a multivariate analysis of the impact of adenoma and patient characteristics. *Eur J Gastroenterol Hepatol* 2002; 14: 183–188
- [26] Lieberman D, Moravec M, Holub J et al. Polyp size and advanced histology in patients undergoing colonoscopy screening: implications for CT colonography. *Gastroenterology* 2008; 135: 1100–1105